

A Metastatic Parachordoma Case

Bir Metastatik Parakordoma Olgusu

Sener Cihan¹, Birsen Songul Cihan², Ajlan Atasoy³, Tugba Fahriye Kos⁴, Nalan Akgul Babacan⁵

¹ Okmeydani Education and Research Hospital Department of Medical Oncology, Istanbul, Turkey

² Okmeydani Education and Research Hospital Department of Radiology, Istanbul, Turkey

³ Diyarbakir Education and Research Hospital Department of Medical Oncology, Diyarbakir, Turkey

⁴ Sutcu Imam University Faculty of Medicine Department of Medical Oncology, Kahramanmaraş, Turkey

⁵ Cumhuriyet University Faculty of Medicine Department of Medical Oncology, Sivas, Turkey

ABSTRACT

Parachordoma is a soft tissue tumor with a high risk of local recurrence. Despite the fact that parachordomas mostly have an indolent course, distant metastasis can be seen on rare occasion. We hereby report a case of a 28-year-old male who was initially diagnosed with parachordoma five years ago when he presented with a mass on his right shoulder. He suffered from local recurrence twice within the first two years after his surgery. Metastatic disease later presented itself with a mass in his left retro-orbital fossa. The patient underwent a partial surgical resection and the pathologic evaluation was reported as "myoepithelial tumor metastasis". The patient's systemic work up showed bilateral pulmonary metastatic nodules and metastasis in the right sacroiliac joint. After radiotherapy for the sacroiliac and left orbital mass, chemotherapy was initiated. The regimen consisted of ifosfamide, mesna and doxorubicin. Follow-up evaluation revealed a minimal decrease in size in the pulmonary nodules and the retro-orbital mass. There was no 18-FDG uptake in the sacroiliac mass on PET-BT. In conclusion, surveillance carries importance due to the risk of metastasis for patients with parachordoma. Systemic chemotherapy consisting of doxorubicin and ifosfamide could be used successfully.

Key Words: Parachordoma, metastasis, radiotherapy, chemotherapy

Received: 11.28.2013

Accepted: 03.19.2014

ÖZET

Parakordoma, lokal rekürrens sıklığı fazla olan bir yumuşak doku tümörüdür. İndolen seyir izlemelerine rağmen nadir de olsa metastatik özellik gösterebilirler. Bu makalede beş yıl önce sağ omuzunda kitle nedeni ile opere edilen ve parakordoma tanısı olan 28 yaşında erkek hasta sunulmaktadır. Hastada ilk ameliyatından sonraki iki yıl içinde iki kez lokal nüks gelişmişti. Son olarak hasta metastatik sol retroorbital kitle ile başvurdu. Retroorbital kitleye parsiyel eksizyon yapıldı ve patolojik inceleme ilk tanısı ile uyumlu olarak myoepitelyal tümör metastazı şeklinde rapor edildi. Sistemik değerlendirmede multipl akciğer metastazı ve sağ sakroiliak eklemden metastaz tespit edildi. Sakroiliak ve retroorbital kitlelere palyatif radyoterapi tamamlandıktan sonra kemoterapi başlandı. Kemoterapi rejimi ifosfamid, mesna ve doxorubisinden oluşmaktaydı. Kemoterapi sonrası değerlendirmelerde akciğer nodüllerinde ve retroorbital kitlede hafif regresyon görüldü. PET/BT'de sakroiliak metastazda 18-FDG tutulumu yoktu. Sonuç olarak, parakordomalar metastatik potansiyelleri nedeni ile yakın takip edilmelidir. Sistemik kemoterapide doxorubisin ve ifosfamid başarı ile kullanılabilir.

Anahtar Sözcükler: Parakordoma, metastaz, radyoterapi, kemoterapi

Geliş Tarihi: 28.11.2013

Kabul Tarihi: 19.03.2014

INTRODUCTION

Parachordoma is a very rare tumor that is histologically resembling chordoma but occurring in the non-axial deep-seated soft tissues of the extremities or in the skin. The first description is credited to Laskowski in 1951 (1). The 2002 World Health Organization classification has included parachordomas in the same class as mixed tumors and myoepitheliomas. Parachordoma is a soft tissue tumor characterized by an indolent nature with some potential for local recurrence, normally in a range from 3 months to 12 years after surgery. The histogenesis of parachordoma is still uncertain, and its histology is similar to that of chordoma. The metastatic potential of this tumor remains poorly defined, and overall, there have been very few cases that have been reported. Different chemotherapy regimens have been used for metastatic parachordoma and there is no consensus as to which regimen is the most effective.

CASE REPORT

A 28-year-old male was initially diagnosed with parachordoma after surgical removal of a mass in his right shoulder. He had initially presented to the orthopedic surgery clinic at Dicle University School of Medicine Hospital with a mass of the right shoulder for 5 years and increasing symptoms of pain for the last few months. Magnetic resonance imaging (MRI) revealed a septated cystic lesion (4x1.5 cm) with smooth borders in the right subacromial/subdeltoid region. Other systemic evaluations were normal.

A surgical excision of the mass was performed. On pathologic evaluation, macroscopic examination revealed pieces of tissue grayish in color with irregular borders and a piecemeal appearance. The section surface was grayish with a solid appearance and contained scattered myxoid areas. Microscopically, there was no tumor involvement at the resection margin.

Address for Correspondence / Yazışma Adresi: Sener Cihan, MD, Department of Medical Oncology, Okmeydani Education and Research Hospital 34100 Sisli, Istanbul, Turkey Phone: +90-532-4070379 Fax: +90-212-3145550 E-mail: drsenercihan@yahoo.com

©Telif Hakkı 2014 Gazi Üniversitesi Tıp Fakültesi - Makale metnine <http://medicaljournal.gazi.edu.tr/> web adresinden ulaşılabilir.

©Copyright 2014 by Gazi University Medical Faculty - Available on-line at web site <http://medicaljournal.gazi.edu.tr/>

doi: <http://dx.doi.org/10.12996/gmj.2014.21>

The tumor consisted of a collagenous and fibromyxoid stroma and oval to round pleomorphic cells with an epithelioid appearance and having clear cytoplasm and occasional vacuoles. A moderate degree of mitotic activity was noted. Reticular nodular pattern, an adenoid-like structure and cords in a focal manner were seen (Figure 1). The tumor cells stained with cytokeratin (CK) 8/18 S-100, Pan CK, Epithelial Membrane Antigen (EMA) and vimentin but did not stain with thyroglobulin, chromogranin-A, HMB-45, Melan-A or Glial Fibrillary Acidic Protein (GFAP). A parachordoma/mixed tumor diagnosis was made. Chemotherapy or radiotherapy as adjuvant treatment were not performed and a close follow-up was suggested.

Local recurrence developed twice during follow-up in the first and the second years. Local excision was performed for both recurrences at the same center. Histological features were similar to those found at the first biopsy, thus diagnosis was confirmed. Local radiotherapy was performed only at the last local recurrence.

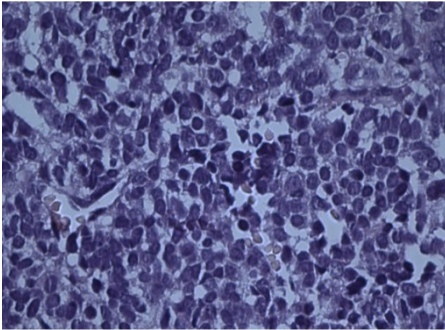


Figure 1. Tumor cells with moderate nuclear atypia with prominent nucleoli and large hyperchromatic nuclei (hematoxylin and eosin, x400)

The patient was admitted to the medical oncology service three years after the initial diagnosis with exophthalmus in his left eye. His work up revealed a 3 cm mass in the left retro-orbital fossa. The patient underwent partial surgical resection and the pathologic evaluation was reported as “myoepithelial tumor metastasis” based on immunohistochemistry due to the positivity for PanCK (Figure 2a), S-100 (Figure 2b) and EMA (Figure 3), especially since this immunoprofile was consistent with the primary tumor that was resected three years ago.

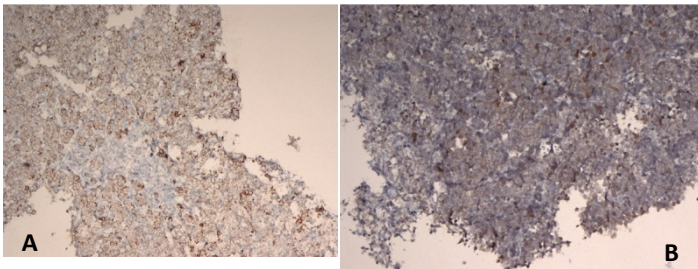


Figure 2. (A) PAN CK positivity in tumor cells (x100). (B) S-100 positivity in tumor cells (x100).

The patient’s systemic staging work up showed bilateral pulmonary metastatic nodules approximately 1 centimeter in size, and a 4-centimeter metastasis in the right sacroiliac joint. There was no FDG uptake in the pulmonary nodules on the PET-CT that was obtained afterwards, however the sacroiliac mass had a maximum SUV of 10 (figure 4a).

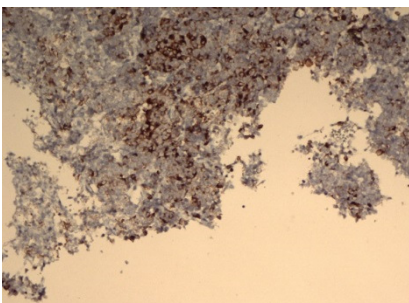


Figure 3. EMA positivity in tumor cells (x100).

The patient’s primary complaints were pain in the left retro-orbital region as well as in the right sacroiliac area (Figure 4c). Therefore, the decision was to start with palliative radiotherapy for both of these areas. After the radiotherapy was completed, palliative chemotherapy was initiated. The regimen consisted of ifosfamide 2 gr/m² for 3 days, mesna 2 gr/m² for 3 days and doxorubicin 50 mg/m² for one day (IMA), and this regimen was repeated every 21 days for a total of 6 cycles. Follow-up evaluation and imaging studies revealed minimal decrease in size in the pulmonary nodules and the retro-orbital mass. There was no FDG uptake in the sacroiliac mass on the new PET-BT (Figure 4b). The patient clinically benefited from the radiotherapy and chemotherapy treatments and reported significant decrease in his pain. At the time that this report was written, five years after the initial diagnosis and two years after the diagnosis of metastasis, the patient was alive and well with no sign of tumor recurrence and no evidence of new metastatic disease.

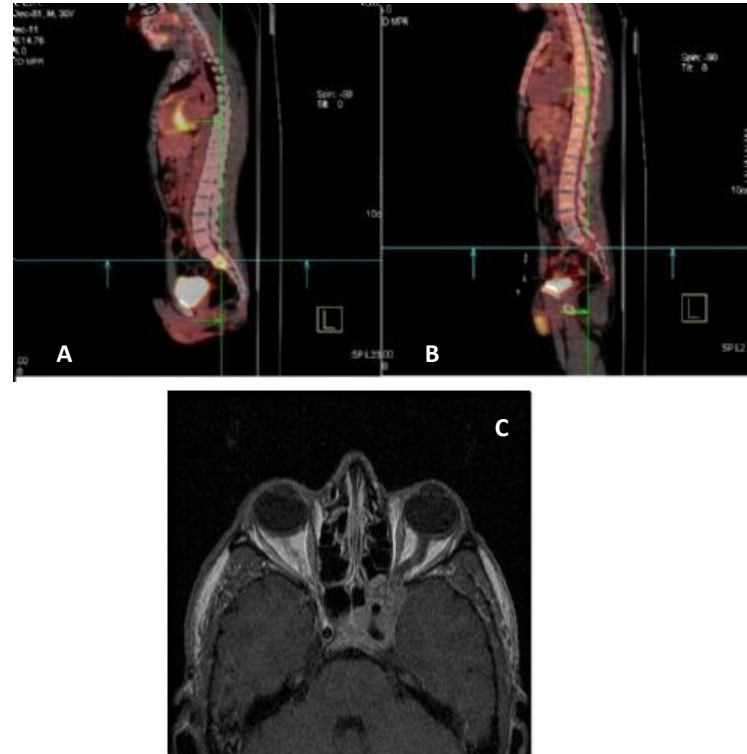

Figure 4. Pathological 18F-FDG uptake in the sacroiliac joint at time of diagnosis (a) and metabolic complete response after chemotherapy (b). Left retroorbital mass in orbital magnetic resonance T1-section imaging (c).

DISCUSSION

Currently, parachordoma is considered a part of the broad morphological and immunophenotypic spectrum of soft tissue myoepithelioma/mixed tumors. The histogenesis of parachordoma is still uncertain. Parachordomas are usually seen in adults. Silverberg et al reported the age ranged from 3 to 83 with a mean age of 39 in their 101 case series (2). The lesion is reported to be seen more commonly in males. The lower extremities are the most frequent location. According to Silverberg’s series, the localization of tumors among the 101 cases was distributed as lower extremity in 41, upper extremity in 35, head and neck in 15 and the body in 10 cases (3). Our case was male and the tumor was located in the shoulder. Parachordomas are usually painless tumors and are encountered as slow-growing masses. However, two painful cases with a subperiosteal location have been reported. The tumor was painful in our case and pain was the main presenting symptom. Complete surgical resection alone is usually curative, and recurrences and metastases are rare. Our patient had a local recurrence in his first year after resection of the primary tumor. Metastatic potential in parachordoma has been poorly described in previous reports. There are reports of a forearm parachordoma with lung metastasis and a chest wall parachordoma with lymph node metastasis in the literature (4).

There are contradictory views on the surgical margins and recurrence association in the literature. Surgical treatment alone can provide cure in most cases but tumors that recur can be seen after incomplete resection. There is no clear relationship between the status of the surgical margins and local recurrence but local recurrences and metastases are more frequent in patients with a histologically malignant appearance.

Parachordomas are benign tumors, but metastases and recurrences are not unusual. Dabska has reported recurrences after 7, 2 and 12 years, but Niezabitowski et al. have reported a recurrence at 3 months, Carstens et al. at 6 months and Ishida et al. at 1 year, although early recurrence is rare (5,6). However, it is difficult to determine the mean rate of recurrence due to the difficulty of long-term follow-up.

There have been six reported cases of metastases from parachordoma (table 1). The first report by Miettinen et al. describes a "chordoma-like" sarcoma in a 67-year-old woman with metastatic disease to the lung who died of the disease 11 months after presentation (7). However, the pathologic features were more consistent with chordoma than parachordoma. Carstens described a metastatic case arising in the buttocks with widespread disease, with death resulting 14 months after local recurrence (8). However, again the pathology was more like chordoma than parachordoma. These two studies were included previously in the parachordoma literature, but given the inconsistent nature of the pathology, we believe they should be discounted. The most recent report of metastatic disease is from Kinoshita and Yasoshima (9). The patient was a 60-year old man with primary parachordoma in his left calf who died 4 months after surgery from lung and brain metastases. Two deaths from metastatic parachordoma have been reported in the literature and it has been said that parachordomas may potentially be low-grade sarcomas.

Table 1. Clinical findings of metastatic parachordoma case reports

Authors (year)	Age	Gender	Primary site	Metastatic site	Treatment of metastasis	Survival*
Limon et al. ¹³ (1998)	52	Female	Chest	Lymph node	Metastectomy	24 months/alive
Abe et al. ¹⁰ (2003)	68	Male	Calf	Lung	CYVADAC*	19 months/exitus
Kinoshita et al. ⁹ (2007)	60	Male	Calf	Lung, brain	No	1 month/exitus
Guedes et al. ⁴ (2008)	6	Female	Forearm	Lung	IMet***	Unspecified
Lococo et al. ¹¹ (2012)	39	Female	Left hip	Lung	Metastectomy Imatinib	10 months/alive
Yildirim et al. ¹⁴ (2013)	49	Male	Inguinal	Testis and hip	Metastectomy Radiotherapy	5 months/alive

* Survival was defined as the time from metastasis to death or the last visit

** CYVADAC: Doxorubicin, vincristine, cyclophosphamide and dactinomycin

***IMet: ifosfamide/mesna and etoposide

Parachordomas are benign tumors, but they can become malignant when recurrence occurs after a short period and cases should therefore be followed-up closely. Different chemotherapy regimens have been used for metastasis of parachordoma and there is no consensus which regimen is the most effective.

Guedes et al. used chemotherapy with a combination of ifosfamide/mesna plus etoposide in a patient with lung metastasis from parachordoma (4). Unfortunately, suspect areas of lung metastasis were found to be enlarged in the follow-up control x-rays 5 months after chemotherapy. Systemic chemotherapy (CYVADACT), including doxorubicin (ADR), vincristine (VCR), cyclophosphamide (CPM), and dactinomycin (Act-D) have been used by Abe et al. in another patient with lung metastasis from parachordoma (10).

The dosages of each drug were as follows: ADR 60mg/m², VCR 1.5 mg/m² for 3 courses, CPM 1000 mg/m² for 3 courses and Act-D 1.5 mg/m². After 1 cycle of the adjuvant chemotherapy, development of lung lesions was not obvious. New bone metastases were found in the right scapula and left distal metaphysis of the femur.

Imatinib is another agent that was used in a patient with lung metastasis from parachordoma in the literature. Lococo et al. reported a case with single pulmonary metastasis who had been operated on 4 years earlier for a parachordoma of the iliopsoas muscle (11). After metastasectomy, imatinib 400 mg/daily was started as adjuvant therapy and was administered for 10 months. At the end of this period, the patient was reported to be still alive.

For our patient we used an IMA (ifosfamide/mesna and doxorubicin) regimen, which is generally accepted with metastatic sarcomas (12). According to the results of our case, it is appropriate to consider that some parachordomas may behave as malignant tumors with distant metastasis, and such cases should be treated as sarcoma.

CONCLUSION

The clinical follow-up of the primary site is important because of the significant potential for local recurrence in parachordoma. In addition, long-term follow-up, including lung CT and bone scintigraphy are important in cases of locally invasive and/or recurrent tumors because of their metastatic potential. To clarify the exact nature of parachordomas, more clinicopathologic data with closer and longer follow-up information on larger number of patients is required for this quite rare tumor.

Conflict of Interest

No conflict of interest was declared by the authors.

REFERENCES

- Laskowski J. Zarys onkologii. In: Pathology of tumors. Kolodziejska H, ed. PZWL, 1955;91-9.
- Silverberg SG, DeLellis RA, Frable WJ et al. Silverberg's Principles and Practice of Surgical Pathology and Cytopathology. 4th ed., Philadelphia, Churchill Livingstone, 2006; 395-6.
- Hornick JL, Fletcher CD. Myoepithelial tumors of soft tissue: a clinicopathologic and immunohistochemical study of 101 cases with evaluation of prognostic parameters. *Am J Surg Pathol* 1997; 27:1183-96.
- Guedes A, Barreto BG, Barreto LG et al. Metastatic parachordoma. *J Cutan Pathol* 2009; 36:270-3.
- Dabska M. Parachordoma: a new clinicopathologic entity. *Cancer* 1977; 40:1586-92.
- Fisher C, Miettinen M. Parachordoma: a clinicopathologic and immunohistochemical study of four cases of an unusual soft tissue neoplasm. *Ann Diagn Pathol* 1997; 1:3-10.
- Miettinen M, Gannon FH, Lackman R. Chordomalike soft tissue sarcoma in the leg: a light and electron microscopic and immunohistochemical study. *Ultrastruct Pathol*. 1992;16:577-86.
- Carstens PH. Chordoid tumor: a light, electron microscopic, and immunohistochemical study. *Ultrastruct Pathol*. 1995;19: 291-5.
- Kinoshita G, Yasoshima H. Case report: fatal parachordoma. *J Orthop Sci*. 2007;12:101-6.
- Abe S, Imamura T, Harasawa A et al. Parachordoma with multiple metastases. *J Comput Assist Tomogr*. 2003;27:634-8.
- Lococo F, Cesario A, Meacci E et al. Pulmonary Metastases From Parachordoma. *The Annals of Thoracic Surgery* 2009;88:9-10.
- Antman K, Crowley J, Balcerzak SP et al. An intergroup phase III randomized study of doxorubicin and dacarbazine with or without ifosfamide and mesna in advanced soft tissue and bone sarcomas. *J Clin Oncol*. 1993;11:1276-85.
- Limon J, Babinska M, Denis A, Rys J, Niezabitowski A. Parachordoma: a rare sarcoma with clonal chromosomal changes. *Cancer Genet Cytogenet*. 1998;102:78-80.
- Yildirim M, Şahin H, Badem H, et al. Recurrent metastasis of progressive parachordoma of spermatic duct to different sites in a year: A rare case. *J Clin Exp Invest* 2013; 4: 377-9.