

A COMPARATIVE STUDY OF METRONIDAZOLE 1 % CREAM VERSUS AZELAIC ACID 20 % CREAM IN THE TREATMENT OF ACNE

A Burhan AKSAKAL, M.D., Melih KORUYUCU, M.D., Meltem ÖNDER, M.D.,
Murat Orhan ÖZTAŞ, M.D., Mehmet Ali GÜRER, M.D.

Gazi University, Faculty of Medicine, Department of Dermatology, Ankara, Turkey
Gazi Medical Journal 1997; 8 : 144-147

SUMMARY :

Purpose : In acne vulgaris, a variety of therapies with different mechanisms of action are available. This study, which aims to compare the efficacy and skin tolerance of metronidazole cream and azelaic acid (AZA) cream in the treatment of moderate to severe acne, appears to be the first of its kind. **Methods :** Forty patients with only moderate to severe acne participated in this randomized, comparative study. In this study, according to the Allen Smith Scale, 15 patients were grade 8; 11 patients grade 6; and 14 patients were grade 4 acne. Twenty of them were treated with the AZA 20% cream and the other twenty patients were treated with the metronidazole cream 1% for three months. **Results :** The results of this study showed that the AZA cream is more effective than the metronidazole cream in reducing counts of inflamed and non-inflamed lesions of acne ($p < 0.001$). **Conclusion :** In moderate and severe acne, it is a waste of time to use only metronidazole cream topically.

Key Words: Acne, Metronidazole, Azelaic Acid

INTRODUCTION

Acne is the most common skin disease characterized by inflamed lesions, and it effects the whole pilosebaceous follicle (1, 2). It is usually first noted during the teenage. Some degree of acne develops in as much as 80 % of adolescents.

The pathogenesis of acne is multifactorial that influences the development of acne, excessive sebum production, abnormal desquamation of sebaceous follicle epithelium, and proliferation of *Propionibacterium acnes*, resulting in inflammation. Clinical manifestations of acne may range from noninflammatory comedones to inflammatory papules, pustules, and cysts (2-5).

The spectrum of topical and systemic therapies

includes agents that target each of the pathogenic factors. Topical application of azelaic acid (AZA) 20 % is markedly more effective in reducing numbers of comedones, papules and pustules in patients with mild to moderate acne (6, 7). On the other hand, metronidazole, an imidazole, has been shown to be effective in reducing acne inflammation when administered orally (8). In this study, we were compared the efficacy and skin tolerance of metronidazole 1 % cream and 1 % AZA 20 % cream in the treatment of moderate to severe acne.

MATERIALS AND METHODS

Forty patients (17 male, 23 female), with an average age 19.2 (age range, 14-27 years), were

included in this study (Table 1). Only moderate to severe acne cases participated in this randomized, comparative study investigating the efficacy and tolerability of metronidazole 1% cream and AZA 20% cream.

The objective clinical assessment was performed according to the Allen-Smith Scale (9). Only patients suffering from grade 4 to grade 8 acne participated in this study. The patients had not been treated with agents active against acne for one month as topically and three months as systemically preceding the start of the trials. Grounds for exclusion were known drug allergies, alcohol abuse, pregnancy, and lactation. In this study, 15 patients had grade 8; 11 patients grade 6; and 14 patients were grade 4 acne. Twenty of them were randomly selected for treating with the AZA 20 % cream (Scheing, İstanbul, Türkiye). Six of them had grade 8; four patients had grade 6; and 10 patients had grade 4 acne. The other twenty randomly elected patients with acne entered to the metronidazole 1% cream (Orva, İzmir, Türkiye) treatment. In this group, nine patients had grade 8; seven patients grade 6, and four patients had grade 4 acne. The drugs were applied to the face, limited by the hair border and the mandibular arch, twice daily for 12 weeks by the patients who were not allowed to use another medicine.

The differences between the acne scores of the two groups were compared with Mann-Whitney U test, and Freedman Variance Analysis test was used for the evaluation of acne score variances during treatment. We also used Wilcoxon Rank Sum W test for the determination of the month that the most significant change occurred.

RESULTS

The study was completed with 40 patients. None of them were excluded due to severe side

effects. We observed mild contact dermatitis only in one patient, but it did not preclude treatment.

Twenty patients applied AZA cream to their faces for three months. At the end of three months, acnes of the two patients in grade 8 group did not change. At the same time, the grade of acnes decreased to grade 6 in two, to grade 4 in one, and to grade 2 in one patient. The severity of the acne was the same in two patients of grade 6 group. One patient was in grade 4 and the other was in grade 2 at the end of three months. Only one of the ten patients with grade 4 acne was observed unchanged. Besides, two of them healed completely and seven of them were degraded to grade 2 (Table-1).

When we evaluate the patients treated with metronidazole, acnes of six out of nine patients with grade 8 acnes were still the same as before the treatment. Acnes of other three patients with grade 8 reduced to grade 6. After three months, 5 among 7 patients with grade 6 acnes remained unchanged. Acnes of other two patients decreased to grade 4. One of the four patients with grade 4 acnes had more lesions than before the treatment. He was upgraded to grade 6 during treatment. Also, one of them did not respond to treatment and stayed at grade 4 level. Lesions of the other two patients decreased to grade 2 (Table 1).

The differences between the acne scores of the two groups were compared with Mann-Whitney U test and no significant difference was found ($P>0.05$).

Freedman Variance Analysis test was used for the evaluation of acne score variances during treatment. As a result of this test, the difference before and after treatment was significant for patients treated with AZA 20 % cream ($P<0.001$). The difference for the group treated with metronidazole 1 % cream was insignificant

PATIENTS	Before Treatment		After Treatment	
	M	AZA	M	AZA
Male/Female	14/6	2/18	14/6	2/18
Acne Grade				
0	-	-	-	2
2	-	-	2	9
4	4	10	3	3
6	7	4	9	4
8	9	6	6	2

Table - 1 : Summarized results of the treatments.

($P>0.05$). As the significant changes were seen in patients treated with AZA 20 % cream, we also used Wilcoxon Rank Sum W test for the determination of the month that the most significant change occurred. We observed most significant changes in

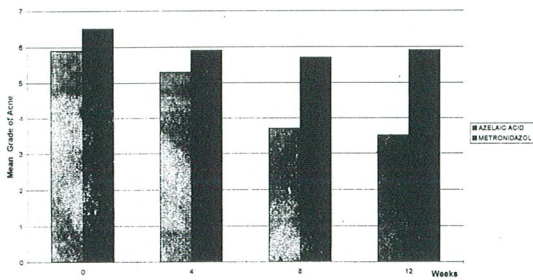


Fig - 1 : Changing of acne grade by time.

the second month of the treatment ($P<0.05$) (Fig. 1).

DISCUSSION

Like oral metronidazole, the effect of topical metronidazole cream may be anti-inflammatory rather than antimicrobial (10,11). In vitro, it has been shown to inhibit the anaerobic growth of *Propionibacterium acnes* and significantly reduce the generation of neutrophil reactive oxygen species, which are potent oxidants capable of causing tissue injury at sites of inflammation. In addition, it impedes the leukocyte chemotaxis (11). Its effect on acne, therefore, probably depends on its anti-inflammatory action (8, 10, 11). Whereas neutrophil chemotaxis and phagocytosis, as well as reactive oxygen species, are not significantly effected in the presence of AZA, it appears to retard the conversion of testosterone to dihydrotestosterone through competitive inhibition of 5 α -reductase (6). This may be one mechanism in treating acne (1, 5). AZA possesses bacteriostatic properties in vitro against a variety of aerobic microorganisms, including *Staphylococcus aureus*, *Staphylococcus epidermidis*, *Proteus mirabilis*, *Escherichia coli*, *Pseudomonas aeruginosa*, *Candida albicans*, and the anaerobic *Propionibacterium acnes*, while at high concentrations it is bactericidal against

Staphylococcus epidermidis and *Propionibacterium acnes* (7). AZA also acts as an antikeratinizing agent and influences the differentiation of human keratinocytes in vivo (6, 7).

We observed in our study that treatment of patients with moderate or severe acne with AZA 20% cream topically was superior to treatment with metronidazole 1 % cream topically. In the literature, there were a few reports about the usage of metronidazole cream topically in the treatment of acne. In one study, it was reported that metronidazole 0.75% cream was ineffective for mild and moderate acne (8). In another study, it was found that the combination of metronidazole 2% and benzoyl peroxide 5% was superior to single use of benzoyl peroxide 5% (10).

In our study, we found no significant results although we used 1% cream instead of 0.75%. Another observation, which was not significant statistically, was that in severe acne and at the beginning of treatment with metronidazole 1 % cream, there was mild recovery of the lesions. But this effect was very mild and transitional.

In this study, the topical treatments with AZA or metronidazole were compared in moderate and severe acne. In our opinion, AZA must be the treatment of choice.

Correspondence to : Dr.Burhan AKSAKAL
Gazi Üniversitesi Tıp Fakültesi
Dermatoloji Anabilim Dalı
Beşevler
06500 ANKARA - TÜRKİYE
Phone : 312 - 214 10 00 / 6106
Fax : 312 - 212 90 18

REFERENCES

1. Nguyen QH, Kim YA, Schwartz AR: Management of acne vulgaris. *Am Fam Physician* 1994; 50 : 89-96.

2. Leyden JJ: New understandings of the pathogenesis of acne. *J Am Acad Dermatol* 1995; 32 : 15-25.
3. Berson DS, Shalita AR: The treatment of acne: The role of combination therapies. *J Am Acad Dermatol* 1995; 32: 31-41.
4. Kaminer MS, Gilchrist BA: The many faces of acne. *J Am Acad Dermatol* 1995; 32: 6-14.
5. Hunt MJ, Barnetson R StC: A comparative study of gluconolactone versus benzoyl peroxide in the treatment of acne. *Australas J Dermatol* 1992; 33: 131-134.
6. Nguyen QH, Bui TP: Azelaic acid: Pharmacokinetic and pharmacodynamic properties and its therapeutic role in hyperpigmentary disorders and acne. *Int J Dermatol* 1995; 34 : 75-84.
7. Fitton A, Goa KL: Azelaic acid: A review of its pharmacological properties and therapeutic efficacy in acne and hyperpigmentary skin disorders. *Drugs* 1991; 41 : 780-798.
8. Tong D, Peters W, Barnetson R StC: Evaluation of 0.75 % metronidazole gel in acne, a double blind study. *Clin Exp Dermatol* 1994; 19: 221-223.
9. Allen BS, Smith JG: Various parameters for grading acne vulgaris. *Arch Dermatol* 1982; 118: 23-25.
10. Nielsen PG: Topical metronidazole gel: Use in acne vulgaris. *Int J Dermatol* 1991; 30 : 662-666.
11. Thiboutot DM: Acne rosacea. *Am Fam Physician* 1994; 50 : 1691-1697.