

RESEARCH ARTICLES

THE DENSITIES OF T CELLS, LANGERHANS CELLS, AND NATURAL KILLER CELLS IN UNINVOLVED SKIN OF PATIENTS WITH ACNE VULGARIS

A.Burhan AKSAKAL, M.D., Ayla GÜLEKON, M.D., Özlem ALTAY, M.D., Cem SEZER*, M.D.,
Murat Orhan ÖZTAŞ, M.D.

Gazi University, Faculty of Medicine, Departments of Dermatology and Pathology *,
Ankara, Turkey
Gazi Medical Journal 1997; 8 : 47-50

SUMMARY

Purpose : Acne Vulgaris(AV) is a disease which affects the whole pilosebaceous follicle and results in the formation of non-inflamed and inflamed lesions. The initial event in AV inflammation may be the disruption of follicular epithelium, which allows the comedo to come in contact with inflammatory systems. The purpose of the present work was to investigate the inflammatory infiltrating cells in early AV lesions. **Methods :** We examined 25 biopsies; 10 of them were moderate to severe acne cases and 15 of them were healthy control patients. All specimens evaluated for the density of the CD3+ (total T lymphocyte) cells, CD4+ (helper/inducer T lymphocyte) cells, CD8+ (suppressor/cytotoxic T lymphocyte) cells, CD1a+ (Langerhans) cells, and CD56+ (Natural Killer) cells in the epidermis and dermis, immunocytochemically. **Results :** Only the CD4+ cells were found to be significantly elevated in the dermis of patients with AV, compared to healthy subjects ($p<0.05$). **Conclusion :** The finding of CD4+ cell elevation in the intact skin of patients with AV suggests that systemic factors influence the pathologic process.

Key Words : Acne Vulgaris, T Lymphocyte Subsets, Langerhans Cells, Natural Killer Cells.

INTRODUCTION

Acne Vulgaris (AV), both aetiologically and pathologically, is a multifactorial disease. A variety of lesions are associated with AV, varying from the more benign looking whiteheads and blackheads to a range of inflammatory lesions including papules, pustules, and deeper nodules and cysts (1, 2). The key unanswered question is the identification of the mediators responsible for altering the follicle wall and triggering the inflammatory cascade. The theory is put forward that hydrolytic enzymes and reactive oxygen species released by neutrophils promote tissue damage, facilitating the release of intrafollicular

material into the dermis and thereby, triggering in the inflammatory cascade. Some acne specialists still believe that the earliest cellular infiltrate in acne is predominantly neutrophilic. The study of "timed" lesions showed that the initial infiltrate in of the developing inflammatory lesions was mononuclear (predominantly CD4+) T lymphocytes (2, 3). Little is known of the inflammatory mediators other than complement present in AV lesions (4, 5, 6). The release of intracomedonal interleukin-1 (IL-1) into the dermis following spongiosis or rupture of the follicle wall represents another alternative mechanism for the transition to the inflammatory

stage of AV (2, 6). This study was planned to evaluate the densities of T lymphocytes, Langerhans cells, and natural killer (NK) cells in the epidermis and dermis of patients with moderate or severe AV, since these cells are responsible for the production and excretion of cytokines that are thought to have important roles in AV etiopathogenesis. To assess the role of cellular immunity in early AV lesions, we studied the densities of CD4+, CD8+, CD3+, CD56+ and CD1a+ cells in apparently healthy skin adjacent to acneic lesions by immunohistochemical methods.

MATERIALS AND METHODS

Two groups were studied. The first group included 10 patients (7 male, 3 female) with intermediate or high grade AV. Patient complaints were scored according to the Allen-Smith scale (7). The second group (control group) included 15 healthy subjects (11 male, 4 female). 0.5 cm punch biopsies were obtained from pilosebaceous unit rich skin adjacent to lesions of patients with AV and control group. Each specimen was washed in saline, embedded in tissue-tek, stored frozen at - 55 C until use. Cryostat sections, 4 mm thick, were placed on poly-L-Lysine treated glass slides and fixed in cold acetone for 10 min. After washing in tris buffered saline(TBS) the slides were incubated with blocking normal goat serum for 20 min. Primary antibodies were applied for 1 h at room temperature. The monoclonal mouse antibodies were as follows: CD3+(Dako-4B5), CD4+(Dako-MT310), CD8+(Dako-DK5), CD1a+(Dako-NA 1/34), CD56+(Dako-T199). Further steps were carried out using Alkaline Phosphatase Anti Alkaline Phosphatase (APAAP) (Dako-K670) kit. After several washings with TBS, the sections were subsequently incubated with biotinylated link antibody for 30 min and then with alkaline phosphatase labeled streptavidin for an additional 30 min. Naphtol phosphate as substrate and new fuchsin as chromogen were applied for demonstration of the immune reactions. After being washed with TBS, the slides were counterstained with hematoxyline. Fresh frozen tonsil was used as positive control tissue (8).

On microscopic examination, only membranous staining was considered to be positive. The positively stained infiltrating cells were observed in the superficial dermis (Fig. 1). The positive cells were counted per 5 microscopic fields at a magnification of x 200 and the mean

number of cells were determined. The mean values of the infiltrating cell populations were reevaluated comparatively in 10 AV patients and 15 control subjects, and the differences between the infiltrating cell populations were determined.

Mann-Whitney U test was used for statistical analysis when comparing two groups. The conformity of the data of each group to normal distribution was tested with the Kolmogorov-Smirnov test. The two groups were compared to each other with Kruskal Wallis H test (9).

RESULTS

AV patients' ages were 16-33 (mean 20.7) years. Their disease durations were 1-10 (mean 3.9) years. AV scores were 4-8 according to the Allen- Smith scale. The control group's ages were 16-53 (mean 31.3) years. CD3+, CD4+, CD8+, CD1a+, CD56+ cells were evaluated quantitatively by means of immunohistochemical methods in both 10 patients with AV and 15 control subjects (Fig. 1). The cell numbers infiltrating the epidermis and dermis in both groups are given in Table I (Table 1). The results of the statistical analysis were as follows :

CD3+ cells: There was no difference between the number of cells infiltrating the epidermis or dermis of the AV and control groups ($p > 0.05$).

CD4+ cells: Higher in dermis of the AV group than the control group ($p < 0.05$), but not different in epidermis ($p > 0.05$).

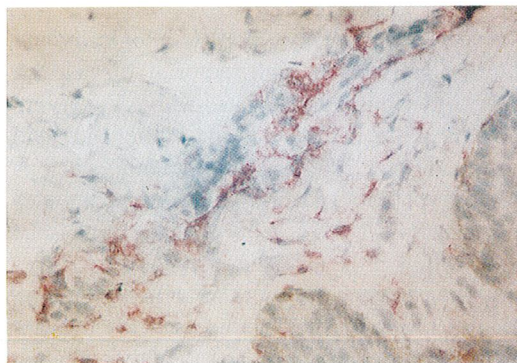


Fig 1 : (Naphtol - New Fuchsin x 200) Membranous staining with CD4+ cells in a patient with AV is seen in the superficial dermis.

		CD3+		CD4+		CD8+		CD1a+		CD56+	
		E	D	E	D	E	D	E	D	E	D
ACNE GROUP (n=10)	RANGE	0-0.5	0.1-1	0-0	0-1.2	0-0.4	0-0.5	0-0.6	0-0.3	0-1.0	0-0.4
	MEAN	0.14	0.47	0	0.30	0.04	0.18	0.20	0.19	0.23	0.17
CONTROL GROUP (n=10)	RANGE	0-0.5	0-1	0-1	0-0.6	0-1	0-.04	0-1	0-0.5	0-0.2	0-0.3
	MEAN	0.14	0.43	0.14	0.14	0.11	0.10	0.33	0.21	0.05	0.09

E : Epidermis D : Dermis

Table - 1 : The distribution and mean values of CD+ cells in the groups of acne patients and control subjects.

CD8+ cells: There was no difference between the number of cells infiltrating the epidermis or dermis of the AV and control groups ($p>0.05$).

CD56+ cells: There was no difference between the number of cells infiltrating the epidermis or dermis of the AV and control groups ($p>0.05$).

CD1a+ cells: There was no difference between the number of cells infiltrating the epidermis or dermis of the AV and control groups ($p>0.05$).

DISCUSSION

Abnormal keratinization of the pilosebaceous follicle is recognized as a primary event in AV. This alteration in the maturation of the follicular epithelium results in the formation of microcomedones and visible comedones composed of compacted keratinous material, accumulated sebum, and microbial organisms. The subsequent progression to inflammatory lesions appears to be due to the aggregation of PMNLs along the follicular wall, degenerative changes in the epithelial cells, and the leakage of follicular contents into the surrounding dermis(1, 10). However, studies of early AV lesions show that neutrophils may be present within apparently intact comedones, suggesting that soluble inflammatory factors may diffuse from comedones and that gross comedonal rupture is not the earliest event in AV inflammation (1). The demonstration of immunoreactants in the dermal blood vessels of the

clinically uninvolved skin of the patients with acne may support this concept (1). Norris and Cunliffe explored the role of cellular immunity in the initiation of AV lesions (3). They found that CD4+ lymphocytes were prominent in early AV lesions and suggested that their presence might be more than an epiphenomenon.

Most recently, Ingham et al. found significant levels of IL-1-like activity and tumor necrosis factor-like molecules in a majority of comedones (6). Release of intra-comedonal IL-1 into the dermis following spongiosis or rupture of the follicle wall represents another alternative mechanism for the transition to the inflammatory stage of AV (2, 6).

Being important antigen presenting cells (APCs), CD1a+ Langerhans cells are responsible for production of IL-1 and this results in activation of CD4+ cells(11,12). Our finding of no change in CD1a+ cells, which function mainly in epidermis, may be relevant with the occurrence of inflammatory process primarily in dermis. CD56+ NK cells are associated with nonlymphocyte cytokine production (12) and show no significant difference. We have found out that CD4+ cells in dermis were elevated when compared to the control group. This result, which is similar to those of Norris and Cunliffe (3), might indicate that the inflammatory process in AV is basically found in the dermis where the pilosebaceous follicles are

localized.

In conclusion, our finding of significantly elevated CD4+ lymphocytes, the most popular immunologic factor implicated in AV etiology, is in accordance with the literature (3). Although it is impossible to be certain whether the early stage alterations occur as systemic or local changes, with biopsies of apparently healthy skin adjacent to acneic lesions very rich from pilosebaceous units, the finding of CD4+ cells elevation in intact skin suggests that systemic factors influence this process.

Correspondence to : Dr.A.Burhan AKSAKAL
Gazi Üniversitesi Tıp Fakültesi
Dermatoloji Anabilim Dalı
Beşevler
006500 ANKARA - TÜRKİYE
Phone : 312 - 214 10 00 / 6129
Fax : 90 312 - 223 90 18

REFERENCES

1. Webster GF : Inflammation in acne vulgaris. *J Am Acad Dermatol* 1995; 33 : 247-253.
2. Cunliffe WJ, Eady A : A reappraisal and update on the pathogenesis and treatment of acne. *Current Opinion in Infectious Diseases* 1992; 5 : 703-710.
3. Norris JFB, Cunliffe WJ : A histological and immunocytochemical study of early acne lesions. *Br J Dermatol* 1988; 118 : 651-659.
4. Leeming JP, Ingham E, Cunliffe WJ : The microbial content and complement C3 cleaving capacity of comedones in acne vulgaris. *Acta Derm Venereol(Stockh)* 1988; 68 : 468-473.
5. Kersey P, Sussman M, Dahl M : Delayed skin test reactivity to propionibacterium acnes correlates with severity of inflammation in acne vulgaris. *Br J Dermatol* 1980;103 : 651.
6. Eady EA, Ingham E, Walters CE, Cove JH, Cunliffe WJ : Modulation of comedonal levels of interleukin-1 in acne patients treated with tetracyclines. *J Invest Dermatol* 1993;101:86-91.
7. Allen BS, Smith JG : Various parameters for grading acne vulgaris. *Arch Dermatol* 1982; 118 : 23-25.
8. Elias JM : Immunohistopathology: A Practical Approach to Diagnosis. Chicago: ASCP Press, 1990 : 1-90.
9. Neter J, Wasserman W, Whitmore GA : *Applied Statistics*.3rd ed. Massachusetts: Allyn and Bacon Inc1988: 493-541.
10. Esterly NB, Koransky JS, Furey NL, Trevisan M : Neutrophil chemotaxis in patients with acne receiving oral tetracycline therapy. *Arch Dermatol* 1984; 120 : 1308-1313.
11. Mc Fadden J : Immunology of psoriasis: A review of Waldimarsson's hypothesis. *Retinoids Today and Tomorrow* 1990; 18 : 31-33.
12. Rose NR, Conway de Macario E, Fahey JL, Friedman H, Penn GM : *Manual of Clinical Laboratory Immunology*.4th ed. Washington: American Society for Microbiology. 1992: 157-163.