

RETROPERITONEAL CASTLEMAN'S DISEASE ASSOCIATED WITH NEPHROTIC SYNDROME

A.Ziya ANADOL, M.D., B.Bülent MENTEŞ, M.D., Betül ÇELİK*, M.D.,
Ömür ATAĞLU*, M.D., Erdal YILMAZ, M.D.

Gazi University, Faculty of Medicine, Departments of General Surgery and Pathology*, Ankara, Turkey

Gazi Medical Journal 8 : 191-194, 1997

SUMMARY : *A case of Castleman's disease is reported, associated with persistent anemia and nephrotic syndrome. In addition to the rare incidence of this disease, renal involvement is infrequently seen in young patients who have histologically proven Castleman's disease or angiofollicular lymph node hyperplasia. The diagnostic and therapeutic aspects of this rare entity is discussed, with emphasis on its association with renal disease.*

Key Words : *Retroperitoneal, Castleman's Disease, Lymph Node Hyperplasia.*

INTRODUCTION

Castleman's disease or angiofollicular lymph node hyperplasia was first described as a lymphoid tumor of the mediastinum (1). Neck, pelvis, retroperitoneum or axilla may also be involved (2, 3). The etiology of the disease is still not clear, and the association of renal disease is infrequent (4). This case is presented to exhibit its rare coexistence with renal amyloidosis.

CASE REPORT

An 17-year-old girl was admitted for persistent anemia and swelling in the legs. She had a previous diagnosis of nephrotic syndrome, and she had been receiving colchicine and 40 g protein diet for eight months. On physical examination, she had a pale skin and slight edema in her lower extremities.

The results of routine laboratory tests were normal except for a hemoglobin level of 8.2 g and serum albumin level of 2.6 g/dl. The renal function tests suggested proteinuria of 5.7 g/day with a creatinine clearance of 64.2 ml/min. Her

abdominal ultrasound revealed a solid mass that compressed the inferior caval vein. Abdominal computed tomography demonstrated a 6x5 cm solid mass in the neighborhood of the right kidney. Intravenous pyelogram showed lateral deviation of the right ureter at L4-5 level. The results of the celiac, mesenteric and renal angiograms were completely normal. Percutaneous renal biopsy confirmed amyloidosis while percutaneous needle biopsy from the mass suggested malignant soft tissue sarcoma.

An exploratory laparotomy was carried out following transfusion of two units of packed red blood cells. At surgery, a retroperitoneally located, 5x7 cm, dark-yellow, solid mass near the right kidney was completely excised. Other intraabdominal structures were normal.

Pathologic Examination

The material was a white-coloured lobulated mass, which measured 6x4 cm in its longest diameters. The cross-section of the specimen was granu-

lar in appearance and there were also areas of hemorrhage. Multiple samples from the specimen were examined.

The microscopic examination of the specimens revealed a lymph node structure with numerous lymphoid follicles and some of these follicles showed vascular structures in their germinal centres which showed hyaline-like change (Fig 1). In the parafollicular areas, there were numerous plasma cells and the specimen also contained eosinophilic material which proved to be amyloid with Congo red (Fig 2). The final histopathological diagnosis

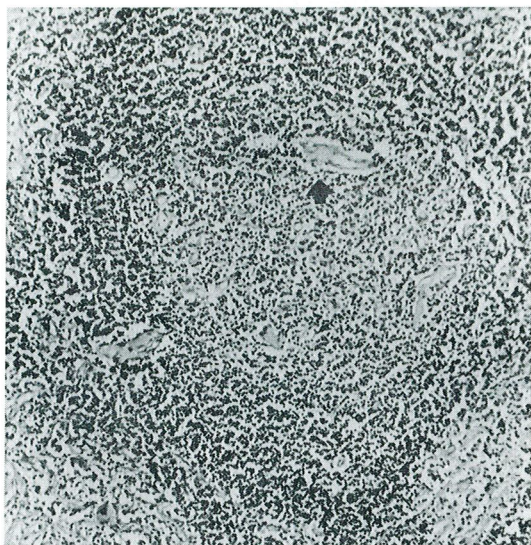


Fig. 1 : Lymphoid follicle with vascular structures in its germinal centre showing hyaline-like changes (Hematoxylen-Eosin, x100).

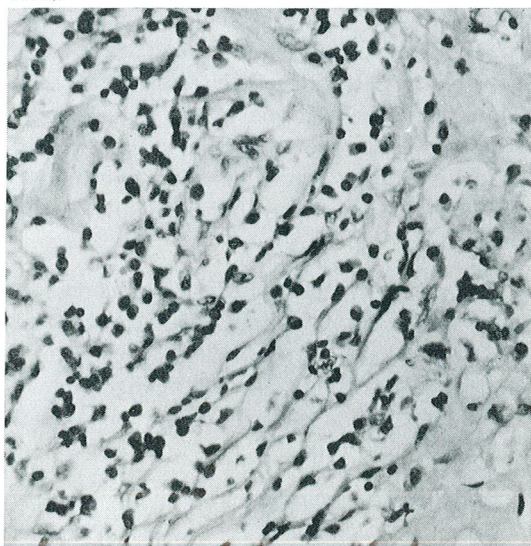


Fig. 2 : Numerous plasma cells and eosinophilic material which proved to be amyloid with Congo red (Hematoxylen-Eosin, x400).

was Castleman's disease of transitional (mixed hyaline-vascular and plasma cell) type.

The renal needle biopsy specimen measured 1 cm in its longest diameter. Histopathological examination revealed hyaline-like material deposition in the glomeruli of the kidney which was proved to be amyloid with the Congo red stain (Fig 3). It was concluded that the patient also had renal amyloidosis.

The postoperative course was uneventful and the patient has been well without recurrence for three years.

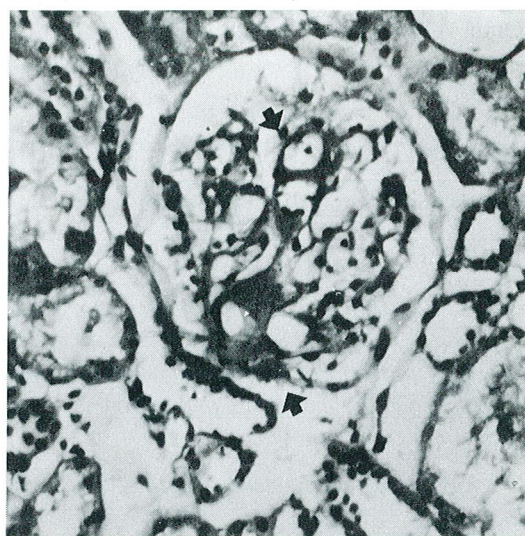


Fig. 3 : Hyaline like material deposition in the glomeruli of the kidney which proved to be amyloid with the Congo red stain (Congo red, x400).

DISCUSSION

Castleman's disease, also referred to as lymph node hyperplasia, lymph node hamartoma, or angiofollicular lymph node hyperplasia is an eponymus term which was first attributed to a lymphoid tumor of the mediastinum (1). Although the majority of the lesions occur within the chest as asymptomatic masses, other sites including the neck, pelvis, retroperitoneum, or axilla may also be involved (1, 2, 3). The etiology of the disease is still not clear. There is no sex predominance or no identifiable risk factor in the development of the disease. Three histological types have recently been described: hyaline-vascular, plasma-cell, and transitional (mixed) type. The first two types are usually localized diseases, whereas the transitional type is usually multicentric (1). The rare

multicentric form with associated systemic disorders may have an aggressive and sometimes fatal clinical course (5). In a few cases, malignant lymphoma, colonic carcinoma, or Kaposi sarcoma has developed (6, 7, 8). The hyalin-vascular type is more common and tends to be an isolated, asymptomatic mass encountered in adolescence, while the plasma-cell and mixed types are frequently seen in adults and can be multicentric and associated with systemic disturbances. The most common form of Castleman's disease is the hyalin-vascular type, followed by plasma cell type. The transitional or mixed type of Castleman's disease is the most infrequent type with areas of hyalin-vascular structures in the follicles and focal plasmocytosis (9). We also observed amyloid deposition in both the tumor and renal biopsy specimen. This finding is in keeping with the two cases of transitional (mixed hyaline-vascular and plasma cell) type localized Castleman's disease with amyloidosis described by Ordi et al (10). Our patient's pathologic examination revealed the characteristics of both the hyaline-vascular and plasma-cell types. Histologic findings similar to the multicentric form of Castleman's disease have been reported to associate the POEMS syndrome (polyneuropathy, organomegaly, endocrinopathy, monoclonal gammopathy and skin changes), and some authors consider them as overlapping entities (11, 12).

The systemic effects of Castleman's disease were first recognized in 1960's. Growth retardation, hypochromic anemia, hypergammaglobulinemia, myasthenia gravis, nephrotic syndrome, jaundice, or amyloidosis was thought to be due to some humoral factors (antierythropoietic factor, growth-inhibitor factor) secreted by the large mass (3). This circulating erythropoietin-inhibiting factor demonstrated in the serum of these patients may represent an antibody directed against circulating erythropoietin. The disappearance of these humoral factors on assays of patients' sera after the removal of the mass is the major clue of these effects (8). We can attribute the anemia and amyloidosis in our patient to the same factors. The association of renal disease is infrequent in Castleman's disease (4). To the best of our knowledge, only 10 cases have been well described as being accompanied by renal disorders. Among these 10 cases, only one was classified as the hyaline-vascular type, while the others were of

plasma-cell or mixed type. Histologic examination of the kidney was performed in six cases. The findings were minimal change (one case), membranous nephropathy (one case), interstitial nephritis (one case) and amyloidosis (three cases) (4). The common manifestation was nephrotic syndrome, as in our patient.

In cases of localized Castleman's disease, complete surgical excision is the treatment of choice (1, 2, 3). If this is not possible, partial excision may also be helpful. A variety of drugs including prednisolone, chlorambusil, or cyclophosphamide have been used in the multicentric form, alone or in combination, with variable results (3).

The present case was quite unusual for exhibiting renal involvement which is seldom seen in Castleman's disease. Although the mixed type of this disease tends to be multicentric and aggressive, our patient has yet been disease free after the removal of the mass; colchicine therapy has been stopped and her anemia disappeared with no further medical therapy.

Correspondence to : Dr.B.Bülent MENTEŞ
Gazi Üniversitesi Tıp Fakültesi
Genel Cerrahi Anabilim Dalı
Beşevler
06500 ANKARA - TÜRKİYE
Phone : 312 - 214 10 00 / 5747

REFERENCES

1. Reynolds SP, Gibbs AR, Weeks R, Adams H, Davies BH : Massive pleural effusion: an unusual presentation of Castleman's disease. *Eur Res J* 1992; 5 : 1150-1153.
2. Garber SJ, Shaw DG : Case report: The ultrasound and computed tomography appearance of mesenteric Castleman's disease. *Clin Radiol* 1991; 43 : 429-430.
3. Keller AR, Hochholzer L, Castleman B : Hyaline-vascular and plasma-cell types of giant lymph node hyperplasia of the mediastinum and other locations. *Cancer* 1972; 29 : 670-683.

4. Tsukamoto Y, Hanada N, Nomura Y, Hiki Y, Kasai K, Shigematsu H, Kobayashi Y : Rapidly progressive renal failure associated with angiofollicular lymph node hyperplasia. *Am J Nephrol* 1991; 11 : 430-436.
5. Debatin JF, Spritzer CE, Dunnick NR : Castleman disease of the adrenal gland: MR imaging features. *AJR* 1991; 157 : 781-783.
6. Cousineau S, Beauchamp G, Boileau JB : Extramedullary plasmacytoma associated with angiofollicular lymph node hyperplasia. *Arch Pathol Lab Med* 1986; 110 : 157-158.
7. Dickson D, Ben-Ezra JM, Reed J, Flax H, Janis R : Multicentric giant lymph node hyperplasia, Kaposi's sarcoma, and lymphoma. *Arch Pathol Lab Med* 1985; 109 : 1013-1018.
8. Ioachim HL : Angiofollicular Lymph Node Hyperplasia. In: *Lymph Node Pathology* 2nd ed. J.B. Lippincott Company, Philadelphia 1994 : 236-244.
9. Bertram Schinitzer : Reactive lymphoid hyperplasias. In: *Jaffe ES (ed). Surgical Pathology of the Lymph Nodes and Related Organs* 2nd ed. W.B.Saunders Company, Philadelphia 1995 : 110-118.
10. Ordi J, Grau JM, Junque A, Nomdedeu B, Palacin A, Cardesa A : Secondary (AA) amyloidosis associated with Castleman's disease. Report of two cases and review of the literature. *Am J Clin Pathol* 1993; 100 : 394-397.
11. Buijs L, Wijermans PW, van Groningen K, Gerrits WJB, Kluin Ph, Haak HL : Hyaline-vascular type Castleman's disease with concomitant malignant B-cell lymphoma. *Acta Haematol* 1992; 87 : 160-162.
12. Gherardi RK, Malapert D, Degos JD : Castleman disease - POEMS syndrome overlap. *Ann Int Med* 1991; 114 : 520-521.