

SELF-EXPANDABLE REMOVABLE PROSTHESIS

Ahmet GÖRGÜL, M.D., Burçak KAYHAN, M.D., Mehmet CİNDORUK, M.D.,
Zeynep AKI, M.D., Bülent MENTEŞ*, M.D., Selahattin ÜNAL, M.D.

Gazi University, Faculty of Medicine, Departments of Internal Medicine and General Surgery*,
Ankara, Turkey

Gazi Medical Journal 7 : 123-127, 1996

SUMMARY : *Patients with advanced cancers of the esophagus or the esophagogastric junction suffer from dysphagia. We report the clinical feasibility of a new kind of self-expanding metal stent (nitinol coil) for the endoscopic treatment of this symptom.*

Key Words : *Stent, Esophageal Carcinoma, Sems.*

INTRODUCTION

The majority of patients with cancers of the esophagus or the esophagogastric junction present with an incurable disease during the diagnosis. (6, 28) Patients with advanced cancers of the esophagus or the esophagogastric junction suffer from dysphagia which causes malnutrition and pain. Because of this, the major goal of therapy is optimal palliation of dysphagia. also, this palliation improves quality of life. Surgery, external beam radiotherapy or laser therapy are all the choices of this palliation, but endoscopic prosthesis placement is an easier and cheaper way for the palliation treatment of malignant esophageal obstruction (4, 5, 28, 29). Prototypes of self-expanding metal prosthesis for the esophagus are in use since 1991 (23).

We report the clinical feasibility of a new kind of self-expanding metal stent (nitinol coil) with respect to the technical success, complications, and reintervention rate.

MATERIALS AND METHODS

Study Design:

This study was prospective and synchronous. Patients with malignant dysphagia due to

esophageal or esophagogastric obstruction admitted to the hospital were considered for inclusion in this study (Fig. 1). All patients gave informed consent following extensive explanation of the risks and the therapeutic alternatives.

Patients:

All patients were considered inoperable by

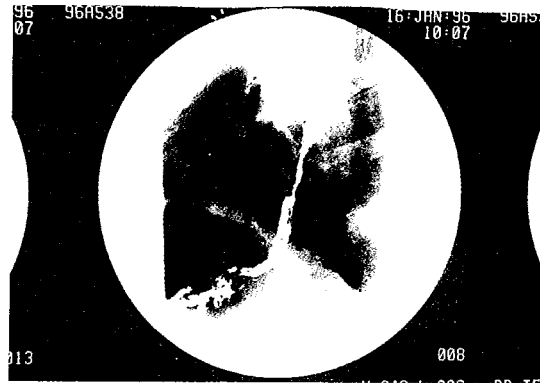


Fig - 1 : Single contrast esophagogram.

surgeons and anesthesiologists because of local tumor extension, distant metastases or severe concomitant disease. The diagnosis was histologically verified in all cases. Details of the 4 patients are shown in table 1. They had adenocarcinoma of the esophagus and all carcinomas localized at esophagogastric junction. The mean age was 52 year . The mean tumor length was 4.5 cm .

Patient Assessment:

Patients were seen on scheduled readmissions or followed up with telephone interviews of monthly intervals. Quality of swallowing was assessed with the aid of a dysphagia score (15) : 0: no dysphagia, 1: dysphagia to normal solids, 2: dysphagia to soft solids, 3: dysphagia to solids and liquids, 4: inability to swallow saliva. Table 1 shows dysphagia index before and after stent

No	Age (Years)	Sex (M:Male, F:Female)	No of Stents	Diagnosis (Histology/Location)	Length of stenosis(cm)	Observation (Weeks)	Dysphagia grade Pre-stent	Dysphagia grade Post-stent
1	46	M	EG 18/8.5	Adeno/Distal	4.5	7 (alive)	3	1
2	39	M	EG 18/8.5	Adeno/Distal	4.5	5 (alive)	3	1
3	51	F	EG 18/8.5	Squamous/Distal	5.0	3 (alive)	3	1
4	72	F	EG 18/8.5	Adeno/Distal	4.0	3 (alive)	3	1

Table 1 : Details of the patients are shown in the table.

Stent Implantation:

Following sedation of the patient with dormicum (Midazolam 10 mg), the length of the stenosis was judged endoscopically and fluoroscopically.(Fig. 2) A guide wire (0.035 inch) was inserted under 7 mm diameter pediatric endoscopic (Olympus UG-FP7) and fluoroscopic control. We used Savary probe (up to 11 mm) for dilating stenotic section in one case. The self-expanding metallic stent (SEMS), constructed from nickel-titanium alloy or "nitinol" (Instent Inc. Eden Prairie, Minn.) was inserted over the guide wire (Fig. 3). An endoscope (Olympus UG-FP7) was inserted additionally and the stent was released under endoscopic and fluoroscopic control (Fig. 4, 5).

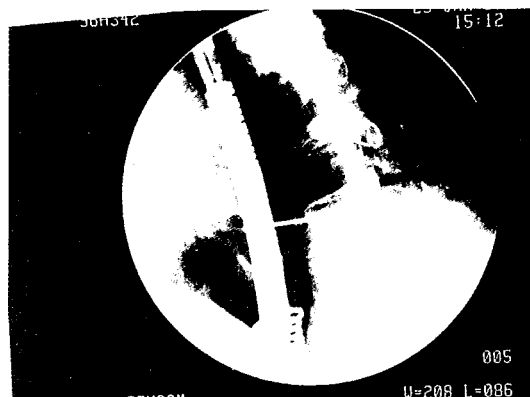

Fig - 3 : Fluoroscopy demonstrating inserted SEMS over the guide wire.

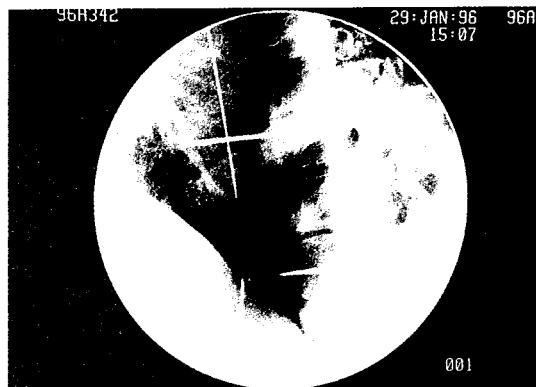

Fig - 2 : Fluoroscopy showing the length of esophageal stenosis.

implantation.

RESULTS

Technical Success :

Technical success, i.e. correct stent placement was achieved in all cases (All stents could easily be passed after placement with a 7 mm endoscope - Olympus UG-FP7-).

Functional Efficacy and Survival :

The functional efficacy is shown in table-1. The mean number of cumulative endoscopic interventions per patient was 3. No treatment complications were noted. There was no mortality or morbidity in the hospital. All patients were able to ingest all necessary calories by mouth, and

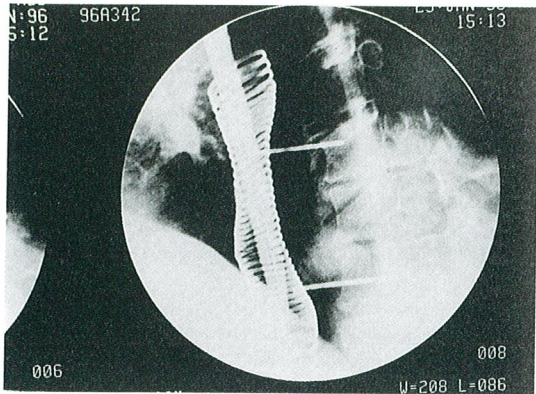


Fig - 4 : SEMS released under endoscopic control.

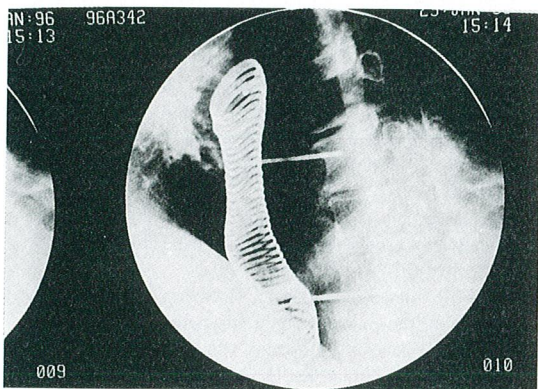


Fig - 5 : SEMS released under fluoroscopic control.

during follow-up period, no prosthesis exhibited tumor ingrowth. During average follow-up of 1 month (range of 1-2 months), no dysphagia was seen in any case (Fig. 6, 7, 8).

DISCUSSION

The diagnosis of malignant esophageal obstruction indicates a discouraging prognosis. Among all treatment modalities, only radical surgery offers a realistic chance of cure. Even after attempted curative resection, the five-year survival rate is only about 5 % (29). Accordingly, non-operative interventions have been elaborated to treat the main symptom dysphagia. Available endoscopic therapy includes dilation with standard Savary- Gillard and balloon dilators, thermocoagulation, injection of alcohol or

chemotherapeutic agents, photodynamic therapy, intra-cavitary irradiation, and Nd-YAG laser treatment (3, 7, 9, 11, 12, 13, 14, 16, 17, 20, 21, 25, 26, 30). The placement of esophageal stents is an appealing method of palliative therapy for this dysphagia. Esophageal stenting has been shown to be a cheaper, faster, and more durable method of

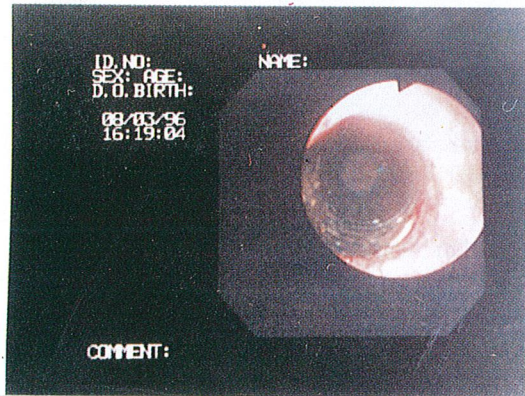


Fig - 6 : Endoscopy revealing the image of the stent one month after the operation.

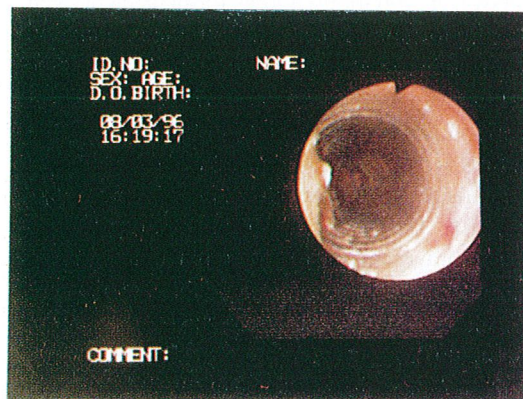


Fig - 7 : Endoscopy revealing the image of the stent one month after the operation.

palliation of malignant dysphagia than other modalities, as reported by Fugger et al (8).

Recently self-expanding metallic stents have been introduced for the treatment of malignant esophageal stenosis (2, 5, 8, 10, 18, 19, 23, 24, 27). The expandable stents available until now have

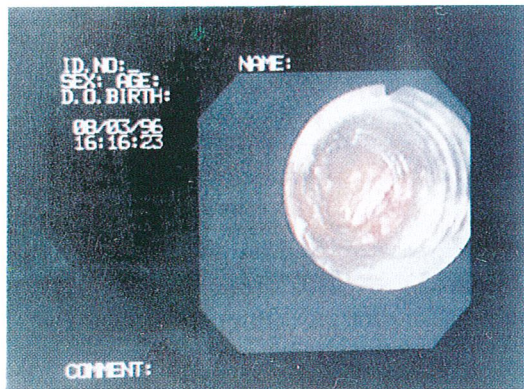


Fig - 8 : Endoscopy revealing the image of the stent one month after the operation.

included the Wallstent (Medinvent S.A., Lausanne, Switzerland) and the Gianturco Z-stent (Wilson-Cook, Winston-Salem, N.C.). We report our experience about a new self expanding stent made of nitinol (Ultraflex, Microvasive, Watertown, Mass). which is an alloy of titanium and nickel that has a firm but flexible consistency once expanded. Advantages of this stent are its small diameter in the compressed state and the large lumen achieved once it is fully expanded. Its surface and edges are smooth, thus preventing mucosal complications. Moreover its flexibility allows for placement even in highly tortuous strictures. Both the granulation and tumor ingrowth can obliterate the lumen of the stent when using other prostheses, but in our experience, this risk is small for nitinol stents. While nitinol is easily removable, expandable stents are not removable as tumor growth may occur through the mesh. However, we found a high rate of gastroesophageal reflux after placement of the stent. The placement of expandable stents is not difficult, as confirmed with our experience with this new stent (22).

In summary, it is clear from this limited early experience, that the new nitinol self-expanding stent is easily inserted and better tolerated by the patient, than its plastic counterpart. However, long-term problems such as limitation of stent expansion by tumor rigidity and ingrowth by tumor or normal epithelium, remain to be addressed.

Correspondence to : Dr.Ahmet GÖRGÜL
Gazi Üniversitesi Tıp Fakültesi
Gastroenteroloji Anabilim Dalı
Beşevler
06500 ANKARA - TÜRKİYE
Phone : 312 - 214 10 00 / 5813

REFERENCES

1. Axelrad MA, Fleischer DE, Gomes M : Nitinol eril esophageal prosthesis: advantages of removable self-expanding metallic stents. *Gastrointestinal Endoscopy* 1996; 43 : 155-160.
2. Bethge N, Knyrim K, Wagner HJ, Storck E, Pousch J, Kleist DV : Self-expanding metal stents for palliation of malignant esophageal obstruction - a pilot study of eight patients. *Endoscopy* 1992; 24 : 411-415.
3. Borr H, Krosner N, Raouf A, Walker RJ : Prospective randomised trial of laser therapy alone and laser therapy followed by endoscopic intubation for the palliation of malignant dysphagia. *Gut* 1990; 31 : 252-258.
4. Canlon A, Nicolav N, Hommand CA, et al : Retrosternal gastric bypass for inoperable oesophageal cancer : A report of 71 patients. *Annals of Thoracic Surgery* 1983; 36: 396-401.
5. Cwikiel W, Stridbeck H : Esophageal stent placement in malignant disease. *Society of Cardiovascular Inter Ventio-nal Radiology (SCVIR Abstract)* 1993; 4 : 36A.
6. Earlom R, Cunho-Melo JR : Oesophageal squamous cell carcinoma : A critical review of surgery. *Br J Surg* 1980; 67 : 381-390.
7. Fleischer D, Sivak M : Endoscopic Nd-YAG laser therapy as palliation for esophagogastric carcinoma. *Gastroenterology* 1985; 89 : 827-831.
8. Fugger R, Niederle B, Jontsche H, Schiessel R, Schulz P : Endoscopic tube implantation for the palliation of malignant esophageal stenosis. *Endoscopy* 1990; 22 : 101-104.
9. Heier SK, Rothman K, Heier LM, Rosenthal WS : Photodynamic therapy for obstructing esophageal tumors : efficacy, safety, light dosimetry and results of an on-going randomized trial (Abstract). *Gastrointest Endosc* 1991; 37 : A187.
10. Kazarek RA, Ball TJ : Metallic self-expanding stent application in the upper gastrointestinal tract: covcats and concerns. *Gastrointest Endosc* 1992; 38 : 1-6.
11. Lambert R, Souquet JC, Sobben G, et al : Survival in upper digestive neoplasia following photodynamic treatment (Abstract). *Gastrointest Endosc* 1991; 37 : A30.
12. Larzou LA, Grigg D, Atkinson M, et al : A prospective comparison of laser therapy and intubation in endoscopic palliation for malignant dysphagia. *Gastroenterology* 1991; 100 : 1303-1310.
13. Likier HM, Levine JG, Lightdole CJ : Photodynamic therapy for completely obstructing esophageal carcinoma. *Gastrointest Endosc* 1991; 37 : 75-78.
14. Macedo G, Allegro S, Saraiva MN, Saraiva M : Ethanol-induced tumor necrosis (ETN): Simple palliation of malignant dysphagia (Abstract). *Endoscopy* 1992; 24 : 622 A.

15. Mallow ME, Pmkus H : Endoscopic laser therapy for malignancies affecting the esophagus and gastroesophageal junction. *Arch Int Med* 1985; 145 : 1443-1446.
16. Malntyre A, Morris DL, Sloan RL, et al : Palliative therapy of malignant esophageal stricture with the bipolar tumor probe and prosthetic tube. *Gastrointest Endosc* 1989; 35 : 531-535.
17. Marcon NE, Siemens M, Haber GB, Randel G, Kortan P : Palliation of partially obstructing esophageal carcinoma with photodynamic treatment (Abstract). *Gastrointest Endosc* 1993; 39 : 283.
18. Maynor M, Rivero L, Pulido-Duque JM, et al : Palliative treatment of malignant dysphagia with elastolloy esophageal endoprosthesis (Streckert): preliminary results. *Society of Cardiovascular Inter-Ventional Radiology (SCVIR Abstract)* 1993; 4 : 37A.
19. Neuhous H, Hoffmann W, Dittler HJ, Niedermeyer HP, Clossen M : Implantation of self-expanding esophageal metal stents for palliation of malignant dysphagia. *Endoscopy* 1992; 24 : 405-410.
20. Novacek S, Chiese A, Poynard T, et al : Endoscopic Nd-YAG laser therapy as palliative treatment for esophageal and colonic cancer. Parameters affecting long-term outcome. *Dig Dis Sci* 1990; 35 : 294-301.
21. Payne-James JJ, Spiller RC, Misiewicz JJ, Silk DB : Use of ethanol-induced tumor necrosis to palliate dysphagia in patients with esophagogastric cancer. *Gastrointest Endosc* 1990; 36 : 43-46.
22. Rajman I, Wolden D, Kortan D, Haber BG, Fuchs E, Siemens M, Kondel G, Marcon NE : Expandable esophageal stents: initial experience with a new nitinol stent. *Gastrointest Endosc* 1994; 40 (5) : 614-621.
23. Sass NL, Hagenaeller F : First endoscopic implantation of memory metal stents in the esophagus. *European Society of Gastrointestinal Endoscopy (ESGE-Abstract)* . *Endoscopy* 1992; 24 : 622.
24. Schoer J, Koton IM, Ivancev K, Uchida B, Rosch J, Binnoeeller KF : Treatment of malignant esophageal obstruction with silicone-coated metallic self-expanding stents. *Gastrointest Endosc* 1992; 38 : 7-11.
25. Schulze S, Fischerman K : Palliation of esophagogastric neoplasms with Nd-YAG laser treatment. *Scand J Gastroenterology* 1990; 25 : 1024-1027.
26. Sonder R, Hogenmuller F, Sonder C, et al : Laser versus laser plus afterloading with iridium 192 in the palliative treatment of malignant stenosis of the esophagus : a prospective randomized and controlled study. *Gastrointest Endosc* 1991; 37 : 433-439.
27. Song HY, Choi KC, Cho BH, Ahn DS, Kim KS : Esophagogastric neoplasms: palliation with a modified Gianturco stent. *Radiology* 1991; 180 : 349-354.
28. Watson A : Surgery for carcinoma of the esophagus. *Postgraduate Med J* 1988; 64 : 860-864.
29. Weiser HF, Lange R, Feussner H : How can we diagnose the early stage of esophageal cancer ? Diagnosis of early esophageal cancer. *Endoscopy* 1986; 18 (Suppl. 3) : 2-10.
30. Wright RA, O'Connor KW : A pilot study of endoscopic injection chemo/sclerotherapy of esophageal carcinoma. *Gastrointest Endosc* 1990; 36 : 47-48.