

## DEVELOPMENTAL ANOMALIES INDUCED BY L-ARGININE AND ASCORBIC ACID IN CHICK EMBRYO : PRELIMINARY MACROSCOPIC FINDING†

Özlem KARAÇAY, Özlem YAKUT, A. Bilge SİPAHİ,  
Tuncay PEKER\*, M.D., Abdullah EKMEKÇİ\*\*, Ph.D.

Gazi University, Faculty of Medicine, Departments of Students, Anatomy\* and Medical Biology and Genetics\*\*, Ankara, Turkey  
Gazi Medical Journal 1999; 10 : 73-79

### SUMMARY :

**Purpose:** Since free radicals are highly reactive in biological systems, complete protection against free radical reactions is not possible. Generally, the reactions of nitric oxide (NO) might act to protect cells from the cytotoxicity of active oxygen species, but might also act as a cytotoxic compound. Our preliminary results confirm this explanation. **Methods :** The teratogenic effects of L-Arginine, Ascorbic acid and L-Arginine+Ascorbic acid combination were evaluated on incubation day 18 by counting the dead and malformed embryos, and then all the external anomalies were photographed. **Results:** Among all the anomalies observed in the study, the higher incidence were observed in Vit C-given group (57 %) when compared with control group. Interestingly, in the L-Arginine + Vit C-given group the incidence of the anomalies were lower than the other drug-given groups (33 %). In addition to this the highest mortality rate was observed in "L-Arginine + Vit C" (61%), L-Arginine (50 %) and Vit C (44 %) given groups respectively. **Conclusion:** According to the results of the study it could be claimed that NO was effective in cell and tissue differentiation. This effect of NO could clearly be observed in skeletal system.

**Key Words :** Drug Induced Abnormalities, L-Arginine, Ascorbic Acid, Bone and Bones.

### INTRODUCTION

Naturally occurring free radicals typically have an oxygen or nitrogen-based unpaired electron. The unpaired electron acquires a partner by attacking a covalent bond of another molecule. The main biological function of nitric oxide (NO) seems to be the stimulation of the soluble guanylate cyclase to elevate C-GMP (cyclic guanosine monophosphate) (1, 2). NO is synthesized from the amino acid arginine by NO synthase. Once synthesized, NO can migrate to lipid soluble parts

of cells, such as the membranes.

NO is an important paracrine signalling molecule in a variety of cell types. In paracrine signalling, a molecule released by one cell acts on neighboring target cells. This kind of signalling plays a critical role in regulating cell to cell interactions including many interactions between different types of cells that take place during embryonic development (3).

Vitamin C (ascorbic acid) is a water-soluble

† This study has been selected as the best study in the 5th Oncology Student Congress with International participation. Adana, Turkey, April 28-30, 1997.

antioxidant. It can trap free radicals and reactive oxygen molecules that result through the action of the detoxification mechanisms previously described (4). Vit C itself does not seem to be a very strong free radical scavenger or nucleophile. Its action is probably mediated by oxygen derivatives (in-vitro) or some other bio-antimutagens (in-vivo) (5).

We are at the early stages of understanding free radical signal transduction and employing this knowledge for intervention in pathophysiology.

Studies on the developmental anomalies due to free radicals and ascorbic acid were not so numerous. The chemistry of NO and also Vit. C in biological systems is extensive and complex. There has been confusion about the roles of these compounds in different conditions. So the aim of our study was to evaluate the role of exogenous reactive nitrogen species and ascorbic acid in the maldevelopment of chick embryos.

## MATERIALS AND METHODS

**Animals and Experimental Protocol:** The experiments were performed on random-bred white leghorns (obtained from Etlik Veterinary Research Institute) which was routinely used in our laboratory for teratogenicity testing. After 3 days of incubation in the horizontal position at 37°C and 60-70 % humidity, the eggs were selected by candling and eventually, by window technique (6).

After moistening of the blastoderm with a drop of saline, the windows in the egg shells were covered with sterile glass slides on a paraffin frame and the eggs were again stored in the incubator (7). During administration, adherence to sterile technique was case fully practiced (6).

The teratogenic effects of L-Arginine (n=12), Ascorbic acid (n=14) and L-Arginine+Ascorbic acid (n=18) combination were evaluated on incubation day of 18 by counting the dead and malformed embryos.

**Drug Preparation:** In this study, L-Arginine, Ascorbic acid and L-Arginine+Ascorbic acid combination were used for examining the abnormalities of the embryonal skeletal system (Ascorbic acid and L-Arginine were provided from Sigma Chemical Company Ltd.). A fourth group of embryos received distilled water and served as control group.

Ascorbic acid (in crystalline form and kept at room temperature) was dissolved in 0.05 ml sterile distilled water and was administered intraamniotically as a single dose of 1mg at 9:00 am on the 1<sup>st</sup> day of incubation.

L-Arginine (in anhydrous crystalline form and kept at room temperature) was dissolved in sterile distilled water and was administered intraamniotically as a single dose of 1 mg at 9:00 am on the 1<sup>st</sup> day of incubation.

A combination of Ascorbic acid and L-Arginine as individually described above was administered intraamniotically as a single dose at 9:00 am on the 1st day of incubation.

**Teratologic Examination:** During evaluation on day 18 all the external anomalies of embryos examined were detected and photographed.

**Visualization of the embryonal skeletal system anomalies:** Cartilage and bone staining, improved by Minoru Inouye (8) and modified in our laboratory (9,10), was used for the examination.

For the evaluation of the results, the number of dead, malformed and growth retarded embryos were given for every group in Table 1.

**Statistical Analysis:** Statistical Analysis was performed by Chi-square tests and reported as the percent occurrence.

## RESULTS

In this study developmental anomalies due to exogenously given free radicals and vitamin C were examined in chick embryos. The mortality incidence was significantly higher in the experimental group as compared to the control group ( $P>0.05$ ).

Anomaly incidence was higher in the Vit C group when compared with control group (Table 1) ( $P<0.05$ ).

The anomaly types were also evaluated according to the types of given agents (Table 2). In the L-Arginine administered group, anomalies were commonly observed in extremities (25%). Especially extension of hindlimbs and extreme flexion of foot were striking (Fig. 1). After the clearing process, bone bendings were observed in hindlimbs. In addition to this, when double staining was applied to the samples it was seen that bone

Table 1 : Incidence of abnormalities in chick embryos treated with L-Arginine, ascorbic acid and L-Arginine+Ascorbic acid.

Groups	Number of fertilized eggs	Number of dead embryos				Total (%)	With anomaly (%)
		Alive	Early	Late			
Control	18	17	1	0	1(5.5)	1 (5.50)	
10 <sup>-5</sup> M L-arginin	12	6	5	1	6 (50.0)*	3 (25.00)	
mg Vitamin C	14	8	2	4	6 (44.0)*	5 (35.71)*	
10 <sup>-5</sup> M L-arginin + Vit C	18	7	4	7	11 (61.0)*	3 (16.66)	

Table 2 : Anomaly types.

Groups	Number of detected anomalies	Anomalies					Total (%)
		Open abdominal wall (%)	Extremity anomalies (%)	Anophthalmie (%)	Other eye anomalies (%)	Beak anomaly (%)	
Control	-	-	-	-	1	1	2 (11)
10 <sup>-5</sup> M L-arginin	-	3 (25.00)	1 (8.33)	1 (8.33)	1 (8.33)	-	6 (50)
mg Vitamin C	1 (7.14)	1 (7.14)	1 (7.14)	2 (14.25)	2 (14.28)	1 (7.14)	8 (57)
10 <sup>-5</sup> M L-arginin + Vit C	1 (5.50)	2 (11.11)	1 (5.55)	-	1 (5.55)	1 (5.55)	6 (33)

\* P < 0.05 when compared with respective control group.

diaphyses were not stained red by Alizarin red-S, which emphasizes the lack of development in the L-Arginine group. In the Vit C group only a few extremity anomalies were observed (7.14%). On

the other hand, extremity anomalies were observed in 11.11% of the samples in L-Arginine + Vit C given group (Fig. 2, 3).

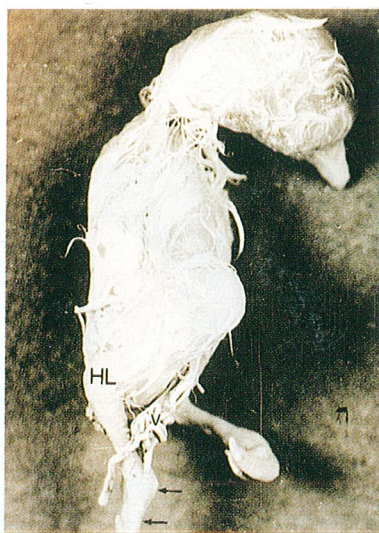


Fig. 1 : L- Arginine given group: Extreme extension of hindlimb. HL : Hindlimb, P: Foot, V: Extra abdominal localization of the viscera, ---> : Extreme extension.

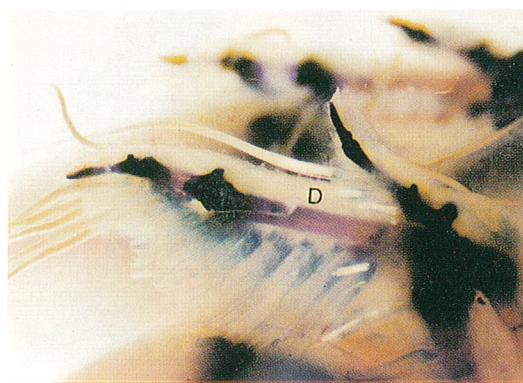


Fig. 2 : Control group: Forelimb of a double stained chick embryo. D: Bone diaphysis. Alizarin red-s and Alcian blue. X 6.7.

Besides the extremity anomalies, some other anomalies were also observed. For instance, the number of anterior abdominal wall defects were the same in Vit C and combination of Vit C and L-Arginin groups (7.14 % and 5.50 % respectively) (Fig. 4, 5), but no such anomalies were present in L-Arginine given group (Table 2).

Anophthalmia was observed in all groups except the control group and no significant differences were observed among the other groups (Fig. 6) (Table 2). Dimensional differences

between the two eyes were also encountered and the most significant differences were observed in Vit C given group (14.25%).

The highest incidence of beak anomalies were also found in the Vit C group (14.28%). Though no beak anomalies were observed, the whole beak was stained red by Alizarin red-S in the control group, in the Vit C group the beak was hypoplastic. There was delay in the ossification of the beak as in the extremities. In the Vit C group the beaks were stained blue by Alcian blue, the ossified part stained

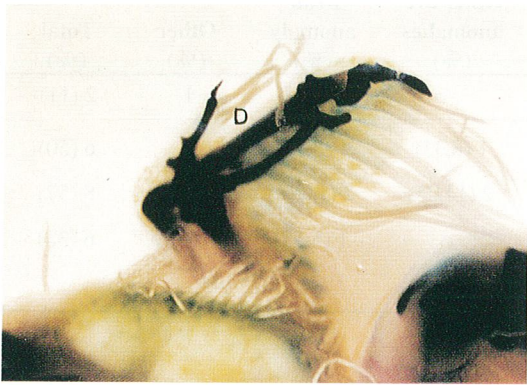

Fig. 3 : L-Arginine given group: Forelimb of a double stained chick embryo. **D**: Bone diaphysis. Alizarin red-s and Alcian blue. X 6.7.

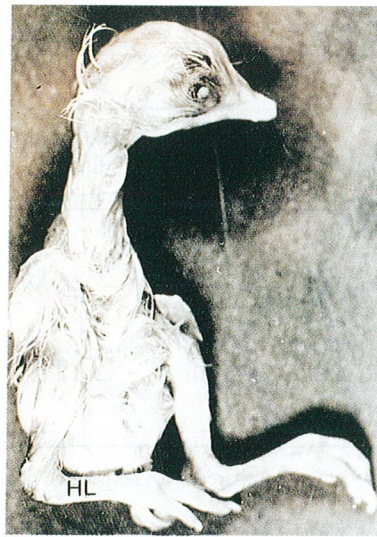

Fig. 4 : Control group: Morphologically normal chick embryo. **HL**: Hindlimb, **P**: Paws.

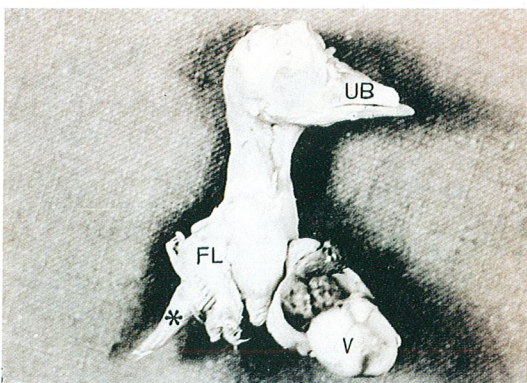


Fig. 5 : Vit C group: Complete absence of hindlimb and extraabdominal localization of the viscera. **V**: Extra abdominal localization of the viscera, **FL**: Forelimb, **UB**: Hypoplastic upper beak, **\***: Abnormal vertebral development.



Fig. 6 : Control and L-Arginine chick embryos: Anophthalmic and extreme extension of hindlimb in L-Arginine given group. **▲**: Anophthalmia, **--->**: Extreme extension.

red by Alizarin red-S was seen only at the tip of the beak (Fig. 7,8).

Vertebral column and pelvic bones were examined by using the double staining method. Vertebral bodies, transverse processes and pelvic bones developed completely (Fig. 9). In the L-Arginine group all the vertebral bodies were joined to each other (vertebral fusion) and anatomical details of the vertebrae could not be observed clearly. The complete absence of hindlimb bones was striking (Fig. 10).

## DISCUSSION

The main purpose of this study is to protect chick embryos by means of Ascorbic acid against the dysmorphogenic effects, which are induced by Nitric Oxide.

In previous studies of teratology certain teratological agents were given to chick embryos and several types of disorders were observed in their developmental processes. The teratological effects of such agents could change due to their

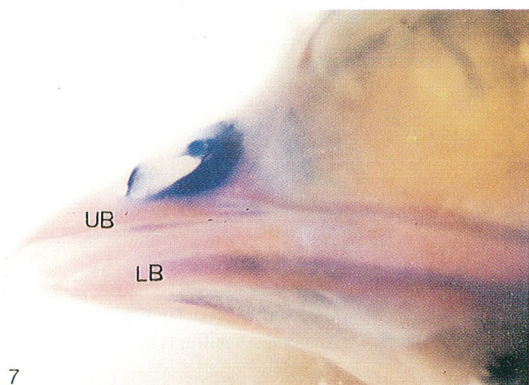


Fig. 7 : Control group: Morphologically normal beak. UB: Upper beak, LB: Lower beak. Alizarin red-s and Alcian blue. X 6.7.

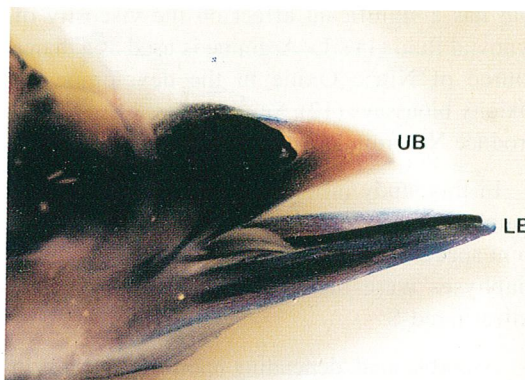


Fig. 8 : L-Arginine + Vit C given group: Hypoplastic beak. UB: Hypoplastic upper beak, LB: Lower beak. Alizarin red-s and Alcian blue. X 6.7.

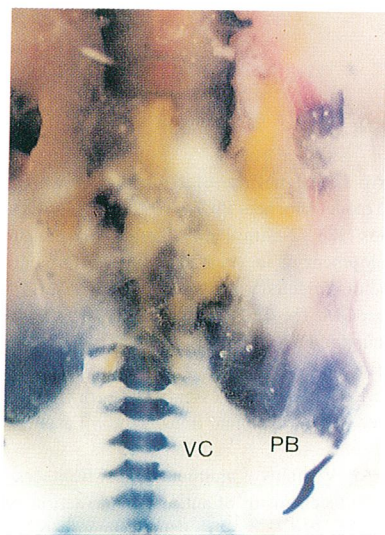


Fig. 9 : Control group: Morphologically normal pelvic bones and vertebral column. VC: Vertebral column, PB: Pelvic bones. Alizarin red-s and Alcian blue. X 6.7.

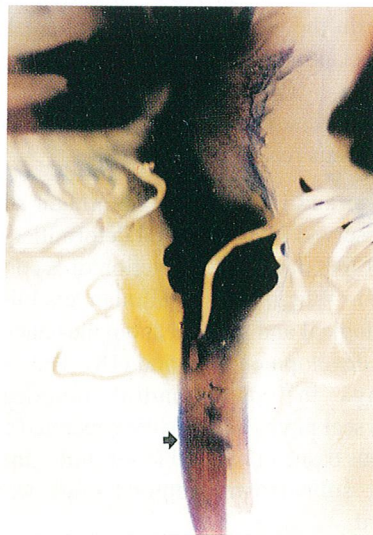

Fig. 10 : L-Arginine given group: Absence of hindlimb and vertebral fusion. ➔: Vertebral fusion and complete absence of hindlimb bones. Alizarin red-s and Alcian blue. X 6.7.

dosage.

Jelinek et al. studied 117 agents that are embryotoxic on chick embryos and reported that only four of these (allylamin, chlorchinolin, methylparation, phenobarbital) were completely embryolethal while the others were embryolethal only in high dosages (6).

In addition the mortality incidence was significantly higher in drug-given group. The highest mortality rate was observed in L-Arginine and Vit C (61%) and then in L-Arginine (50%) and Vit C (44%) given groups respectively.

Free radicals destroy the stability of connective tissue and lessen the viscosity of the synovial fluid affecting hyaluronic acid, a glucosaminoglycan that has a significant effect on the viscosity of synovial fluid (11). L- Arginine is used as a major source of Nitric Oxide in the developmental toxicity bioassays (12). Several types of cells also produce NO from L-Arginine in-vitro (13-15).

In this study, after the clearing process and double staining, bone bendings and narrowing of joint space were observed in hindlimbs and bone diaphyses were observed unstained in red by Alizarin red-S.

Ascorbic acid, depending upon whether it is in the oxidized or reduced state, can function biologically as either a pro-oxidant or oxygen-radical scavenger. Whether it functions as a pro or anti-oxidant in a particular situation will also depend on the concentration and availability of other reactants (15). Our study was also designed to evaluate the embryotoxicity and dysmorphogenesis of ascorbic acid in the presence of exogenous reactive Nitric Oxide.

Mayer and Bengtsson et al. in their studies in 1988 observed some vertebral deformities in some types of fish due to the depletion of ascorbic acid (16, 17). Wegger and Palludan examined the hematological and skeletal anomalies due to Vit C in fetal developmental period (18). They reported swellings in costochondral junctions and epiphyseal plates which were separated from the spongy tissue in ribs and lower limbs. In addition to this, subperiosteal hemorrhagies were also observed.

Among all the anomalies observed in the study the higher incidence was observed in the Vit C-

group when compared with control group (57%). Interestingly, in the L-Arginine + Vit C group the incidence of the anomalies were lower than the other drug-given groups (33 %).

## CONCLUSION

According to the results of the study it could be claimed that NO was effective in cell and tissue differentiation. This effect of NO could clearly be observed in the skeletal system. Although 1mg/ml Vit C could cause significant anomalies when given alone, in the L-Arginine + Vit C group the incidence of anomalies was lower than the other drug-given groups.

Correspondence to : Dr.Tuncay PEKER  
Gazi Üniversitesi Tıp Fakültesi  
Anatomi Anabilim Dalı  
Beşevler  
06500 ANKARA - TÜRKİYE  
Phone : 312 - 214 10 00 / 6976  
Fax : 312 - 212 46 47

## REFERENCES

1. Ignarro LJ. Signal transduction mechanisms involving nitric oxide. *Biochem Pharm* 1991; 41: 485-490.
2. Yeates RA, Schmid M. Total prevention of the Development of in vitro Tolerance to Organic Nitrates *Arzneim.-Forsch./Drug Res* 1992; 42: 297-302.
3. Cooper GM. *The Cell. A Molecular Approach*. ASM press. Washington DC. 1997: 524.
4. Dargan SF, Schatzkin A: Antioxidant micronutrients in cancerLander HM : An essential role for free radicals and derived species in signal transduction. *Faseb J* 1991; 11: 118-126.
5. Odin AP. Vitamins as antimutagens: Advantages and some possible mechanisms of antimutagenic action. *Mutat Res* 1997; 386: 39-67.
6. Jelinek R, Peterka M, Rychter Z. Chick Embryotoxicity Screening Test- 130 Substances Tested. *Indian J Exp Biol* 1985; 23: 588-595.

7. Novotná B, Jelinek R. Mutagenic and Teratogenic Effects of Cyclophosphamide on the Chick Embryo: Chromosomal Aberrations and Cell Proliferation in Affected and Unaffected Tissues. *Teratogen Carcin Mut* 1990; 10: 341-350.
8. Inouye M. Differential staining of cartilage and bone in fetal mouse skeleton by Alcian blue and Alizarin red-S. *Cong Anomalies* 1976; 16: 171-173.
9. Erdođan D, Kadiođlu D, Peker T. Demonstration of Congenital Anomalies in the Joints of the Forelimbs and Hindlimbs Caused by Several Pharmacological Agents. *Anat Histol Embryol* 1996; 25: 263-267.
10. Erdođan D, Peker T, Kadiođlu D. Evaluation of the Skeletal Defects Caused by Caffeine and Sodium Salicylate in Mouse Embryo. *J Neurol Orthop Med Surg* 1996;16: 214-221.
11. Winrow VR, Winyard PG, Morris CJ, Blake DR. Free Radicals in inflammation. Second messengers and mediators of tissue destruction. *Br Med Bull* 1993; 49: 506-522.
12. Leaf CD, Wishnok JS, Hurley JP, Rosenblad WD, Fox JG, Tannenbaum SR. Nitrate biosynthesis in rats, ferrets and humans. Precursor studies with L- arginine. *Carcinogenesis* 1990; 11: 855-858.
13. Palmer RMJ, Ashton DS, Moncada S. Vascular endothelial cells synthesize nitric oxide from L- arginine. *Nature* 1988; 333: 664-666.
14. McCall TB, Boughton-Smith NK, Palmer RMJ, Whittle BJR, Moncada S. Synthesis of nitric oxide from L-arginine by neutrophils. *Biochem J* 1989; 261: 193-296.
15. Knowles RG, Palacios M, Palmer RJM, Moncada S. Formation of nitric oxide from L-arginine in the central nervous system: a transduction mechanisms for stimulation of the soluble guanylate cyclase. *Proc Natl Acad Sci USA* 1989; 86: 5159-5162.
16. Mayer FL, Mehrle PM, Crutcher PL. Interactions of toxaphene and vitamin C in channel catfish. *Trans Amer Fish Soc* 1978; 107: 326-333.
17. Bengtsson BE, Larsson A, Bengtsson A, Renberg L. Sublethal Effects of Tetrachloro-1,2-benzoquinone-A Component in Bleachery Effluents from Pulp Mills- On vertebral Quality and Physiological Parameters in Fourhorn Sculpin. *Exotoxicology and Enviromental Safety* 1988; 15: 62-71.
18. Wegger I, Palludan B. Vitamin C Deficiency Causes Hematological and Skeletal Abnormalities during Fetal Development in Swine. *J Nutr* 1994; 124: 241-248.