

CASE REPORT : INCONTINENTIA PIGMENTI ACROMIANS

Meral BOZKURT, M.D., Melih KORUYUCU, M.D., Burhan AKSAKAL, M.D.,
Kivılcım GÜCÜYENER*, M.D., Ufuk ERGÜN, M.D., M Ali GÜRER, M.D.

Gazi University, Faculty of Medicine, Departments of Dermatology and Pediatrics*,
Ankara, Turkey

Gazi Medical Journal 6 : 147-148, 1995

SUMMARY : *Incontinentia pigmenti acromians, hypomelanosis of Ito is a neurocutaneous disorder of unknown etiology. The disorder is characterized by hypopigmented, bizarre, irregular shaped macules on the trunk ad extremities. More than 90 % of patients has other features besides skin lesions. In our case, mild motor and mental retardation, strabismus and scoliosis were found additionally. We report this case to be published as it is a very rare condition.*

Key Words : *Incontinentia Pigmenti Acromians, Hypomelanosis Of Ito, Hypopigmentation, Scoliosis, Mental Retardation, Strabismus.*

INTRODUCTION

Incontinentia pigmenti acromians, hypomelanosis of Ito is a neurocutaneous disorder of unknown etiology. The disorder is characterized by hypopigmented, bizarre, irregular shaped macules on the trunk and extremities. Lesions appear as the negative image of the pigmentary pattern observed with incontinentia pigmenti. But hypomelanosis of Ito differs in the other features and inheritance pattern. Since 1985, this rare disorder were reported in 38 cases.

CASE REPORT

A 16-year-old girl complained of white colored skin lesions without previous history of suppuration, inflammation or desquamation of 10 years duration. During her school years, she complained of forgetfulness, inability of concentration and adaptation. The family history revealed that one of her cousins were mentally retarded. Physical and laboratory examination revealed mild motor and mental

retardation, strabismus and scoliosis that were not so serious that surgical approach were not considered. Her chromosomal analysis were normal and skin biopsy showed no pathological findings including pigment incontinence.

DISCUSSION

Hypomelanosis of Ito occurs 2.5 times as commonly in women as in man. An autosomal dominant inheritance pattern is being argued (1, 4, 5, 7). The hypomelanotic macules are usually present at birth. The hypopigmented macules may progress or regress itself (4). These macules occurs along Blaschko lines along which linear nevoid anomalies also occur (4, 7). The lesions mostly occur on trunk and extremities. Chromosomal mosaicism thought in the etiopathogenesis (7). The other theory is random distribution of two clones of cells with different pigment potential with the capability of becoming melanoblasts (4). More than 90 % of patients has other features besides skin lesions. Half

of the patients have mental retardation and/or epilepsy. Strabismus, hypertelorism, speech disorder, ear abnormalities, scoliosis, deafness, atopic dermatitis, teeth abnormalities, insulin dependent diabetes mellitus, guatr and eosinophilia were also reported (2, 3, 4, 6).

In our case characteristic hypopigmented macules has been present since she were five years old (Fig 1). Besides having macular lesions, she also had mental and motor retardation, scoliosis and strabismus. In tissue sample we observed no pigment incontinence. In the regions overlying lesions no sensational or sweating abnormality were found. Incontinentia pigmenti were differentiated by the lack of basal layer degeneration, pigment incontinence and dermal infiltration. Systemic problems were not seen in nevus depigmentosus. Other hypopigmented disorders were excluded by the absence of the progression or regression of macules, by the presence of the systemic involvement such as scoliosis, mental retardation and by the absence of the secondary findings on the lesions like sensational loss sweating disorders induration atrophy.

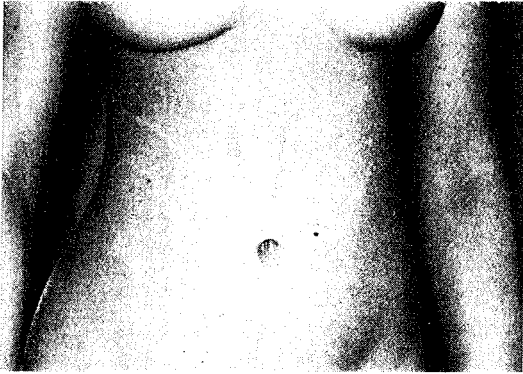


Fig - 1 : Bizarre shaped macules of the patient.

Correspondence to : Dr.Meral BOZKURT
Gazi Üniversitesi Tıp Fakültesi
Dermatoloji Anabilim Dah
Beşevler
06500 ANKARA - TÜRKİYE
Phone : 312 - 214 10 00 / 6104

REFERENCES

1. Amon M, Menapace R, Kimbauer R : Ocular symptomatology in familial hypomelanosis Ito. *Incontinentia pigmenti achromians*. *Ophthalmologica* 1990; 200 (1) : 1-6.
2. Bartholomew DW, et al : Single maxillary central incisor and coloboma in hypomelanosis of Ito. *Clin Genet* 1987; 31 (6) : 370-373.
3. George AO, Adeyanju MO : Incontinentia pigmenti achromians (Ito) in a West African. *East Afr Med J* 1992; 69 (4) : 227-228.
4. Gordon N : Hypomelanosis of Ito (incontinentia pigmenti achromians). *Dev Med Child Neurol* 1994; 36 (3) : 271-274.
5. Kegel MF : Dominant disorders with multiple organ involvement. *Dermatol Clin* 1987; 5 (1) : 205-219.
6. Ong B, Chan HL, Cheah JS : Insulin dependant diabetes and goitre in a case of hypomelanosis of Ito (incontinentia pigmenti achromians). *Ann Acad Med Singapore* 1985; 14 (2) : 317-319.
7. Vormittag W, Ensinger C, Raff M : Cytogenetic and dermatoglyphic findings in a familial case of hypomelanosis of Ito (incontinentia pigmenti achromians). *Clin Genet* 1992; 41 (6) : 309-314.