

## PALPABLE HYDROCELE CALCULOUS : A CASE REPORT (HYDROCELE CALCULOUS)

Mesut ÇETİNKAYA , M.D.,  
Özdemir YILDIZ, M.D.,

Ercüment ULUSOY, M.D.,  
Ekrem GÜNER, M.D.

Öztuğ ADSAN, M.D.,

Ankara Numune Hospital, Department of Urology, Ankara, Turkey  
Gazi Medical Journal 6 : 145-146, 1995

**SUMMARY :** We report a case of two palpable stones, each 5 mm. in diameter and situated in the left tunica vaginalis. The stones were radioopaque on plain film and its x-ray diffraction analysis revealed that it was in dahillite [ $Ca_5(PO_4, CO_3)_3(OH)$ ] form.

**Key Words :** Calculi, Hydrocele, Complication.

### INTRODUCTION

Hydrocele stone is a rarely encountered formation and have little clinical significance. Although definite etiology is unknown, it may rarely occur due to obstruction in the genital lymphatics (6). Hydrocele stone was first described by Kickham in 1935 (5).

In this paper, we report a case of hydrocele stones; interestingly the stones were radioopaque and in dahillite form.

### CASE REPORT

A 50 year-old man presented with two palpable hard mass formation within the left testis, severe pain and swelling in that region of 5 years duration. He defined that he had fallen a renal stone four years ago in his history. Physical examination revealed that there were two palpable, hard stone formation within the tunica vaginalis of the left testis and a slight swelling in the left scrotal contents. Scrotal sonographic evaluation and transillumination revealed left hydrocele and inside the tunica vaginalis two independent, hyperechogenic formations each

of them 5 mm. in diameter (Fig 1). The stones were excessively opaque in the plain film (Fig 2). All the biochemical assays were in normal range preoperatively.

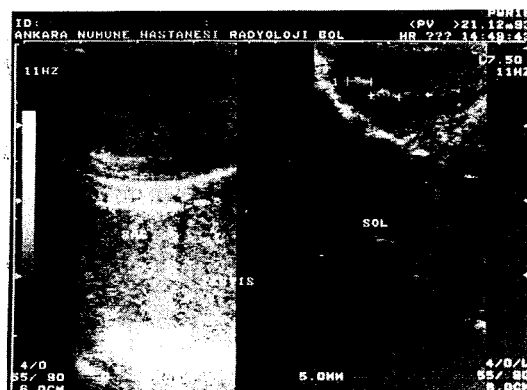


Fig - 1 : The ultrasonographic view of the hydrocele stones.




Fig - 2 : The view of the hydrocele stones on plain film.

The stones were removed with a scrotal incision (Fig 3). Lord's procedure was performed for the therapy of the hydrocele and no complications occurred in the postoperative period. During 6 months follow-up period, the patient had no complaint.

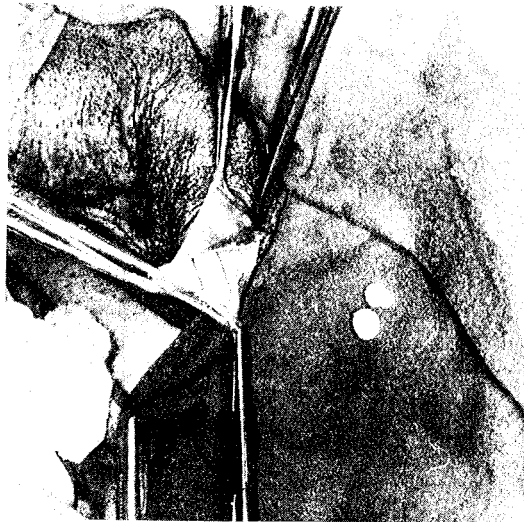


Fig - 3 : The view of the hydrocele stones on operation.

## DISCUSSION

The formation of hydrocele stones is a rare entity and the precise etiology is still unknown. It is suggested that this type of stones generally cause complaints such as pain and swelling due to hydrocele (1, 2, 4). In some reports, these stones were named "hydrocele pearls" (3). In our case it was interesting that two stones were palpable and could be easily seen on the plain film. In this case the amount of hydrocele fluid was minimal and this made it ea-

sier to palpate the stones and we therefore think that there is no correlation between the amount of hydrocele fluid and the formation of stones. The analysis of the stones with x-ray diffraction method revealed the structure of the stones a dahillite form  $[Ca_5(PO_4, CO_3)_3(OH)]$ . To the best of our knowledge, this composition of hydrocele stones has not been reported before.

No correlation has been stated between the hydrocele stones and the renal stone history in the patient.

Correspondence to : Dr.Mesut ÇETINKAYA  
Billur Sok 20/10  
Kavaklıdere  
06700 ANKARA - TÜRKİYE  
Phone : 312 - 467 46 89

## REFERENCES

1. Chatterjee AC : A rare complication of hydrocele. Br J Surg 1975; 61 : 891-892.
2. Efem S : Calculous disease of primary vaginal hydrocele in an infant. Br J Surg 1987; 74 : 72.
3. Farina LA- Vicente R : Scrotal calculi. Eur Urol 1990; 18 : 80.
4. Khanna S, Tieckoo S : Calculous disease in hydrocele. Eur Urol 1989; 16 : 235-236.
5. Kickham CJE : Calcified hydrocele of the tunica vaginalis testis. N Engl J Med 1935; 212 : 419.
6. Smith JH, Von Lichtenberg F, Lehman JS : Parasitic diseases of the genitourinary system; In Campbell's Urology Walsh PC, Retik AB, Stamey TA, Vaughan ED (eds). Sixth ed. Philadelphia, Saunders Co 1992; pp. 883-927.