

## EXOGASTRIC LEIOMYOMA PRESENTING WITH MASSIVE ASCITES

Zafer FERAHKOŞE, M.D., B.Bülent MENTEŞ, M.D., Ekmel TEZEL, M.D., Gülen AYKOL\*, M.D., Ömer ULUOĞLU\*, M.D., Ziya ANADOL, M.D., Ertan TATLICIOĞLU, M.D.

Gazi University, Faculty of Medicine, Departments of Surgery and Pathology\*, Ankara, Turkey  
Gazi Medical Journal 6 : 83-86, 1995

**SUMMARY :** *A case is reported with massive ascites arising from leiomyoma of the stomach. This is an unusual manifestation of the neoplasm which usually presents with ulceration, obstruction or perforation. Ascites formation was ascribed to the abundant vascular structure and the myxoid stroma of the tumor. Projecting extrinsically with a tenous pedicle from its side of origin in the gastric wall, the tumor presented additional diagnostic difficulties. An uncommon example of exogastric leiomyoma is documented with emphasis on its very unusual presentation with ascites.*

**Key Words :** *Gastric, Gastric Leiomyoma, Ascites.*

### INTRODUCTION

Gastric leiomyomas compose approximately 2 % of all gastric tumors and 40 % of all benign tumors of the stomach (7, 29, 30). Because they are usually small in size and asymptomatic, they are often undiagnosed during life (7, 21, 30). Smooth muscle tumors of the stomach generally present with nonspecific symptoms and signs of gastric ulceration, gastric outlet obstruction or perforation (1, 2, 5, 18, 24, 25). Extrinsic growth away from the serosal surface of the stomach may result in interesting, unusual manifestations and diagnostic difficulties.

We observed a case of this relatively uncommon tumor presenting with ascites. Ascites formation has not been described previously in large series reviewing gastric smooth muscle tumors. No other reports have been found in the literature regarding this unusual presentation (3, 10, 24, 28, 31, 32). Preoperative diagnostic difficulties in determi-

ning the origin and the nature of the tumor and a retrospective evaluation regarding the relationship between the histologic features and ascites are considered.

### CASE REPORT

A 58 year old man was admitted to our surgical department for evaluation of the abdominal distension. The patient had been well until about 2 months prior to admission, when a mild, dull pain in the epigastrium and abdominal swelling of gradual onset developed. His stools became more frequent. No other symptoms including haemetemesis and melena were described. He had not received any detailed diagnostic work-up or treatment. Physical examination revealed presence of ascites with bulging flanks dull to percussion, shifting dullness, fluid wave and slight umbilical herniation. A large rounded painless epigastric mass was noted. Paleness of the conjunctivas was the only other positive finding.

Results of routine laboratory evaluations-including liver function tests-were normal except for a low hemoglobin level of 10.6 gr/dl. Endoscopy demonstrated normal gastric mucosa. Barium enema showed a slight downward displacement of the transverse colon with no intrinsic abnormality. Abdominal ultrasonogram confirmed the presence of massive ascites and revealed a large solid mass separate from the liver and pancreas, and without any connection to great abdominal vessels (Fig 1 A, B). A diagnostic paracentesis was performed. The fluid was transudative and cytologic examination showed no abnormality. Computed tomographic scanning of the abdomen did not specify the origin of the solid vascularized tumor, the other abdominal structures being normal. Intravenous pyelogram showed normal findings.

An exploratory laparotomy was carried out fol-



Fig - 1A



Fig - 1B

Fig - 1A, B : Abdominal ultrasonogram confirmed the presence of ascites and revealed a large solid mass of undetermined origin with well defined borders.

lowing transfusion of 2 units of packed red cells. At surgery, about 4 liters of ascites were aspirated. An unencapsulated, fragile dark red mass protruded from the abdominal cavity. It was attached by a thin pedicle to the greater curvature near the antrum (Fig 2). The mass was removed with a 4-5 cm. wedge of the stomach. A liver biopsy was performed. Other abdominal structures were normal.

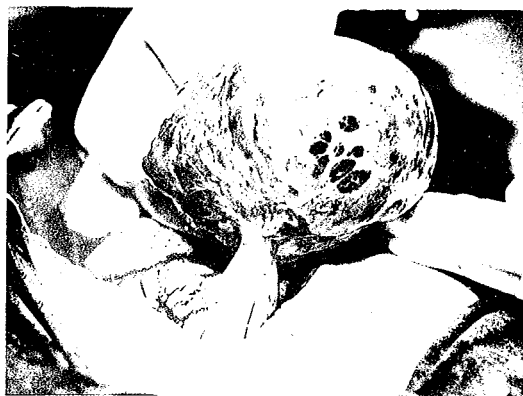

Fig - 2 : Intraoperative view showing the connection of the tumor with the greater gastric curvature.

Gross examination revealed a roundish solid dark red mass, measuring 15x12x8 cm. The cut surface showed small partially empty spaces containing blood clots. On microscopic examination, elongated blunt ended cells arranged in bundles and carrying the well-known characteristics of smooth muscle fibers were admixed with vascular structures with thin irregular walls and surrounded by a framework of reticulum fibers (Fig 3). Some areas of the tumor showed myxoid change in the stroma. A close relationship between the vascular muscular layer and tumor cells was noted. There were evidences of mild pleomorphism, but no necrotic areas or invasion to the adjacent structures. The mitotic count was very low. The final histologic diagnosis was gastric (vascular) leiomyoma. The liver biopsy specimen was normal.

The postoperative course was uneventful. The patient has been well after almost 5 years, free of ascites.

### CONCLUSION

Gastric leiomyomas are relatively uncommon tumors originating from the smooth musculature of the gastric wall including the musculature of the

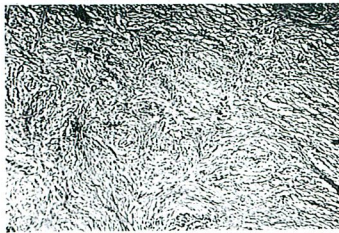
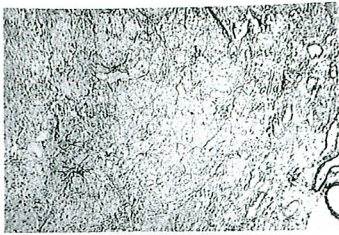

Fig - 3 : Tumor cells arranged in typical bundles are admixed with irregular vascular structures (HE staining, x40) and the abundant stroma shows myxoid changes (HE staining, x80).

gastric blood vessels (25, 30). In a series of 160 cases of gastrointestinal smooth muscle tumors by He et al, leiomyomas were reported to be the most common type, the most frequent site of tumor formation being the stomach, and the more common mode of growth being extraluminal expansion (13). Smooth muscle tumors of the stomach generally present with symptoms and signs of gastric mucosal ulceration, gastric outlet obstruction or perforation (22, 25, 30). Compression of the inferior vena cava with the eventual development of bilateral deep venous thrombosis and a few interesting cases of intraperitoneal hemorrhage secondary to exogastric leiomyoma presenting with spontaneous haemoperitoneum were reported (1, 15, 16, 17, 18, 19, 23, 25, 26, 32, 33). The diagnosis is usually made by gastroscopy, contrast radiology, CT scan and ultrasonography (6, 13, 25, 33).

Anatomic location of the tumor and its position regarding the relation between the muscle wall of the stomach and the main portion of the tumor is variable in different series (4, 13). Tumor extending into the peritoneal cavity as an exogastric formation may cause diagnostic difficulties. Even sophisticated imaging techniques such as ultrasound, CT scan and MRI may not allow physicians to differentiate between the variety of unrelated disorders such as pancreatic, hepatic or mesenteric tumors or cysts or abdominal sarcomas (2, 14, 19). Extrinsicly growing tumors may also form fibrotic capsular attachments to adjacent organs or structures which obscure their origin even more (19). In our patient, neither ultrasound nor CT scan established the origin of the

mass and its exact nature. The lack of the common clinical features of a gastric leiomyoma and unusual presentation with ascites were obviously important confusing and misleading factors considering preoperative diagnosis.

The microscopic appearance is generally typical in smooth muscle tumors although it may occasionally be varied and bizarre, especially when leiomyoblastomas are concerned (4, 27). In our case, the tumor possessed an abundant vascular pattern and a myxoid stroma. An interesting microscopic observation was the relationship between the vascular muscular layer and the tumor cells. It is obviously not possible to be certain that the tumor arised from vascular or mural smooth muscle and whether this might contribute to the rich vascular structure of the tumor in our case. There are similar observations in the literature on the basis of the light microscopy (20). In our opinion, the formation of ascites in this condition was ascribed to the edematous myxoid stroma of the tumor and the eventual interruption of venous return as the tumor enlarged. Partial torsion of the tumor around its thin pedicle might also contribute to ascites formation (8). Torsion of certain pelvic structures, such as large uterine leiomyomas has also been reported to cause ascites (9). The recurrence rate of gastric leiomyomas depend on the extent of resection and the histological features of the tumor, varying from 10 % to 40 % in different series (3, 10, 21). We think that, extrinsicly growing gastric leiomyomas deserve special attention considering unusual presentations, one of which is here reported to be ascites.

**Correspondence to :**

Dr.Zafer FERAHKOŞE  
Gazi Üniversitesi Tıp Fakültesi  
Genel Cerrahi Anabilim Dalı  
Beşevler  
06500 ANKARA - TÜRKİYE  
Phone : 312 - 214 10 00 / 5703

## REFERENCES

1. Abramson DJ : Leiomyoblastomas of stomach. *Surg Gynecol Obstet* 1973; 136 : 118-125.
2. Alpers D, Levitt R, Halverson J, Pikul F : Huge abdominal mass in a 69 year old man. *Am J Med* 1986; 80 (3) : 477-482.
3. Biandrate F, Piccolini M, Francia L, Antonini A : Gastric leiomyoma. Our cases. *Minerva Chirurgica* 1992; 47 (13-14) : 1155-1160.
4. Buswell WA, Powell CD : Stout's bizarre smooth muscle tumor of the stomach. *Br J Surg* 1984; 71 : 430.
5. Butterfield LJH, Casey TP : A bizarre smooth muscle tumor of the stomach. A case report of an unusual cause of swelling of the legs. *Aust NZ J Surg* 1967; 36 : 328-331.
6. Choi BI, Ok ID, Im JG, et al : Exogastric cystic gastric leiomyoblastoma with unusual CT appearance. *Gastrointest Radiol* 1988; 13 : 109-111.
7. Dalaker K, Harket R : Leiomyoblastoma of the stomach. *Acta Chir Scand* 1980; 146 : 141-146.
8. Fukuda O, Munemura M, Tohya T, et al : Massive edema of the ovary associated with hydrothorax and ascites. *Gynecol Oncol* 1984; 17 : 231.
9. Gal D, Buchbaum HJ, Voet R, et al : Massive ascites with uterine leiomyoblastomas and ovarian vein thrombosis. *Am J Obstet Gynecol* 1985; 6 : 89.
10. Gillanders I, Lafferty M, Danesh B : Gastric leiomyoma : An unusual presentation. *Postgraduate Med J* 1992; 68 (795) : 68-69.
11. Golden T, Stout AP : Smooth muscle tumors of gastrointestinal tract and retroperitoneal tissues. *Surg Gynecol Obstet* 1941; 73 : 84-810.
12. Goodman P, Raval B, Bonmati C, Schmidt WA : Leiomyoma involving the gastrocolic ligament : CT demonstration. *Computerized Medical Imaging & Graphics* 1990; 14 (6) : 431-435.
13. He LJ, Wang BS, Chen CC : Smooth muscle tumors of the digestive tract : Report of 160 cases. *Br J Surg* 1988; 5 : 184-186.
14. Holder PD, Field S, Greenhalg AM : Case report : Simple liver cyst masquerading as a gastric leiomyoma-a diagnostic pitfall. *Clinical Radiology* 1993; 48 (4) : 288-289.
15. Iwatt AR, Khalil M, Atthah EB : Gastric epitheloid leiomyoma presenting with spontaneous haemoperitoneum. *Central African J Med* 1990; 36 (8) : 200-202.
16. Kelsey JR : Leiomyoblastomas of the stomach presenting as acute intraperitoneal hemorrhage. *Gastroenterol* 1966; 51 : 539-541.
17. Laky D, Pascu M : An uncommon gastric tumor : Leiomyoma associated with osteochondroma. *Pathology, Research & Practice* 1993; 189 (10) : 1221-1224.
18. Linsay PC, Ordonez N, Raaf GH : Gastric leiomyoblastomas. Clinical and pathological review of fifty patients. *J Surg Oncol* 1981; 18 : 399-421.
19. Malhotra R : A malignant gastric leiomyoblastoma presenting as an infected pseudocyst of the pancreas. *Am J Gastroenterol* 1988; 83 : 452-456.
20. Martin JF, Bazin F, Feroldi J, Cabbane F : Tumors myoides intramurales de l'estomac. *Ann Anat Path* 1960; 5 : 484-497.
21. Morino G, Caponnetto A, Maio P, Scorza V, Fabbrocini P : Leiomyoma of the stomach. A case report of exogastric development. *Minerva Chirurgica* 1992; 47 (10) : 941-944.
22. Nanni G : Unusual presentation of a giant leiomyoblastoma of the stomach. *NY State J Med* 1986; 86 : 316-318.
23. Niemiec S : Coexistence of gastric carcinoid and leiomyosarcoma. *Wiadomosci Lekarskie* 1990; 43 (21-22) : 1083-1086.
24. Ostrovskii VP, Shapriniskii VA, Korsunskii VA : Gastric leiomyoma complicated by repeated bleeding and degenerating into leiomyosarcoma. *Klinicheskaia Khirurgiia* 1990; 5 : 42-43.
25. Phipps RF : Gastric leiomyoma presenting with intraperitoneal hemorrhage. *J Surg Oncol* 1986; 32 : 92.
26. Ramos SM, Mitsudo S : Haemoperitoneum secondary to exogastric leiomyosarcomas and leiomyoblastomas. *Am J Gastroenterol* 1984; 79 : 637-641.
27. Ranchod M : Smooth muscle tumors of the gastrointestinal tract and retroperitoneum. A pathological analysis of 100 cases. *Cancer* 1977; 39 : 255-262.
28. Saccia A, Digirolamo P, Manconi P, D'Agata M : Myxoid tumors of the stomach. Our experiences. *Minerva Chirurgica* 1993; 48 (18) : 993-997.
29. Simitchiev S, Ivanov Z, Bakhariev Z : Epitheloid leiomyoma of the stomach. Its current diagnosis. *Vutreshni Bolesti* 1991; 30 (2) : 111-115.
30. Skandalakis JE, Gray SW, Shephard D : Smooth muscle tumor of the stomach. *Int Abs Surg* 1960; 10 : 209-226.
31. Skandalakis JE, Stephen WG, Bobby CB, Mullins ID : Non-epithelial tumors of the stomach and duodenum In : Nyhus LM, Wastell C (Editors), *Surgery of the stomach and duodenum*. 4th edition. Boston Little Brown and Company 1986; pp. 728-732.
32. Van Hoe L, Bertrand P, Van Wilderode W, Depuyt F : Large polypoid gastric leiomyoma with intermittent duodenal prolapse. *Journal Belge de Radiologie* 1993; 76 (3) : 171-172.
33. Zerbi A, Braga M, Sironi A, et al : An uncommon cause of massive intraperitoneal bleeding. *Tumor* 1988; 74 : 365-367.