

# BASAL CELL CARCINOMA OF THE NOSE WITH CERVICAL LYMPH NODE METASTASIS

## SERVİKAL LENF NODU METASTAZI OLAN BURUN BAZAL HÜCRELİ KARSİNOMU

Ersin ÜLKÜR, M.D., Hüseyin KARAGÖZ, M.D., Şükrü YILDIRIM\*, M.D.,  
Bahattin ÇELİKÖZ, M.D.

Gulhane Military Medical Academy and Medical Faculty Haydarpaşa Training Hospital, Department of Plastic and Reconstructive Surgery and Burn Unit and Pathology\*, Istanbul, Turkey  
Gazi Medical Journal 2004; 15: 153-156

**SUMMARY:** Basal cell carcinoma (BCC) is one of the most common types of cancer, and its natural history is one of local recurrence rather than metastatic spread. Although in patients with metastatic disease the most common location of the primary BCC is the head and neck region, the primary BCC on the nose seems to be less prone to metastasize. The treatment of metastatic BCC of the lymph nodes in the older patient is a challenging problem. We report the treatment of the metastatic BCC of an aged patient with radiotherapy.

**Key Words:** Basal Cell Carcinoma, Nose.

### INTRODUCTION

Basal cell carcinoma (BCC), which is composed of cells arising from the basal cell layer of the epidermis or the lining of the hair follicles or sebaceous glands, is the most common cancer among whites. It mostly occurs in elderly people between the fifth and seventh decades of life. It tends to grow slowly and invade locally over many years. The tumor rarely metastasizes and the estimated incidence of metastasis ranges from 0.003% to 0.55% (1-3). Approximately 230 cases of metastatic disease have been reported worldwide (4,5) and two-thirds of these metastases were seen in the regional lymph nodes.

The treatment of metastatic BCC of the lymph nodes in the older patient whose general status is not suitable for a major operation, such

**ÖZET:** Bazal hücreli karsinoma en sık gözlenen kanser tiplerinden olmakla birlikte daha çok lokal nüks yapma eğilimindedir. Metastatik yayılımı sık gözlenmez. Metastazla birlikte görülen bazal hücreli karsinom vakaları daha çok baş boyun bölgesinde olsa da burun lokalizasyonlu olanlarda daha nadir gözlenmektedir. İleri yaştaki hastalarda lenf noduna metastaz yapmış bazal hücreli karsinomanın tedavisi genel durumu açısından zor olmaktadır. Bu çalışmamızda, burunda bazal hücreli karsinoma tedavisi sonrası servikal lenf nodu metastazı gelişmiş ileri yaştaki bir hastanın radyoterapi ile tedavi ve takibi sunulmaktadır.

**Anahtar Kelimeler:** Basal Hücreli Karsinoma Burun.

as neck dissection, can be a challenging problem. We report the treatment of the metastatic BCC of an aged patient with radiotherapy.

### CASE REPORT

A 72-year-old white female was admitted to our unit with a one-year history of an increasing mass with purulent discharge on the nose. On examination, the mass was 4x4 cm with ulceration (Fig. 1). There was no palpable cervical lymph node bilaterally, and findings on ultrasound of the cervical region were normal at that time. The entire tip, caudal two-thirds dorsum, total left ala, cephalic two-thirds of the right ala, and one-third cephalic septum of the nose were occupied by the lesion according to the computed tomography imaging examination (Fig. 2). There was no sign of metastasis. The patient had received medication for hypertension,

congestive heart failure and deep venous thrombosis. An incisional biopsy was performed and the lesion was histologically diagnosed as a BCC (Fig. 3). Nodular masses of basaloid cells originated from the basal layer of the epidermis extending into the dermis. The characteristic cells of BCC have a large, oval, or elongated nucleus and relatively little cytoplasm.

The patient underwent an en-bloc excision including 5-10 mm of healthy skin

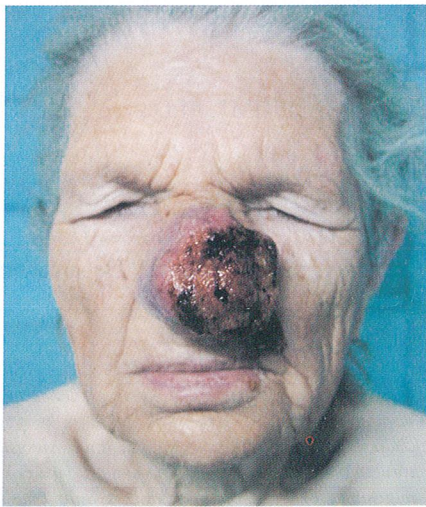

Fig. 1: A 72-year-old female with a 4x4 cm nodular mass with superficial ulceration on the nose.

margins. Nasal reconstruction was performed with a forehead flap. A porous polyethylene stand was used instead of the nasal bone, and mucopericondrium flaps from the septum were used for the inner lining. Although some revisions were suggested to shape the reconstructed nose, the patient did not agree to these. Only the bulky tissue on the rotation point of the forehead flap could be revised (Fig. 4). Six months after the primary lesion, the patient was noted to have right submandibular lymph node

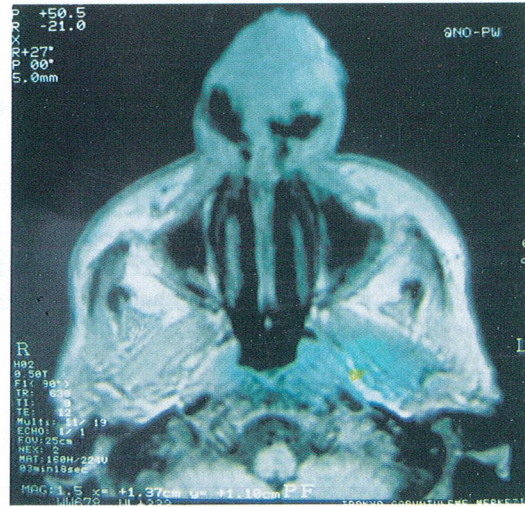


Fig. 2: Computed tomography view showing the mass occupying the entire tip, caudal two-thirds dorsum, total left ala, cephalic two-thirds of the right ala, and one-third cephalic septum of the nose.

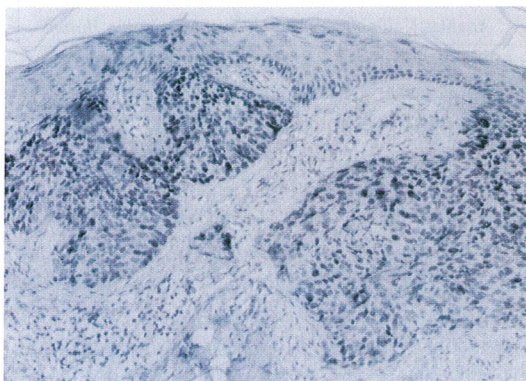


Fig. 3: Nest of malign basal cells attached to the basal cell layer of the epidermis in the incisional biopsy specimen.

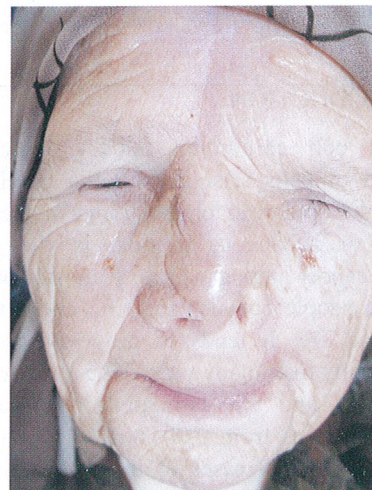

Fig. 4: Nasal reconstruction was achieved with a forehead flap.

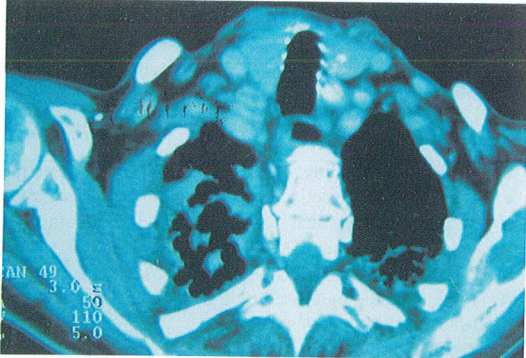


Fig. 5: Computed tomography view showing multiple cervical enlarged lymph nodes.

swelling. A computed tomography scan with contrast medium showed enhancements of the submental and submandibular lymph nodes (Fig. 5). An excisional biopsy of the largest submandibular node was performed. Infiltrating cords of basaloid cells in the lymphoid tissue were seen in the histologic findings, and diagnosed as metastatic BCC (Fig. 6). Since the age of the patient was advanced and her general status did not allow radical neck dissection, radiotherapy was planned. The patient received irradiation to the neck at a total dose of 50 Gy. After a follow-up of 2 years, she showed no signs of recurrence or distant metastasis.

#### DISCUSSION

The criteria for the diagnosis of metastatic BCC were established by Lattes and Kessler in 1951 (6) and Cotran in 1961 (7). They pointed out that 1) the primary tumor must be arising from the skin and not from the mucous membrane or glandular tissue, 2) both metastases and the primary lesion must have similar pathologic appearances and cannot be squamous cell carcinoma, and 3) metastases must be shown in the lymph nodes or viscera and cannot be a result of direct extension. The diagnosis of metastatic BCC was performed according to these criteria.

BCC rarely metastasizes, unlike squamous cell carcinoma. It is reported that the route of metastasis of BCC can be subdivided into 3 types: lymphatic, hematogenous, and mixed. The

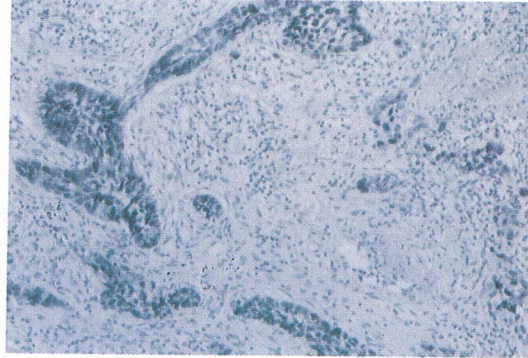


Fig. 6: Nests of BCC show an infiltrative pattern in the reticular dermis.

lymphatic route is reported more frequently than the others (3). The location of the primary BCC is the head and neck region in 85% of patients with metastatic disease. This distribution is similar to that for nonmetastasizing primary BCC (2,3,6,8). There seems to be a slight tendency for tumors of the scalp and ear to metastasize more often, while those of the nose tend to be less prone to metastasize (2,8). Multiple skin recurrences are seen before BCC metastasizes (2). Sometimes patients have more than one primary skin tumor, (2), which may cause confusion as to the origin of the metastatic BCC. Our patient had neither multiple skin recurrences nor multiple primary skin BCCs before the diagnosis of lymph node metastases.

Although the literature on metastatic BCC notes a male predominance with a male to female ratio of 2:1, it is not known whether male sex is a risk factor for metastasis. The median age at onset of the primary tumor is 45 years, and the median age at the first sign of metastasis is reported to be 59 years (2,3). Our patient was 72 years old when the primary tumor was diagnosed, and metastatic disease developed one year later.

It is difficult to determine factors that may predict metastatic BCC. Metastasis may depend on the size of the original tumor and the depth of tumor invasion (9). Snow et al. found that in 850 patients with metastatic BCC, only lesions bigger than 3 cm in diameter metastasized (8). While the overall rate of metastatic BCC was less than 1%,

they quote a 1.9% incidence of metastasis for BCC of this size. The lesion in our patient was 4 cm in diameter with deep invasion. Another criterion for predicting metastasis is duration of the disease. In a review of 170 cases, the median interval between onset of BCC and metastasis was 9 years with a range of less than 1 year to 45 years (2). In our case, the duration between the excision time of the primary tumor and the time of noticing metastatic lymph nodes was 6 months. Since the risk factors (large size, long duration, and deep invasion) were seen in this patient, we planned postoperative control appointments as often as every month in the first six months. In this way the treatment of the metastatic lymph nodes could begin early.

The treatment of metastatic BCC of the lymph node is radical excision and radiotherapy. Radical or modified neck dissection is a major operation and affects the general status of the patient. Radiotherapy can be a single choice of treatment in older patients if the lesion is not fixed to the bone (10). In our case, radiotherapy was used solely due to the advanced age and non-stable general status of the patient.

#### CONCLUSION

We have presented a case of metastatic basal cell carcinoma of the cervical lymph nodes treated with radiotherapy. For older patients whose general status does not allow a major operation, radiotherapy can be a choice of treatment. If the patient has risk factors (large size, long duration, and deep invasion), postoperative evaluations for metastasis should be performed carefully.

Correspondence to: Ersin ÜLKÜR, M.D.  
Gülhane Askeri Tıp Akademisi  
Plastik Cerrahi Anabilim Dalı  
İstanbul-TURKEY  
Phone: 216 - 345 02 95  
Fax: 216 - 345 26 56  
E-mail: eulkur@yahoo.com

#### REFERENCES

1. Robinson JK, Dahiya M. Basal cell carcinoma with pulmonary and lymph node metastasis causing death. *Arch Dermatol* 2003; 139: 643-648.
2. Domarus HV, Stevens PJ. Metastatic basal cell carcinoma report of five cases and review of 170 cases in the literature. *J Am Acad Dermatol* 1984; 10: 1048-1060.
3. Lo JS, Snow SN, Reizner GT, Mohs FE, Larson PO, Hruza GJ. Metastatic basal cell carcinoma: report of twelve cases with a review of the literature. *J Am Acad Dermatol* 1991; 24: 715-719.
4. Safai B. Management of skin cancer. Principle and Practice of Oncology. Devita VT Jr, Helman S, Rosenberg SA (eds), Philadelphia, Lippincott-Raven, 5th Ed, 1997; pp 1895-1900.
5. Giri DD, Gupta PK, Hoda RS. Cytologic diagnosis of metastatic basal cell carcinoma: report of a case with immunocytochemical and molecular pathologic considerations. *Acta Cytol* 2000; 44: 232-236.
6. Farmer ER, Helwig EB. Metastatic basal cell carcinoma: a clinicopathologic study of seventeen cases. *Cancer* 1980; 46: 748-757.
7. Cotran RS. Metastasizing basal cell carcinoma. *Cancer* 1961; 14: 1036-1040.
8. Snow SN, Sahl WJ, Lo JS, Mohs FE, Warner T, Dekkinga JA, Feyzi J. Metastatic basal cell carcinoma. *Cancer* 1994; 73: 28-35.
9. Randle HW. Basal cell carcinoma: identification and treatment of the high-risk patient. *Dermatol Surg* 1996; 22: 255-261.
10. Dinehart SM, Jansen GT. Cancer of the skin, Suen JY, Cancer of the Head and Neck, 3rd ed., Philadelphia, Saunders Company, 1981; 147-148.