

# US-GUIDED COMPRESSION REPAIR IN IATROGENIC PSEUDOANEURYSMS

## İATROJENİK PSÖDOANEVRİZMALARIN US KILAVUZLUĞUNDA KOMPRESYON TEDAVİSİ

Hasan YERLİ, M.D.,  
Hakan ÖZDEMİR\*, M.D.,

Cem YÜCEL\*, M.D.,  
Safiye GÜREL\*\*\*, M.D.,

Murat ÖZDEMİR\*\*, M.D.,  
Şule KOŞAR\*, M.D.

Baskent University School of Medicine, Department of Radiology, Ankara, Turkey  
Gazi University School of Medicine, Departments of Radiology\* and Cardiology\*\*, Ankara, Turkey  
İzzet Baysal University School of Medicine, Department of Radiology\*\*\*, Bolu, Turkey  
Gazi Medical Journal 2004; 15: 87-95

### ABSTRACT

**Purpose:** To evaluate the efficacy of ultrasound-guided compression repair in patients with pseudoaneurysms due to extremity artery catheterizations. **Materials and Methods:** Over a one-year period, fifteen patients with fourteen femoral pseudoaneurysms and one brachial pseudoaneurysm, which developed after cardiac catheterizations, were examined with color Doppler imaging. All of the patients were reevaluated with color Doppler imaging within 24 hours of the procedure. **Results:** In the initial attempt, ultrasound-guided compression repair was successful in thirteen (92%) patients. In one patient with brachial pseudoaneurysm, spontaneous thrombosis was demonstrated. Two recurrences were encountered, one and three days after the procedure. Recompression was performed successfully without further problems. Adequate compression could not be achieved in an uncooperative patient. No complications were observed during or after the procedures. **Conclusion:** Ultrasound-guided compression repair is a safe and effective method for the treatment of pseudoaneurysms. To achieve high success rates, good cooperation has to be obtained from the patient. In patients with anticoagulated and multiloculated pseudoaneurysms longer compression periods or recompression after cessation of anticoagulation may improve the success rates.

**Key Words:** Ultrasonography, Aneurysm-False, Femoral artery, Iatrogenic Diseases

### INTRODUCTION

In cases of incomplete healing of the intervention site due to inappropriate or inadequate compression after angiography, a perivascular hematoma called a pseudoaneurysm,

### ÖZET

**Amaç:** Ekstremitte arter kateterizasyonu sonrasında gelişen psödoanevrizma olgularında, ultrasonografi eşliğinde kompresyon tedavisinin etkinliğinin değerlendirilmesi. **Metod:** Bir yıllık dönem içerisinde, kardiyak kateterizasyon sonrasında gelişen ondört psödoanevrizma olgusunda, Fellmeth tarafından tanımlanan teknikle ultrasonografi eşliğinde kompresyon tedavisi uygulandı. Brakial arter psödoanevrizmalı bir olguda spontan tromboz gözlemlendi. Tüm olgular, işlemden 24 saat sonra yeniden renkli Doppler ultrasonografi ile değerlendirildi. **Bulgular:** Olguların onüçünde (% 92), ultrasonografi eşliğinde kompresyon tedavisi ile başarı sağlandı. Bu olgulardan kompresyon sırasında antikoagülan tedavi alan iki tanesinde işlemden bir gün ve üç gün sonra rekürrens saptandı. Bu olgulara, ultrasonografi eşliğinde kompresyon tedavisi tekrarlandı. Kooperasyon sağlanamayan bir olguda ise işlem başarısız oldu. İşlem sırasında ve takip süresince herhangi bir komplikasyon ile karşılaşmadı. **Sonuç:** Ultrasonografi eşliğinde kompresyon tedavisi, psödoanevrizmaların tedavisinde etkin ve güvenli bir yöntemdir. İşlem öncesinde ve sırasında hasta ile iyi kooperasyon kurulması, antikoagülan tedavi alan ve multilobe psödoanevrizmalı olgularda kompresyon süresinin uzun tutulması ya da antikoagülan kesildikten sonra işlemin tekrarlanması, başarı oranını artıran faktörlerdir.

**Anahtar Kelimeler:** Ultrasonografi, Aneurizma-Psödo, Femoral Arter, İatrojenik Hastalıklar

which connects to the arterial lumen via a tract or neck, can be formed (1). This lesion is also called a pulsatile hematoma since it does not contain a fibrous aneurysm wall (2). The rate of pseudoaneurysm formation after femoral artery

catheterization is between 0.05% and 0.55% (3). However, reports in recent years have shown that pseudoaneurysm development is becoming more frequent with increasing numbers of treatment-oriented catheterizations, and the rates are reaching high values, i.e. 0.6-6% (3). The use of wide-scale catheters during treatment-oriented procedures, the application of anticoagulant treatments during and after the procedure and catheterization of the femoral artery and vein together during the same procedure are the factors causing increased pseudoaneurysm development (1-3). Pain, infection development, progressive growth of the lesion, compression neuropathy, venous stasis and rupture are among the potential sequelae of pseudoaneurysms.

In most cases, pseudoaneurysms cannot be distinguished from simple hematomas by physical examination. On gray-scale ultrasonography, a pseudoaneurysm appears as an anechoic mass that expands during the systolic phase, and that has a neck connecting it to the artery from which it originates. On duplex Doppler examination, the blood flow in the collection appears similar to arterial flow (4). The best method for diagnosing pseudoaneurysms is color Doppler ultrasonography (4-7) (Fig. 1). During the systole, antegrade flow into the pseudoaneurysm is seen, and during the diastole there is a retrograde flow since the pressure in the pseudoaneurysm is higher than that in the feeding artery. In essence, color Doppler typically shows vortex-like, revolving flow in the

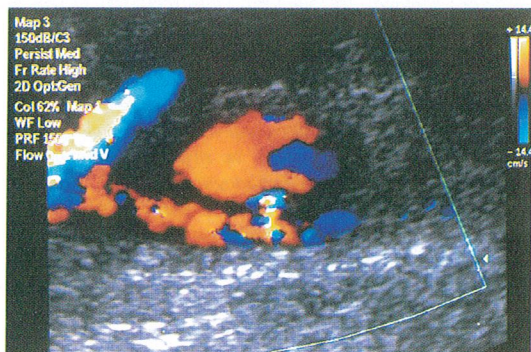


Fig. 1: A pseudoaneurysm originating from the deep femoral artery is seen in the color Doppler examination.

pseudoaneurysm throughout each cardiac cycle. Spectral Doppler examination shows the characteristic back and forth wave form ("to and fro flow") (Fig. 2).

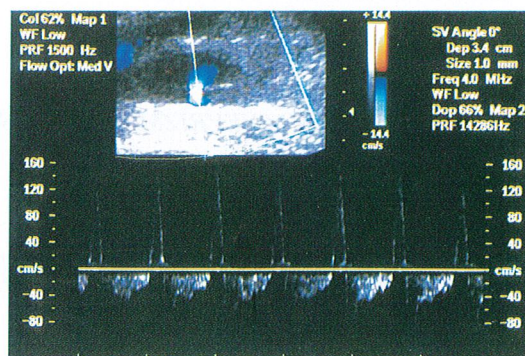


Fig. 2: A back and forward waveform ("to and fro flow") is demonstrated in the pseudoaneurysm neck in the spectral Doppler examination.

The classic treatment for pseudoaneurysm is surgical repair. However, some of these lesions (particularly small ones) can spontaneously thrombose and options such as close follow-up and serial monitoring have been advocated for appropriate cases (8). In 1991, Fellmeth and coworkers introduced ultrasound-guided compression repair (UGCR) as a safe and effective method for treating pseudoaneurysms (9). After that, the results of this method in wide series were reported by several workgroups (3,9-11).

The aim of this research is to determine the efficacy of UGCR in the treatment of pseudoaneurysms and to identify complications associated with this procedure.

## MATERIALS AND METHODS

The patients were 15 individuals who developed a pseudoaneurysm after undergoing diagnostic or treatment-oriented angiography in the angiography unit cardiology department. Eight of the patients were women and 7 were men, and the age range was 23-78 years (mean 59.2 years). Each lesion was detected on color Doppler imaging after the patient developed pain or swelling at the intervention site during follow-

up. All the color Doppler ultrasonography examinations were performed using an ATL HDI 5000 system and transducers with broadband technology, which allowed examination at frequencies of 4-7 MHz and 5-12 MHz. Pseudoaneurysm was diagnosed through the detection of the characteristic back and forth wave form on the spectral Doppler and vortex-like flow on the color Doppler examination (4-7).

Some of the patients had contraindications for UGCR, such as serious ischemia of the extremities, skin ischemia, widespread hematomas, infection, or lesions of the proximal inguinal ligament. After these issues were eliminated, the radiologist and the cardiologist considered all 15 of the patients as good candidates for UGCR. One patient had a pseudoaneurysm of the brachial artery, and this lesion thrombosed spontaneously. The exact location, dimensions, number of lobes, and neck diameter of each pseudoaneurysm were determined before the operation (Table 1). In addition, all patients and their families were informed about the steps involved in the procedure, the expected compression time, the possibility of pain in the inguinal region afterward, and possible complications (thrombosis or distal embolization, in particular).

Before the procedure, six patients received intravenous sedation and three received local anesthesia. Compression was carried out using the technique described by Fellmeth and coworkers (9) (Fig. 3). After establishing the best transducer position for observing the pseudoaneurysm neck, the lesion was

compressed in the transverse plane, keeping the neck in the center of the monitor display. The pressure applied was gradually increased until the flow through the neck was completely stopped. Care was taken to avoid affecting the flow in the nearby arteries (Fig. 4-6). The dorsalis pedis and tibialis posterior pulses were checked every 5 minutes. The pressure was held steady for 10 minutes, and was then decreased slowly and stopped for a short period. Thrombosis development was evaluated during this break. If no thrombus was detected, the transducer was repositioned and another 10-minute session of compression was completed. These steps were repeated until the pseudoaneurysm was totally thrombosed or the patient was unable to tolerate further compression due to pain at the site of application. If the attending radiologist became fatigued during compression, an accompanying radiologist took over.

After UGCR was complete, a strong bandage was applied to the groin and the patient was told to rest for 24 hours. Then a repeat color Doppler examination was carried out. Patients without recurrence underwent clinical follow-up. During follow-up, UGCR-related complications, pseudoaneurysm recurrence, and pain related to the procedure were noted.

For each case, we recorded the reason for the catheterization procedure that led to pseudoaneurysm development, the diameter of arterial cover, the lesion characteristics listed above, administration of anticoagulant or antiaggregant, and the interval from angiography to UGCR.

Table-1: Clinical summary.

Case	1	2	3	4	5	6	7	8	9	10	11	12	13	14	15
Age	23	75	55	55	60	58	55	58	71	69	64	56	52	60	78
Sex	F	F	F	M	F	M	F	M	F	F	M	M	M	F	M
The purpose of catheterization	Diag.	PTCA	Diag.	PTCA	PTCA	Stent	Diag.	PTCA	PTCA	Diag.	Diag.	Diag.	Diag.	Diag.	Diag.
Arterial cover diameter	7F	7F	7F	8F	8F	8F	7F	8F	8F	7F	6F	7F	7F	7F	6F
Anticoagulation in angiography	-	+	-	+	+	+	-	+	+	-	-	-	-	-	-
Antiaggregant treatment	+	+	+	+	+	+	+	+	+	+	+	+	+	+	+
Time between intervention and compression (day)	20	9	18	LO	6	3	8	2	20	1	2	5	6	3	SI
Localization	DFA	SFA	SFA	SFA	SFA	MFA	DFA	SFA	SFA	SFA	DFA	DFA	SFA	MFA	BA
Dimension (cm)	3x2	3x1.5	4x3	5x3	3.5x1.5	4x2	2x1.5	3x2	4x2	3.5x1.2	2x1	3x2	2.5x2	2x2	2.5x1
Lobe number	1	Multilobe	1	1	1	1	1	Multilobe	Multilobe	1	1	1	1	Multilobe	1
Neck diameter (mm)	2	3	2	2	1	2	2	3	4	2	2	3	2	2	2
Anticoagulation in compression	-	+	-	-	-	-	-	+	-	-	-	-	-	-	-
Compression time (minute)	15	30+35	30	27	25	30+30	25	20	40+55	17	20	15	10	18	-
Recurrence	-	+	-	-	-	-	-	-	+	-	-	-	-	-	-
Success	+	+	+	+	+	-	+	+	+	+	+	+	+	+	+

F: Female M: Male PTCA: Percutaneous Transluminal Coronary Angioplasty MFA: Main Femoral Artery  
 Diag: Diagnostic SFA: Superficial Femoral Artery DFA: Deep Femoral Artery BA: Brachial Artery ST: Spontaneous Thrombosis

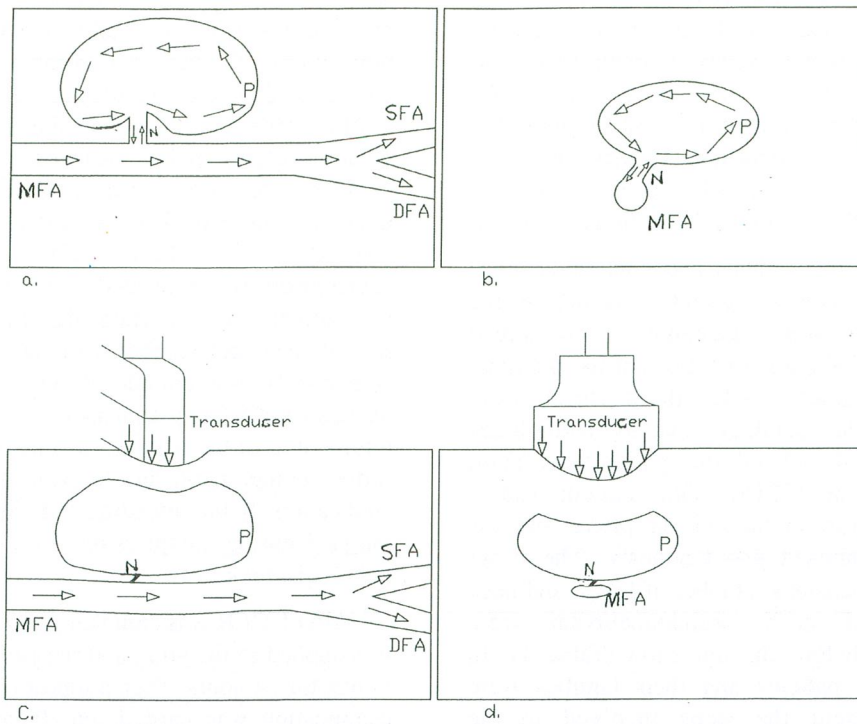


Fig. 3: The demonstration with schema of the treatment of a pseudoaneurysm (P) originating from the main femoral artery (MFA) by UGCR. (a,b) Vortex-like flow is seen inside a pseudoaneurysm originating from the MFA anterior with a narrow neck (N) in the longitudinal and transverse planes. SFA: Superficial femoral artery, DFA: Deep femoral artery. (c,d) The neck of the pseudoaneurysm is strongly compressed with a transducer to prevent flow towards the pseudoaneurysm. Meanwhile, the flow in the femoral artery is maintained. The process is ended when the neck of the pseudoaneurysm is thrombosed.

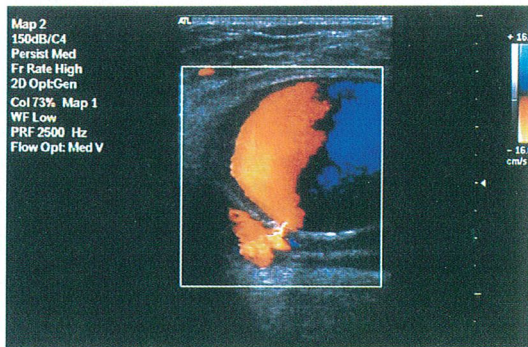


Fig. 4: A pseudoaneurysm originating from the superficial femoral artery is seen in the color Doppler examination.

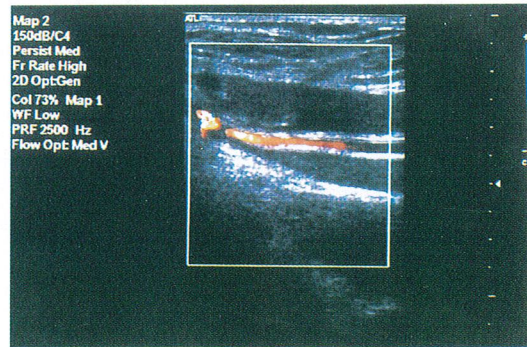


Fig. 5: During the compression, flow in the superficial and deep femoral arteries is protected while the pseudoaneurysm is occluded.

## RESULTS

The purpose of catheterization, arterial cover diameter, the application of antiaggregant or

anticoagulant treatment, time between intervention and compression, compression time, the rates of recurrence and success, and the

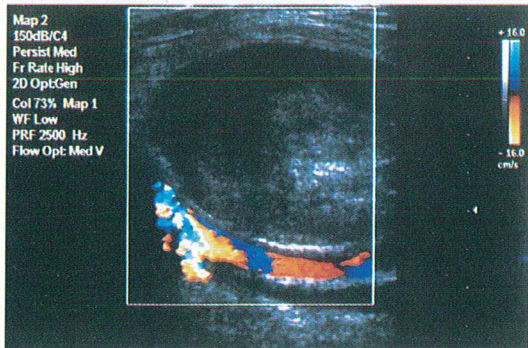


Fig. 6: After the UGCR, it can be seen that the pseudoaneurysm is completely thrombosed in the longitudinal cross-section.

location and lobe numbers of the pseudoaneurysm are shown in Table 1. The pseudoaneurysm developed after diagnostic angiography in 9 cases (60%) and after treatment-oriented intervention (percutaneous transluminal coronary angioplasty or stent placement) in 6 cases (40%). Arterial cover with 6-7F was used in diagnostic procedures, and 7-8F in treatment-oriented interventions. Anticoagulant treatment was administered in all six of the treatment-oriented interventions. In addition, all patients received antiaggregant treatment during both angiography and UGCR.

The time from angiography to UGCR ranged from 1 to 20 days (mean, 8 days). The pseudoaneurysm originated from the main femoral artery in 2 cases (13.3%), the superficial femoral artery in 8 cases (53.3%), the deep femoral artery in 4 cases (26.7%), and the brachial artery in 1 case (6.6%). The smallest lesion measured 2×1 cm, the largest measured 5×3 cm, and the mean dimensions were 3.1×1.8 cm. Eleven (73.3%) of the pseudoaneurysms had only one lobe and 4 (26.7%) were multi-lobed. The neck diameters ranged from 1 to 4 mm (mean, 2.2 mm).

In all cases, blood flow in the nearby arteries was preserved and the pseudoaneurysm was totally obliterated. In 13 patients, including two who were still receiving anticoagulant treatment at that time, the UGCR procedure lasted 15-40 minutes. In one patient who had a multi-lobed

pseudoaneurysm and who was not on anticoagulant therapy at the time of UGCR, control color Doppler ultrasonography at 24 hours showed recurrence of the lesion. After another 55 minutes of compression, the pseudoaneurysm was successfully thrombosed. This case had the longest compression time, 95 minutes in total over the 2 days of treatment. In one of the patients receiving anticoagulant treatment, recurrence was found in the control color Doppler examination 3 days after the compression, and UGCR was applied again 24 hours after continuing the anticoagulant treatment. The pseudoaneurysm was thrombosed again after 35 minutes of compression. This patient showed no further recurrence during follow-up.

One patient had Alzheimer's disease in addition to coronary artery disease. In this case, we attempted two 30-minute UGCR sessions on two consecutive days. However, despite intravenous sedation, the patient continued to move and so it was impossible to achieve the necessary compression. The patient could not cooperate in spite of IV sedation and moved continuously, and so effective and continuous compression could not be accomplished. UGCR was unsuccessful in this case.

All patients defined the level of pain that they could tolerate. None of the patients exhibited altered distal extremity pulses during UGCR or follow-up. The control color Doppler examinations at 24 hours and the repeated color Doppler examinations during follow-up revealed no procedure-related complications.

## DISCUSSION

Pseudoaneurysm is a rare complication developing in extremity artery catheterizations. An increase in its prevalence has been observed in recent years. This is thought to be related to the increase in the number of treatment-oriented catheterizations. Most pseudoaneurysms are seen after cardiac catheterizations. Fellmeth and coworkers reported that 32 (82%) of their 39 patients with pseudoaneurysm or arteriovenous fistula on the intervention site had undergone cardiac catheterizations (9). In a series including 10,589 interventions, the intervention site complication rate was 0.55% after cardiac catheterizations and 0.17% after peripheral or

neuroangiography (12). All the pseudoaneurysms included in our study were observed after cardiac catheterizations.

The risk of pseudoaneurysm development is higher after interventions in arteries other than the main femoral artery (12,13). Only 13.3% of the cases in our series originated from the main femoral artery. This is related to certain factors. Firstly, the main femoral artery is tightly wrapped by neurovascular cover. Secondly, the head femur provides a strong support during the manual compression. Neither factor applies in superficial or deep femoral arteries (14).

The traditional approach is surgical restoration in a short time due to the possible complications (pain, increase in dimensions, rupture etc). Surgical restoration is an effective and safe method but it is expensive and lengthens hospitalization. In addition, it may cause injury, infection, pain or scar tissue, which may cause difficulties during further interventions.

It is known that many lesions can be thrombosed spontaneously. Paulson et al. observed 24 cases in order to determine which had a greater possibility of spontaneous thrombosis (8). Fourteen were spontaneously thrombosed in a day. Ten were not thrombosed and surgical treatment was used. In the first examination, flow volumes in the cases spontaneously thrombosed (mean 1.8 ml) are significantly lower than those in cases operated on (mean 4.4 ml). Meanwhile, the other color Doppler sonography findings (pseudoaneurysm volume, flow percentage in the pseudoaneurysm = flow volume in the total lumen / total division of the pseudoaneurysm x 100%, the rate of back and forth flow speeds in the pseudoaneurysm neck, time of the diastolic flow and neck length) are found to be of no aid in forecasting the possibility of spontaneous thrombosis. In one case in which brachial artery catheterization had been applied, a pseudoaneurysm with a neck 2 mm in diameter was observed to be spontaneously thrombosed.

UGCR is an effective and safe treatment method for pseudoaneurysms developing due to femoral artery interventions. By stopping the blood flow in the neck with compression, the blood in the lesion is thrombosed after a time and the pseudoaneurysm turns into a simple

hematoma. Even though this method takes longer, considering the general anesthesia risk due to cardiac problems in most cases, it must be preferred to surgical treatment. In addition, the possible complications of surgical treatment do not exist in UGCR, and there is always a chance of surgical restoration in cases in which UGCR cannot succeed.

Reported success rates of UGCR are between 57% and 100% (15,16). Coley and coworkers reported a 93% success rate in 117 cases. The success rate of our series is 92%, showing parallelism to other series. The most important factor negatively affecting the success of compression treatment is the existence of anticoagulant treatment. Reported success rates are between 29% and 100% (15,16). The success rate for these cases is 62% in Coley's series. In these cases, it is proposed to increase the 10 minute compression time to 20 minutes, and the total compression time to 2 hours (10). However, applying compression for such a long time does not seem possible in practice since it tires both the patient and the person applying it. A longer compression time also increases the risk of femoral artery thrombosis. For cases in which the only problem is the tiredness of the person applying it, mechanic clamp or compression devices can be used for compression (17,18). In Coley's series, in cases in which UGCR could not succeed due to anticoagulant usage, anticoagulant treatment was continued for a period in some patients with appropriate clinical situations and thrombosis was provided in 75% after repeating UGCR.

The literature shows that dimensions and number of lobes do not affect the success rate but only increase the compression time needed (3). There were 2 multi-lobed pseudoaneurysms in our patients and they were also receiving anticoagulant treatment. Mean compression time was 42.5 minutes in these, while it was 56.5 minutes in two patients with multi-lobed pseudoaneurysms who were not using anticoagulant. All patients with multi-lobed pseudoaneurysms and using anticoagulant were treated successfully by increasing the compression time.

It was thought that longer time intervals between intervention and compression make it more difficult to apply compression because of

epithelizations of the tract and fibrous characteristics developed by the capsule (9,19). However, in Coley's series, in cases older than 21 days and newer than 5 days, success rates were 88% and 89%, respectively (3). In the only unsuccessful outcome in our study the patient had waited for 3 days and the mean time from intervention to UGCR was 8 days.

The time necessary for successful compression varies among series and cases. The shortest time is 8 minutes, and in cases exceeding 60 minutes success possibility seems to decrease and ending the process is proposed (10). Coley et al. reported that in 18% of successful cases compression was applied for longer than 60 minutes. In most of these cases, mechanic compression devices were used. We assume that the reason for achieving thrombosis in 15-40 minutes in all successful cases in our series was the high rate of patients (87%) not using anticoagulant. Meanwhile, we think that the increase in the resolution of the color Doppler ultrasonography systems, giving a better demonstration of the flow in the pseudoaneurysm neck, aids in continuing the compression in the right position.

We think that one of the most important factors affecting the success of compression is the cooperation of the patient before and during the procedure. Before UGCR, the patient must be informed about the procedure. Intravenous sedation and, if necessary, local anesthesia, must be employed. However, the sedation level should not impair the patient's cooperation. Our failure in one case was due to Alzheimer's disease. The success in patients receiving anticoagulant treatment shows the importance of patient cooperation.

UGCR should not be applied in patients who experience extreme pain during the compression, or who have infection at the intervention site, a very large hematoma or critical extremity ischemia. It is also contraindicated in pseudoaneurysms over the inguinal ligament level because of the possibility of uncontrollable hemorrhage that can be retroperitoneal as a result of rupture (9).

The possibility of complications other than pain is very small. Coley reported hypotension disappearing after proper positioning and giving

intravenous liquid in two cases and distal embolization in one case (3). In other series, pseudoaneurysm rupture during the procedure in one case and 1.5 days after the procedure in another has been reported; femoral vein thrombosis in one case and saphenous vein thrombosis in another have also been found (10,20,21). Arteries near the pseudoaneurysm should not be occluded in order to avoid thrombosis and distal embolization. This rule was strictly followed in our cases and no complications, except pain, developed. Even though the complication risk is low, the possibility of urgent surgery should be considered and there should be constant communication with vascular surgeons.

Recently, direct percutaneous embolization using different types of agents such as thrombin and glue [n-butyl cyanoacrylate (NBCA)] accompanied by ultrasonography was defined as a new treatment method and an alternative to UGCR (21-25). Paulson achieved a success rate of 96% with thrombin injection while the success rate in patients who underwent UGCR was 74% in the same series. The most important advantage of this method is the sufficiency of 3-20 seconds duration in cases that needed one injection while 2-5 minutes is necessary in cases requiring more than one injection. It can also be applied to lesions over the inguinal ligament level (22). The only possible risk of the method is the antibody against cattle factor V originating from the cattle thrombin used in the procedure and its cross-reaction with human factor V, causing coagulopathy (26,27). In spite of this theoretic risk, Paulson reported no coagulopathic or thrombotic complications in any of the cases in their series. NBCA, which is a liquid embolic agent, can be polymerized and solidified when in contact with free radicals. NBCA has been rarely used in the treatment of pseudoaneurysms because of the risk of distal embolization when it enters the vascular lumen unless it is not completely polymerized. However, it has been reported that US-guided glue injection in the treatment of femoral artery pseudoaneurysm requires a short duration, and is an effective and easy method (23).

In conclusion, UGCR is still a safe and effective alternative to surgery in pseudoaneurysm treatment. The contradictions of

the procedure (infection at the intervention site, wide hematoma, critical extremity ischemia, lesions over the inguinal ligament level) and its complications (distal embolus, thrombosis, rupture) should be known in detail. All cases must be evaluated by the clinician and there must be necessary preparations for surgery in spite of the low risk. In addition, patients must be well informed and their cooperation should be obtained.

**Correspondence to:** Hasan YERLİ, MD  
Başkent Üniversitesi Tıp Fakültesi  
Radyoloji Anabilim Dalı  
Beşevler  
06490 ANKARA - TÜRKİYE  
Phone: 312 - 223 21 26  
Fax: 312 - 223 73 33  
E-mail: hasanyerli@yahoo.com

#### REFERENCES

- Paulson EK, Kliewer MA, Hertzberg BS, O'Malley CM, Washington R, Carroll BA. Color Doppler sonography of groin complications following femoral artery catheterization. *AJR* 1995; 165: 439-444.
- McCann RL, Schwartz LB, Pieper KS. Vascular complications of cardiac catheterization. *J Vasc Surg* 1991; 14: 375-381.
- Coley BD, Roberts AC, Fellmeth BD, Valji K, Bookstein JJ, Hye RJ. Postangiographic femoral artery pseudoaneurysms: Further experience with US-guided compression repair. *Radiology* 1995; 194: 307-311.
- Abu-Yousef MM, Wiese JA, Shamma AR. The "to and fro" sign: duplex Doppler evidence of femoral artery pseudoaneurysm. *AJR* 1988; 150: 632-634.
- Mitchell DG, Needleman L, Bezzi M, Goldberg BB, Kurtz AB, Pennell RG, Rifkin MD, Vilaro M, Baltarowich OH. Femoral artery pseudoaneurysm: diagnosis with conventional duplex and color Doppler US. *Radiology* 1987; 165: 687-690.
- Sheikh KH, Adams DB, McCann R, Lysterly HK, Sabiston DC, Kisslo J. Utility of Doppler color flow imaging for identification of femoral artery complications of cardiac catheterization. *Am Heart J* 1989; 117: 623-628.
- Igdbashian VN, Mitchell DG, Middleton WD, Schwartz RA, Goldberg BB. Iatrogenic femoral arteriovenous fistula: diagnosis with color Doppler imaging. *Radiology* 1989; 170: 749-752.
- Paulson EK, Hertzberg BS, Paine SS, Carroll BA. Femoral artery pseudoaneurysms: value of color Doppler sonography in predicting which ones will thrombose without treatment. *AJR* 1992; 159: 1077-1081.
- Fellmeth BD, Roberts AC, Bookstein JJ, Freischlag JA, Forsythe JR, Buckner NK, Hye RJ. Postangiographic femoral artery injuries: nonsurgical repair with US-guided compression. *Radiology* 1991; 178: 671-675.
- Paulson EK, Kliewer MA, Hertzberg BS, Tchong JE, McCann RL, Bowie JD. Ultrasonographically guided manual compression of femoral artery injuries. *J Ultrasound Med* 1995; 14: 653-659.
- Cox GS, Young JR, Gray BR, Grubb MW, Hertzner NR. Ultrasound guided compression repair of postcatheterization pseudoaneurysms: results of treatment in one hundred cases. *J Vasc Surg* 1994; 19: 683.
- Rapoport S, Sniderman KW, Morse SS, Proto MH, Ross GR. Pseudoaneurysm: a complication of faulty technique in femoral arterial puncture. *Radiology* 1985; 154: 529-530.
- Lilly MP, Reichman W, Sarazen AA, Carney WI Jr. Anatomic and clinical factors associated with complications of transfemoral arteriography. *Ann Vasc Surg* 1990; 4: 264-269.
- Dorfman GS, Cronan JJ. Postcatheterization femoral artery injuries: is there a role for nonsurgical treatment? *Radiology* 1991; 178: 629-630.
- Feld R, Patton GM, Carabasi RA, Alexander A, Merton D, Needleman L. Treatment of iatrogenic femoral artery injuries with ultrasound guided compression. *J Vasc Surg* 1992; 16: 832.
- Agrawal SK, Pinheiro L, Roubin GS, Hearn JA, Canon AD, Macander PJ, Barnes JL, Dean LS, Nanda NC. Nonsurgical closure of femoral artery pseudoaneurysms complicating cardiac catheterization and percutaneous transluminal coronary angioplasty. *J Am Coll Cardiol* 1992; 20: 610.
- Fellmeth BD, Buckner NK, Ferreira JA, Rooker KT, Parsons DM, Brown PR. Postcatheterization femoral artery injuries: repair with color flow US guidance and clamp assistance. *Radiology* 1992; 182: 570-572.
- Trerotola SO, Savader SJ, Prescott CA, Osterman FA. US-guided pseudoaneurysm repair with a compression device. *Radiology* 1993; 189: 285.
- DiPrete DA, Cronan JJ. Compression ultrasonography: treatment for acute femoral artery pseudoaneurysms in selected cases. *J Ultrasound Med* 1992; 11: 489-492.
- Dol JA, Reekers JA, Kromhout JG. Rupture of pseudoaneurysm during attempted US-guided compression repair. *Radiology* 1992; 185: 284.
- Hilborn M, Downey D. Deep venous thrombosis complicating sonographically guided compression repair of a pseudoaneurysm of the common femoral artery. *AJR* 1993; 161: 1334-1335.
- Paulson EK, Sheafor DH, Kliewer MA, Nelson RC, Eisenberg LB, Sebastian MW, Sketch MH Jr. Treatment of iatrogenic femoral artery pseudoaneurysms: comparison of US-guided thrombin injection with compression repair. *Radiology* 2000; 215: 403-408.
- Aytekin C, Firat A, Gültekin B, Boyvat F, Taşdelen A. US-Guided glue injection in the treatment of femoral pseudoaneurysms. *Tani Girisim Radyol* 2003; 9: 257-259.
- Kruger K, Zahringer M, Sohngen FD, Gossman A, Schulte O, Feldmann C, Strohe D, Lackner K. Femoral pseudoaneurysms: management with percutaneous thrombin injections—success rates and effects on systemic coagulation. *Radiology* 2003; 226: 452-458.



25. Lonn L, Olmarker A, Geterud K, Klingenstierna H, Delle M, Grip L, Risberg B. Treatment of femoral pseudoaneurysms. Percutaneous US-guided thrombin injection versus US-guided compression. *Acta Radiology* 2002; 43: 396-400.
26. Frush DP, Paulson EK, O'Laughlin MP. Successful sonographically guided thrombin injection in an infant with a femoral artery pseudoaneurysm. *AJR* 2000; 175: 485-487.
27. Spotnitz WD. Fibrin sealant in the United States: clinical use at the University of Virginia. *Thromb Haemost* 1995; 74: 482-485.