

## CASE REPORTS

# URETHRAL EROSION AFTER DOUBLE UROLUME URETHRAL STENT INSERTION: A CASE REPORT

## ÇİFT UROLUME ÜRETRAL STENT YERLEŞTİRİLMESİ SONRASINDA ÜRETRAL EROZYON: OLGU SUNUMU

Altuğ Tuncel, M.D., Ali Atan, M.D., Koray Ağras, M.D., Yılmaz Aslan, M.D.

Ministry of Health, Ankara Numune Training and Research Hospital, 3rd Urology Department, Ankara-Turkey  
Gazi Medical Journal 2004; 15: 67-69

*SUMMARY: Multiple urethral stent insertion is usually not preferred in patients with long line urethral stricture disease. In this case report, we describe a serious complication of the intervention.*

*Key Words: Complication, Urethral Stent, Urethral Stricture.*

### INTRODUCTION

The UroLume urethral stent has been advocated for use in men with urethral stricture disease. In recent years, numerous reports have been published regarding the efficacy, safety and success of the device (1-3). Despite these results, different types of complications associated with urethral stent insertion, such as spontaneous breakage, stent migration, recurrent stenosis, and extensive proliferation of hyperplastic tissue within the stent, have been reported in cases of urethral stricture disease (4-7). We report a complication of double UroLume urethral stent insertion.

### CASE REPORT

A 43-year-old man presented with chronic, intermittent penile and perineal pain associated with urinary retention. At first, urethral catheterization was tried with 4 different sizes of urethral catheters (16, 14, 12 and 10 Fr), but none of them could be advanced beyond the first 5 cm of the urethra. One hundred cubic centimeters of

*ÖZET: Genellikle, uzun üretral segmentte darlığı olan hastalarda çok sayıda üretral stent yerleştirilmesi tercih edilmez. Bu olgu sunumunda, bu girişime bağlı ciddi bir komplikasyonu sunuyoruz.*

*Anahtar Kelimeler: Komplikasyon, Üretral Stent, Üretra Darlığı.*

urine was evacuated by suprapubic urine diversion. The patient's history revealed that he had suffered a urethral injury due to a traffic accident and a suprapubic catheter was inserted between January 1999 and April 1999. The patient underwent six direct-vision internal urethrotomies at another medical center between April 1999 and March 2001 but these were of little benefit. Two UroLume urethral stents were inserted through the urethral stricture at the same center in April 2001. His severe unremitting obstructive and irritative voiding symptoms such as difficulty in voiding, decreased urine calibration and projection, weak stream, and nocturia did not alleviate after the intervention. Although his complaints got worse, he did not come for a check-up after the stent insertion.

At his first visit after 2 years, the stents were visualized under the pubic symphysis on a plain pelvic radiograph. The distal urethral stent was not on the same axis as the proximal stent and it had angulated to the right side (Fig. 1). In urethroscopy, the urethrotome could not be

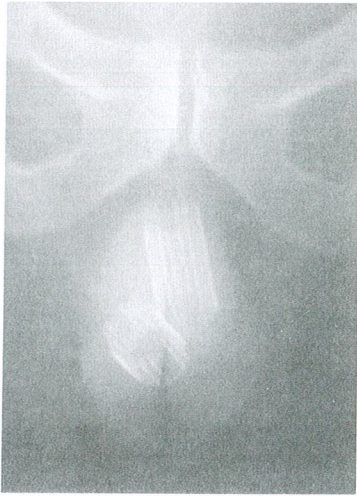

Fig. 1: Two urethral stents in the pelvic radiograph.

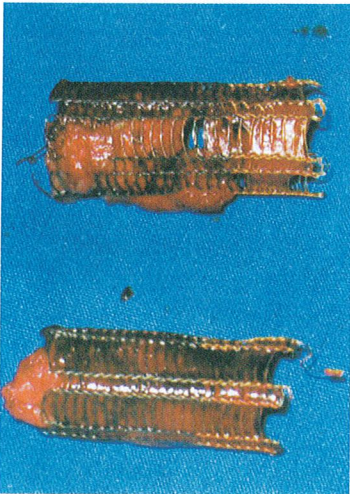


Fig. 2: Two obliterated urethral stents were removed.

advanced more than 5 cm into the urethra because of complete obstruction. Hence, open urethroplasty was planned. Perioperatively, a complete urethral obstruction starting 1 cm from the sphincter and extending nearly 10 cm further was observed. The proximal stent was in the urethra but the distal stent had migrated out of the urethra. The two stents were completely obliterated by extensive hyperplastic proliferative fibrotic tissue and so the stents and obliterated urethral segment were removed (Fig. 2). Urethral reconstruction was performed with the use of a scrotal skin flap. Three weeks later, the urethral catheter was removed. He passed urine spontaneously and was fully continent with no residual urine. The postoperative urethrograph was normal (Fig. 3). The 5th month follow-up

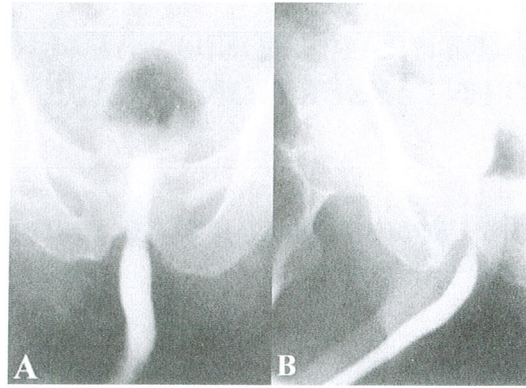


Fig. 3: Postoperative control urethrograph. A- Posteroanterior, B- Oblique views.

was satisfactory.

#### DISCUSSION

The use of urethral stents in urethral stricture disease has become increasingly popular since 1988 (1). Despite their advantages, many urologists have observed UroLume urethral stents to cause complications (4-7). Treatment options for urethral stricture disease include urethral dilation, internal urethrotomy, and urethroplasty. The minimally invasive procedures, dilation and urethrotomy, appear to be equally efficacious as initial treatments for bulbar urethral strictures in 65% and 68% of cases, although the long-term results of the procedures are approximately 50% to 60% (8,9). In a study by Milroy and Allen (5), 50% failure was reported with UroLume stent use in patients with long line and post-traumatic urethral stricture disease. Another study reported that urethral strictures of longer than 2 cm are particularly unsuitable for urethral stent insertion because of intra-stent fibrosis and poor clinical outcomes (6).

In the literature, there are no reports of multi-stent insertion. We think that the UroLume urethral stents had not been used in our patient based on an appropriate indication since he had not received any benefit from any of the procedures. Double stent insertion is not an ideal treatment because of its high complication risk. The use of a UroLume stent to treat urethral stricture disease may lead to postoperative

complications, and a need for repeated procedures. Although the procedure is reportedly reversible, significant and irreversible urethral damage can result. While the UroLume provides an alternative mode of treatment for urethral stricture disease, we recommend careful patient selection and avoidance of multi-stent insertion.

**Correspondence to:** Ali ATAN, M.D.  
Birlik Mah 97. Sokak 13-C/1  
Çankaya  
06610 ANKARA - TÜRKİYE  
Phone: 0532 424 20 82  
Fax: 312 -310 34 60  
E-mail: [aliatanpitt@hotmail.com](mailto:aliatanpitt@hotmail.com)

#### REFERENCES

1. Milroy EJ, Chapple CR, Copper JE, Eldin A, Wallsten H, Seddon AM, Rowles PM. A new treatment for urethral strictures. *Lancet* 1988; 1: 1424-1427.
2. Milroy EJ, Chapple CR, Eldin A, Wallsten H. A new stent for the treatment of urethral strictures. Preliminary report. *Br J Urol* 1989; 63: 392-396.
3. Milroy EJ, Chapple CR, Eldin A, Wallsten H. A new treatment for urethral strictures: a permanently implanted urethral stent. *J Urol* 1989; 141: 1120-1122.
4. Yachia D. Spontaneous breakage of self-retaining intraprostatic stent. *J Urol* 1996; 144: 997-998.
5. Milroy EJ, Allen A. Long-term results of UroLume urethral stent for recurrent urethral strictures. *J Urol* 1996; 155: 904-908.
6. Wilson TS, Lemack GE, Dmochowski RR. Urolume stents learned. *J Urol* 2002; 167: 2477-2480.
7. Baert L, Verhamme L, Van Poppel H, Vandeursen H, Baert J. Long-term consequences of urethral stents. *J Urol* 1993; 150:853-855.
8. Chilton CP, Shah PJ, Fowler CG, Tiptaft RC, Blandy JP. The impact of optical urethrotomy on the management of urethral strictures. *Br J Urol* 1983; 55:705-710.
9. Heyns CF, Steenkamp JW, De Kock ML, Whitaker P. Treatment of male urethral strictures: is repeated dilation or internal urethrotomy useful? *J Urol* 1998; 160:356-358.