

# A CASE OF CEREBRAL HYDATID CYST WITH AN UNUSUAL CT FINDING

## NADİR BT BULGUSUNUN EŞLİK ETTİĞİ BEYİNDE HİDATİK KİST OLGUSU

C. Zuhale ERDEM, M.D., L.Oktay ERDEM, M.D., Deniz AKDUMAN, M.D.,  
Sadi GÜNDOĞDU\*, M.D.

Zonguldak Karaelmas University School of Medicine, Department of Radiology, Zonguldak-Turkey  
Zonguldak Karaelmas University School of Medicine, Department of Infectious Diseases and  
Clinical Microbiology\*, Zonguldak-Turkey  
Gazi Medical Journal 2004; 15: 31-32

**SUMMARY:** Brain involvement in hydatid disease is uncommon and usually seen in children. On computed tomography (CT) scans perifocal edema is not usually present and, when noted, usually reflects an infected cyst. We report an unusual case of an uninfected hydatid cystic lesion with surrounding edema on brain CT.

**Key Words:** Hydatid Cyst Disease, Brain, Computed Tomography.

**ÖZET:** Hidatik kist hastalığında beyin tutulumu yaygın değildir ve sıklıkla çocuklarda gözlenir. Bilgisayarlı tomografi (BT) incelemede perifokal ödemin eşlik etmesi beklenen bir bulgu değildir ve mevcut olması kistin infekte olduğunu gösterir. Biz bu yazımızda, beyin BT incelemede çevresel ödem gösteren ancak infekte olmayan hidatik kist olgumuzu sunduk.

**Anahtar Kelimeler:** Hidatik Kist Hastalığı, Beyin, Bilgisayarlı Tomografi.

### INTRODUCTION

Brain involvement in hydatid disease (HD) occurs in 1 to 2% of all Echinococcus granulosus infections. Some 50 to 75% of intracranial hydatid cysts are seen in children. On CT hydatid cysts typically appear as hypodense lesions with a regular round contour and isodense walls (except when calcified) and perifocal edema is not usually present (1, 2). We report a patient with an unusual brain CT appearance.

### CASE REPORT

A nine-year-old girl was admitted to our hospital with severe headache, vomiting, and abdominal pain. On physical examination hepatomegaly and papilledema in the left optic fundus were detected. Abdominal ultrasonography showed multiple cystic lesions in the liver. Furthermore, brain CT (Fig. 1) showed a large (6x8 cm) cystic lesion with

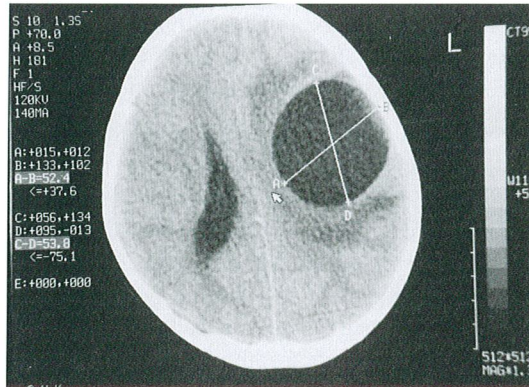


Fig. 1: Plain CT scan showing a 6x8 cm cystic lesion with surrounding edema (arrows) in the left parietal lobe. A midline shift was also detected.

surrounding edema in the left parietal lobe. A mid-line shift was detected. The indirect hemagglutination test was positive. The patient was operated on for the cystic lesion of the brain. The microbiological investigation yielded no organisms after surgical removal. The pathologic examination confirmed the diagnosis of hydatid cyst. The patient was put on an albendazole regimen.

## DISCUSSION

HD is still a problem in Turkey. It is caused by a tapeworm, *Echinococcus granulosus*, which forms larval cysts in human tissue. The disease is endemic in areas where the raising of sheep and cattle is common. Dogs and in some areas foxes are endemic hosts that harbor adult worms in their intestines. Humans acquire the infection by ingesting viable parasite eggs with their food (3).

It has been reported that on brain CT scans, hydatid cysts typically appear as hypodense lesions with a regular round contour and isodense walls (except when calcified) (1). Magnetic resonance imaging (MRI) demonstrates hydatid cysts typically containing fluid with cerebrospinal fluid (CSF) imaging characteristics (4). Another feature of the cerebral hydatid cyst is the low signal intensity of the cyst wall on T2-weighted images (5, 6). Perifocal edema is not usually present and, when noted, usually reflects an infected cyst (2). Degeneration of cysts can also occur without infection as a result of trauma or surgery or rarely may even be spontaneous due to death of the cyst, and can cause unusual CT appearances (7). Our patient did not have a history of prior surgery or trauma, and postoperative microbiological cultures yielded no organisms and so the perifocal edema was attributed to spontaneous degeneration.

Hydatid cysts in the brain generally cause ventricular distortion and midline shift, as in our case. They can be differentiated from brain abscess and cystic astrocytoma by the absence of significant rim enhancement, perifocal edema, and mural nodule (8). We did not perform post-contrast CT. Since our patient had concomitant liver hydatid cyst disease, the cystic lesion in the brain was considered primarily due to HD.

We think that our case is interesting, because brain hydatid cysts are uncommon and cerebral hydatid cysts with perifocal edema are rare. HD

should be kept in mind in the differential diagnosis of cerebral cystic lesions with perifocal edema.

**Correspondence to:** C.Zuhal ERDEM, M.D.  
Zonguldak Karaelmas Üniversitesi  
Tıp Fakültesi  
Radyoloji Anabilim Dalı  
Kozlu  
67600 ZONGULDAK - TÜRKİYE  
Phone: 372 - 261 01 69  
Fax: 372 - 261 01 55  
e-mail: sunarerdem@yahoo.com

## REFERENCES

1. Abbassioun K, Rahmet H, Ameli NO, Tafazoli M. Computerized tomography in hydatid cyst of the brain. *J Neurosurg* 1978; 49: 408-411.
2. Krajewski R, Stelmasiak Z. Cerebral hydatid cysts in children. *Child's Nerv Syst* 1991; 7: 154-155.
3. Schantz PM, Okelo GBA. Echinococcosis (hydatidosis). In: Warren KS, Mahmoud AAF, eds, *Tropical and Geographical Medicine*. 2nd ed. New York: McGraw-Hill, 1990, pp 505.
4. Chang KH, Cho SY, Hesselink JR, et al. Parasitic disease of the central nervous system. *Neuroimaging Clin North Am* 1991; 1: 159-178.
5. Tuzun M, Altinors N, Arda IS, Hekimoglu B. Cerebral hydatid disease CT and MR findings. *Clin Imaging*. 2002 Sep-Oct; 26: 353-357.
6. El-Shamam O, Amer T, El-Atta MA. Magnetic resonance imaging of simple and infected hydatid cysts of the brain. *Magn Reson Imaging*. 2001 Sep; 19: 965-974.
7. Pedrosa I, Saiz A, Arrazola J, Ferreiros J, Pedrosa CS. Hydatid disease: radiologic and pathologic features and complications. *Radiographics* 2000; 20: 795-817
8. Handa J, Nakano Y, Handa J. Computerized tomography in the differential diagnosis of low density intracranial lesions. *Surg Neurol* 1978; 10: 179-185.