

TRADITIONAL TONSILLECTOMY VERSUS RADIOFREQUENCY DISSECTION TONSILLECTOMY IN ADULTS

ERİŞKİNLERDE GELENEKSEL TONSİLLEKTOMİYLE RADYOFREKANS DİSEKSİYON TONSİLLEKTOMİNİN KARŞILAŞTIRILMASI

Metin YILMAZ, M.D.,
Levent Bekir BEDER*, M.D.,

Mehmet Birol UĞUR*, M.D.,
Fikret ÇINAR*, M.D.

Lokman UZUN*, M.D.,

Gazi University Faculty of Medicine, Department of Otorhinolaryngology, Ankara-Turkey
Zonguldak Karaelmas University Faculty of Medicine, Department of Otorhinolaryngology*,
Zonguldak-Turkey
Gazi Medical Journal 2004; 15: 13-17

ABSTRACT

Purpose: To compare traditional dissection tonsillectomy (TRT) with radiofrequency dissection tonsillectomy (RFT) in terms of postoperative pain, intraoperative blood loss, and operation time. **Methods:** Thirty patients underwent elective tonsillectomy under general anesthesia. RFT was performed in 15 and TRT was performed in the remaining. A radiofrequency surgical unit (Surgitron FFPF 140 watt machine, Ellman Corporation, Hewlett New York) equipped with a needle electrode on pure cut and coagulate setting of about '3.5' (17 watts) was used for cold dissection of the tonsils in the RFT group. Postoperative pain was assessed by visual analog scale (VAS). The VAS scores were recorded every hour in the first 24 hours and daily until the 10th day. The operation time was regarded as the period between the first incision and extubation. The amount of blood in the suction container was considered the amount of intraoperative bleeding. **Results:** There was no significant difference between the groups regarding VAS scores, intraoperative bleeding, or operation time ($p>0.05$, c_2 test). **Conclusion:** Both TRT and RFT techniques are safe and similar in terms of postoperative pain, operation time, and intraoperative blood loss. RFT does not have any significant advantage over the traditional technique.

Key Words: Radiofrequency, Tonsillectomy, Postoperative Pain, Morbidity.

ÖZET

Amaç: Amacımız geleneksel diseksiyon tonsillektomi (GLT) ile radyofrekans tonsillektomi (RFT) postoperatif ağrı, operasyon süresi ve operasyondaki kan kaybı miktarı açısından karşılaştırmaktır. **Yöntem:** 15 tanesi RFT, 15 tanesi GLT grubuna ait olmak üzere 30 hastaya genel anestezi altında tonsillektomi yapıldı. '3.5' ayarında (17 watt) saf kesme ve koagülasyon modunda çalışmak üzere ayarlanmış iğne elektrotlu radyofrekans cerrahi ünitesi (Surgitron FFPF 140 watt machine, Ellman Corporation, Hewlett New York) RFT grubunda tonsil soğuk diseksiyonu için kullanıldı. Postoperatif ağrı vizüel analog skalasıyla (VAS) değerlendirildi. VAS skorları ilk 24 saatte saat başı ve onuncu güne kadar günlük olarak kaydedildi. Operasyon süresi ilk kesiden entübasyon kanülünün çıkarılmasına kadar olan süre olarak belirlendi. İntraoperatif kanamayı değerlendirmek üzere aspire edilen kan hacmi ölçüldü. **Bulgular:** VAS skorları, operasyon süresi ve intraoperatif kanama açısından iki grup arasında istatistiksel olarak anlamlı bir fark yoktu ($p>0,05$) ancak VAS skorları GLT grubunda daha iyiydi. RFT grubunda operasyon süresi daha kısaydı ve intraoperatif kanama daha az bulundu. **Sonuç:** Her iki yöntemin de güvenilir olduğu ve postoperatif ağrı, operasyon süresi ve intraoperatif kan kaybı miktarı açısından benzer sonuç verdikleri gözlemlendi. RFT tekniğinin, geleneksel tekniğe göre belirgin avantajlar taşıdığı gözlemlendi.

Anahtar Kelimeler: Radyofrekans, Tonsillektomi, Postoperatif Ağrı, Morbidite.

INTRODUCTION

Tonsillectomy is one of the most common

surgical procedures performed worldwide and so efforts to diminish the associated morbidity are of

great importance. There is still controversy over which is the optimal technique for tonsillectomy with the lowest morbidity rates.

Radiofrequency thermal dissection is an efficient and safe technique with which precise dissection of the tissues is possible (1). With radiofrequency, the molecular bonds of tissue are disintegrated at a low temperature of 60 to 100 C. It has the advantage of minimal thermal damage to the surrounding tissues while simultaneously coagulating blood vessels (1-3).

Our aim was to compare traditional dissection tonsillectomy (TRT) with radiofrequency dissection tonsillectomy (RFT) in terms of postoperative pain, operation time and intraoperative blood loss in subjects scheduled for elective tonsillectomy.

MATERIALS AND METHODS

This prospective and randomized study was conducted between May 2001 and November 2003 in the Department of Otolaryngology, Zonguldak Karaelmas University Hospital, in order to compare the results of RFT and TRT techniques with regard to postoperative pain, operation time, and intraoperative bleeding. Informed consent was obtained from the patients participating in the study, and 30 adult patients (14 male and 16 female, aged 18 to 56 years) were included. The diagnoses were recurrent or chronic tonsillitis, and obstructive tonsillary hypertrophy. The patients did not know which surgical technique had been applied until 10 days postoperatively. The tonsillectomy operations were performed under endotracheal general anesthesia. TRT and RFT were each performed in 15 patients.

On TRT, after an initial incision on the superior pole of the tonsil, dissection was carried out around the tonsillar capsule, and removal of the tonsil was completed using a snare. Hemostasis was achieved using a bipolar diathermy unit.

For RFT, a radiofrequency surgical unit (Surgitron FFPF 140 watt machine, Ellman Corporation, Hewlett New York) equipped with a needle electrode on pure cut and coagulation setting of about '3.5' (17 watts) was used for the dissection of tonsils. The tonsil was grasped with a clamp and retracted medially. The dissection

proceeded in the cut and coagulate mode around the tonsillar capsule. During the dissection, cut mode was paused for 10 seconds every 10 seconds until the end of the operation. Hemostasis was achieved using a bipolar diathermy unit in case of brisk hemorrhage.

A visual analogue scale (VAS) was used to assess postoperative pain. One day before the surgery, the patients were informed about how to use the VAS chart, which was a 100 mm horizontal line marked "no pain" at the left end (1 point) and "worst pain" at the right end (10 points). Each patient rated and recorded his or her pain every hour for ten days.

The time period between the initial incision and extubation was considered operation time. The amount of blood collected in the container of suction was recorded as the amount of intraoperative bleeding.

Patients used acetaminophen (Calpol fi) suspension up to 8x500 mg per day for 14 days. The amount of daily acetaminophen use was recorded on the first, second, fourth, seventh and tenth days. Amoxicillin-clavulanate (Augmentin fi) p.o. twice daily was given for 7 days after the operation. The time period needed for the patients to return to work was also recorded.

A chi-square test was used to compare the results of the RFT and TRT groups. A p-value < 0.05 was considered statistically significant.

RESULTS

All patients completed the VAS and analgesic consumption questionnaires.

There was no significant difference between the groups regarding age, sex or body weight ($p>0.05$) (Table 1).

Although the VAS scores of the patients in the TRT group were slightly higher than those in the RFT group, the difference was not statistically significant ($p>0.05$) (Fig. 1). There was no significant difference between the groups with regard to the use of medicine ($p>0.05$). There was no significant difference between the operating time and intraoperative blood loss in the two groups although the results were in favor of the RFT group (Fig. 2 and 3). The patients in the TRT group returned to work in a mean period of 17 days (range, 13-21 days). This duration was

Table-1: Descriptive data of adults included in the study.

	Tonsillectomy groups		
	TRT (n=15)	RFT (n=15)	p
Age (years)	28.1 ± 7.2	33.6 ± 11.3	n.s ^a
Weight (kg)	66.9 ± 17.9	69.6 ± 15.2	n.s ^a
Gender (male/female)	6/9	8/7	n.s ^a

^aχ² test.

RFT: Radiofrequency tonsillectomy

TRT: Traditional tonsillectomy

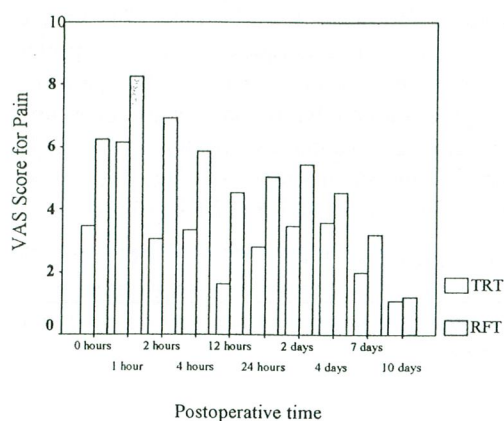


Fig. 1: Visual analog scale scores obtained every hour for the first, second, fourth, seventh and tenth days after elective tonsillectomy with traditional tonsillectomy and radio frequency dissection tonsillectomy. The data represent the mean values of groups.

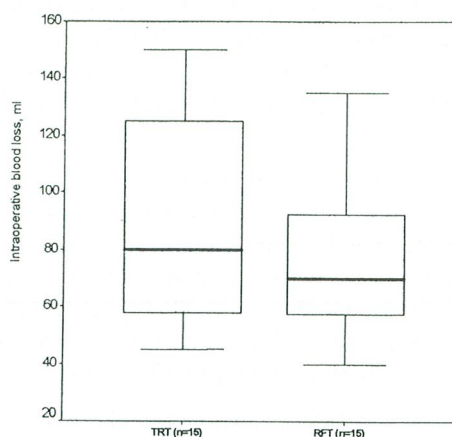


Fig. 3: The operation time in minutes during elective tonsillectomy with radio frequency dissection tonsillectomy (RFT) and traditional tonsillectomy (TRT) presented as a box plot. There was no statistically significant difference between the groups (chi-square test p=0.27). The black line indicates mean values (34.8 min for RFT and 34.9 min for TRT); the shaded boxes, interquartile range (25% and 75% percentiles); and error bars, range.

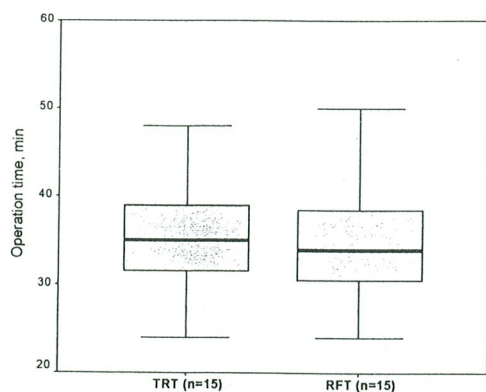


Fig. 2: Intraoperative blood loss during elective tonsillectomy with radio frequency dissection tonsillectomy (RFT) and traditional tonsillectomy (TRT) presented as a box plot. There was no statistically significant difference between the groups (chi-square test p=0.25). The black line indicates mean values (77 ml for RFT and 90 ml for TRT); the shaded boxes, interquartile range (25% and 75% percentiles); and error bars, range.

18 days (range, 12-25 days) in the RFT group (p=0.96).

DISCUSSION

Tonsillectomy is a common operation that can be performed by several different techniques. It is important to reduce morbidity for postoperative patient comfort. Reduction of pain improves oral intake and decreases the risk of dehydration, infection, and postsurgery hemorrhage (2).

The optimal technique for tonsillectomy is a subject of debate. Every technique has its own advantages and disadvantages. Both monopolar and bipolar electrocautery tonsillectomy may reduce the duration of surgery and amount of blood loss when compared with cold dissection, but postoperative pain is increased and the healing process in the tonsillar fossa is slower (4-

7). Similarly, there is significantly less perioperative haemorrhage if tonsillectomy is performed using the KTP laser, but it causes severe postoperative pain, and slower wound healing (8, 9). The ultrasonically activated scalpel (Harmonic scalpel) uses high-frequency ultrasonic energy to perform tissue dissection and coagulation simultaneously. It offers tissue dissection with efficacious intraoperative hemostasis and decreased severity in pharyngeal pain on the day of the operation. (10, 11). On the other hand, slower wound healing and increased pharyngeal pain and otalgia during the second postoperative week are the reported disadvantages compared to the traditional method (10, 12).

Electrosurgical instruments and lasers all achieve cutting and simultaneous hemostasis by sealing the blood vessels' lumina by virtue of heating (2). The extent of diathermy used in tonsillectomy and the resulting degree of soft tissue damage due to heating may be related to the degree of postoperative pain (2, 13, 14).

Monopolar radiofrequency thermal ablation of soft tissues has been studied extensively by specialists in cardiology (15), neurosurgery (16), urology (17), and oncology (18). It has demonstrated acceptable efficacy, safety, and reproducibility of treatment results. A precise controllable lesion characterizes the monopolar radiofrequency method. The coagulation necrosis effect of monopolar radiofrequency energy is effective and safe, and associated with low morbidity in treatments of the soft palate (19), nasal turbinates (20), and tongue base (21).

Our study did not show a statistically significant difference between the VAS scores of the TRT and RFT groups although the pain scores were better in the TRT group. Radiofrequency current applied to the surgical tools is used to generate radio energy, which produces steam within the cells, thus vaporizing them and dividing the tissues. Unlike cautery or diathermy, the needle or loop electrode remains cold, which enables radiofrequency to cause less tissue damage compared to the usual diathermy devices (2, 3, 22). However, the application of bipolar diathermy for hemostasis might result in deeper thermal damage to the surrounding tissue during RFT. Thus, the RFT group received the same thermal injury as the TRT group, at least in

portions of the tonsillar beds, and the possible benefit of RFT was eliminated by the use of cautery. This may be the factor that increased postoperative pain in the RFT group.

Back et al. studied the morbidity and efficacy of bipolar radiofrequency tonsillectomy and compared it with traditional tonsillectomy. They state that bipolar administration of radiofrequency current results in less electricity being leaked to distant tissues than monopolar administration, theoretically decreasing the morbidity following tonsillectomy (2). In the same study both techniques resulted in similar degrees of postoperative pain in the patients, although intraoperative blood loss and operating time were significantly less in TRT. In our study operation time and intraoperative blood loss were similar between the TRT and RFT groups.

In conclusion, both RFT and TRT are safe and were similar in terms of postoperative pain, operation time and the amount of intraoperative bleeding.

Correspondence to: Metin YILMAZ, M.D.
Gazi Üniversitesi Tıp Fakültesi
Kulak Burun Boğaz Anabilim Dalı
Beşevler
06510 ANKARA - TÜRKİYE
Phone: 312 - 202 64 31

REFERENCES

1. Turner RJ, Cohen RA, Voet RL, Stephens SR. Analysis of tissue margins of cone biopsy specimens obtained with cold knife, CO2 and Nd:YAG lasers and radiofrequency surgical unit. *J Repr Med* 1992; 24: 607-610.
2. Back L, Paloheimo M, Ylikoski J. Traditional tonsillectomy compared with bipolar radiofrequency thermal ablation tonsillectomy in adults. *Arch Otolaryngol Head Neck Surg* 2001; 127: 1106-1112.
3. Brown JS. Radiosurgery: a new instrument for minor operations. *Practitioner* 1995; 239: 446-8.
4. Blomgren K, Qvarnberg YH, Valtonen HJ. A prospective study on pros and cons of electrodissection tonsillectomy. *Laryngoscope* 2001; 111: 478-82.
5. Wexler DB. Recovery after tonsillectomy: electrodissection vs. sharp dissection techniques. *Otolaryngol Head Neck Surg* 1996; 114: 576-81.

6. Silveira H, Soares JS, Lima HA. Tonsillectomy: cold dissection versus bipolar electrodissection. *Int J Pediatr Otorhinolaryngol.* 2003; 67: 345-51.
7. Pang YT. Paediatric tonsillectomy: bipolar electrodissection and dissection/snare compared. *J Laryngol Otol* 1995; 109: 733-6.
8. Saito T, Honda N, Saito H. Advantage and disadvantage of KTP-532 laser tonsillectomy compared with conventional method. *Auris Nasus Larynx* 1999; 26: 447-52.
9. Kothari P, Patel S, Brown P, Obara L, O Malley S. A prospective double-blind randomized controlled trial comparing the suitability of KTP laser tonsillectomy with conventional dissection tonsillectomy for day case surgery. *Clin Otolaryngol* 2002; 27: 369-73.
10. Akural EI, Koivunen PT, Teppo H, Alahuhta SM, Lopponen HJ. Post-tonsillectomy pain: a prospective, randomised and double-blinded study to compare an ultrasonically activated scalpel technique with the blunt dissection technique. *Anaesthesia* 2001; 56: 1045-50.
11. Metternich FU, Sagowski C, Wenzel S, Jakel K. Tonsillectomy with the ultrasound activated scalpel. Initial results of technique with Ultracision Harmonic Scalpel. *HNO* 2001; 49: 465-70.
12. Haegner U, Handrock M, Schade H. "Ultrasound tonsillectomy" in comparison with conventional tonsillectomy. *HNO* 2002; 50: 836-43.
13. McAuliffe Curtin J. The history of tonsil and adenoid surgery. *Otolaryngol Clin North Am* 1987; 20: 415-419.
14. Choy ATK, Su AP. Bipolar diathermy or ligation for haemostasis? A prospective study on postoperative pain. *J. Laryngol Otol* 1992; 106: 21-22.
15. Calkins H, Langberg J, Sousa J, el-Atassi R, Leon A, Kou W, Kalbfleisch S, Morady F. Radiofrequency catheter ablation of accessory atrioventricular connections in 250 patients: abbreviated therapeutic approach to Wolff-Parkinson-White syndrome. *Circulation* 1992; 85: 1337-1346.
16. Yoon KB, Wiles JR, Miles JO, Nurmikko TJ. Long-term outcome of percutaneous thermocoagulation for trigeminal neuralgia. *Anaesthesia* 1999; 54: 803-808.
17. Chapple CR, Issa MM, Woo H. Transurethral needle ablation (TUNA). *Eur Urol* 1999; 35: 119-128.
18. Allgaier HP, Delbert P, Zuber I, Olschewski M, Blum HE. Percutaneous radiofrequency interstitial thermal ablation of small hepatocellular carcinoma. *Lancet* 1999; 353: 1676-1677.
19. Powell NB, Riley RW, Troell RJ, Li K, Blumen MB, Guilleminault C. Radiofrequency volumetric tissue reduction of the palate in subjects with sleep disordered breathing. *Chest* 1998; 113: 1163-1174.
20. Utley DS, Goode RL, Hakim I. Radiofrequency energy tissue ablation for treatment of nasal obstruction secondary to turbinate hypertrophy. *Laryngoscope.* 1999; 109: 683-686.
21. Powell NB, Riley RW, Guilleminault C. Radiofrequency tongue base reduction in sleep disordered breathing. *Otolaryngol Head Neck Surg* 1999; 120: 656-664.
22. Bridenstine JB. Use of ultrahigh frequency electrosurgery (radiosurgery) for cosmetic surgical procedures. *Dermatol Surg* 1998; 24: 397-400.