

TECHNICAL NOTE

DIAMOND FLAP ANOPLASTY FOR CICATRICIAL ANAL STENOSIS FOLLOWING FOURNIER'S GANGRENE

B.Bülent MENTEŞ, M.D., Alper CİHAN, M.D., Ertan TATLICIOĞLU, M.D.,
Zafer FERAHKOŞE, M.D.

Gazi University, Faculty of Medicine, Department of General Surgery, Ankara, Turkey
Gazi Medical Journal 1998; 9 : 183-186

SUMMARY : *Cicatricial stenosis of the anal canal is a serious and disabling complication of anal surgery, which may be extremely difficult to manage. In surgical practice, there exists minimal consensus as to the most successful way to surgically manage patients with this condition. Different anoplasties have been described for the management of anal stenosis, such as mucosal advancement anoplasty, S-plasty, V-Y anoplasty, Y-V anoplasty, or diamond-shaped island flap anoplasty, all of which involve local tissue transfer of varying complexity. In this paper, we describe a recent reconstructive approach to an unusual and severe case of anal stenosis following Fournier's Gangrene.*

Key Words : *Anal Stenosis, Surgery, Anoplasty, Flap.*

INTRODUCTION

Anal stenosis, sometimes called anal stricture, is the term applied to an abnormally tight, nonelastic anal opening. The epithelial lining is replaced in parts by fibrous connective tissue. Apart from the cutaneous aspect, there is usually a concomitant underlying sphincter musculature stenotic dimension, contributing to the lack of elasticity necessary for stretch during the passage of a normally formed stool. The patient resorts to increasing quantities and varieties of laxatives. The inelastic scar may occasionally stretch or tear, often causing further formation of scar tissue. Cicatricial stenosis involving the mid-anal canal or dentate line and mucosal ectropion are typically encountered as late sequels of anorectal surgery. Stricture complicates approximately 5% to 10% of radical amputative hemorrhoidectomies and may be observed after other surgical procedures, such as rectal sphincterotomy, fissurectomy, or excision of

mucosal ectropion (1). Other conditions predisposing the patient to anal stenosis include trauma, ileo-pouch-anal anastomosis after total proctocolectomy, inflammatory bowel disease, tuberculosis, lymphogranuloma venereum, radiotherapy, and senile involution (2).

Surgical correction of stenosis aims to recreate normal anal function and anatomy by restoring normal sphincter mechanism and re-establishing the mucocutaneous junction at an appropriate distance from the anal verge. Many techniques have been described for the management of these disorders, most of which utilize an advancement skin flap principle, variably incorporating internal sphincterotomy. (1-10). In this report, we describe the technical details and outcome of a severe case of cicatricial anal stenosis treated by diamond flap anoplasty.

PATIENT AND TECHNIQUE

A 23-year-old male was admitted for complete cicatricial anal stenosis. Three months before admission, he had undergone wide surgical debridement plus laparoscopic sigmoid loop (functional end) colostomy at our department for Fournier's gangrene, following outpatient hemorrhoidectomy in another clinic. The postoperative course was uneventful, and three weeks after this initial procedure, the large perineal defect was covered by split-thickness skin graft. In spite of this early reconstructive intervention, we were faced with complete anal stenosis two months later (Fig. 1).

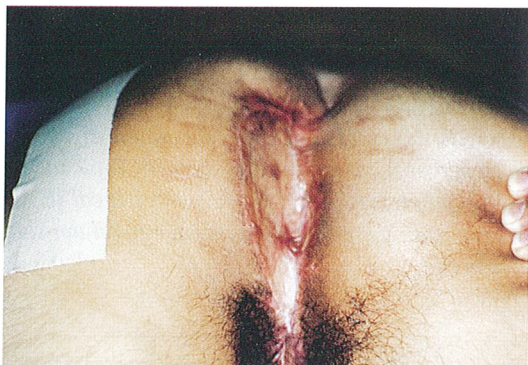

Fig - 1 : In spite of the early surgical intervention of split-thickness skin grafting, complete anal stenosis developed secondary to the extensive inflammation of previous Fournier's gangrene.

At operation, we initially hoped to find a thin membranous covering that we could easily manage. On the contrary, the anus was covered by thick scar tissue. A circular tissue excision was made and deepened towards the anal canal, so as to correspond to the anal verge at the end of the procedure. The anal mucosa hardly reached a few centimetres above, and the anal canal was abnormally tight and nonelastic, up to the dentate line. As we performed anal mucosectomy, the mucosal lining was circumferentially dissected free. On the right buttock with less scarring, a diamond-shaped flap was constituted and transferred medially to meet the right-lateral mucosal edge over a partial internal sphincterotomy (Fig. 2). This dermal-mucosal

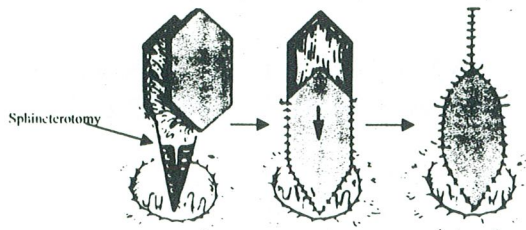


Fig - 2 : A diamond-shaped flap is outlined on the healthy skin surface and mobilized by deep incision into the subcutaneous tissue. The flap is advanced into the anal canal and sutured with absorbable sutures. The donor site is closed primarily (Modified from Buls JG: Benign anal strictures. In. Zuidema GD and Condon RE (eds): Shackelford's Surgery of the Alimentary Tract. 4th ed. Philadelphia: WB Saunders, 1996 : p 406).

edge was connected with absorbable sutures, and the rest of the freed mucosal edges were marsupialized circumferentially to create the new, fully-epithelialized, and partially everted anal opening (Fig. 3). The resultant anal opening lacked any raw surface and it was wide enough to allow passage of a lubricated index finger.

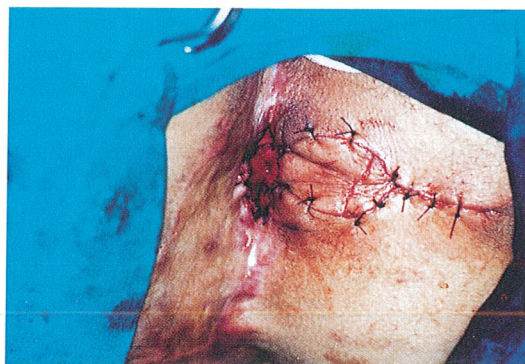

Fig - 3 : The resultant anal opening was tightly patent and lacked any raw surface.

The postoperative course was uneventful. Beginning with the third postoperative day, daily digital examinations were performed to check the opening. The patient was discharged on the seventh day and called for weekly visits. Two months postoperatively, the anal canal was normally patent and elastic. Anal manometric study revealed close to normal resting and squeeze pressure levels (53 mmHg and 110 mmHg, respectively). The patient could hold 100 cc of water instilled into the rectal ampulla without leakage, and expel it voluntarily. Colostomy closure was planned but postponed a few months because the patient wanted to go back to work and arrange his business before undergoing a fourth operation.

DISCUSSION

This case exemplifies a severe anal stenosis at a considerably high level, to which diamond flap anoplasty was successfully applied. Introduced in 1986 (3), this form of reconstruction, to our knowledge, does not yet have widespread application in our country. Therefore, we wanted to describe the technical details of this procedure, based on the theoretical advantages and the successful outcome obtained in our case. The method is easily reproducible because it does not require much technology or imaginative skill.

Anal stenosis may be congenital or acquired. The congenital forms are uncommon and include anal atresia and Hirschsprung's disease. Acquired anal stenosis usually follows nonspecific types of inflammation as a result of fissures, abscess, or dermatitis. The specific inflammatory diseases such as Crohn's disease, ulcerative colitis, lymphogranuloma venereum, syphilis, and actinomycosis are less common causes. Acquired anal canal stenosis is most commonly a result of prior hemorrhoidectomy. Other causes include laxative abuse (especially mineral oil), chronic anal fissure, neoplasia, inflammatory bowel disease, and irradiation. Postoperative anal stenosis is a serious complication of anal operations. To date, ideal management of this problem has not been well defined. Etiology of the stenosis are secondary to hemorrhoid operations in 87.7 %, anorectal surgical procedures associated with Crohn's disease in 3.3 %, and multiple other causes in the remaining 9.0 % (11). A treatment plan based upon the cause, severity, and level of stenosis of the anal canal (lower, middle and upper part of the canal) is proposed. The patient reported here developed a

severe form of anal stenosis due to the extensive inflammation of Fournier's gangrene. The early interventions, including surgical debridement and skin graft reconstruction, failed to prevent this cicatricial stenosis.

Anoplasty is a technique used to reconstruct the anal canal and the mucocutaneous junction. It can be used to replace descended mucosa as seen in anal canal stenosis. In severe cases, as noted by Corman et al. (8), the ensuing discomfort is generally unresponsive to nonsurgical treatments that fail to address the underlying anatomic distortion (fibrosis) of the anal canal. Most pure verge strictures will respond to a small incision and/or dilatation. Mid-anal canal dentate strictures with the exception of ileo-pouch-anal anastomosis will not respond permanently to dilation. The ideal procedure is one with minimal morbidity, good patient acceptance, simplicity of technique, and satisfactory long-term results. Several procedures of varying complexity involving local tissue transfer have been described. Internal sphincterotomy is selectively applied (1-5, 9). Since it was introduced by Caplin and Kodner in 1986 (3), the island flap anoplasty has become a popular choice for repair of mucosal ectropion and anal stenosis. Before this, the S-plasty (6, 8, 12) and Y-V pedicle flap (1, 13) were the most common forms of anoplasty. Recently, however, the S-plasty has been considered to be too extensive and complicated (3, 5, 9). In addition, both the S-plasty and Y-V anoplasty have had complications related to increased tension at the suture lines, failure to provide enough skin for repair, and undermining of the blood supply to the flaps leading to flap necrosis (3, 5, 14). Sarner (15) introduced a rectangular pedicle flap in 1969. The flap has more general applicability and would relieve anal stenosis regardless of origin or location. The major disadvantage is open wounds, including the donor site, at the procedure's end. Again, a partial lateral internal sphincterotomy is performed if the muscle seems to contribute to the stenosis.

The diamond-shaped island flap provides a very effective design for the treatment of patients with anal stenosis, as demonstrated in our case. This is a rather recent method, reflecting a rather modern surgical concept (3, 16). Its advantages are simplicity of construction, maintenance of maximal blood supply to the flap, minimal tension on the suture lines, and allowing for primary closure of the

donor site. Stenosis and ectropion have been satisfactorily repaired utilizing this technique. In conclusion, a variety of procedures may be used to relieve the problem when surgically significant anal stenosis occurs postoperatively. The decision as to which procedure to use should be based upon the cause of the stricture, the degree of stenosis, and its location. If the patient has underlying inflammatory intestinal disease, simple dilation is recommended to avoid healing problems. If not, diamond flap anoplasty, as described here, appears to be a safe, efficient, and reproducible method to apply, regardless of the level of stenosis.

10. Rosen L : Anoplasty. *Surg Clin North Am* 1988; 68 : 1441-6.
11. Milsom JW, Mazier WP : Classification and management of postsurgical anal stenosis. *Surg Gynecol Obstet* 1986; 163 : 60-64.
12. Hudson AT : S-plasty repair of Whitehead deformity of the anus. *Dis Colon Rectum* 1967; 10 : 57-60.
13. Gingold BS, Arvanitis M : Y-V anoplasty for treatment of anal stricture. *Surg Gynecol Obstet* 1986; 162 : 241-2.
14. Christensen MA, Pitsch RM, Cali RL, Blatchfort GJ, Thorson AG : "House" advancement pedicle flap for anal stenosis. *Dis Colon Rectum* 1992; 29 : 92-94.
15. Sarner JB : Plastic relief of anal stenosis. *Dis Colon Rectum* 1969; 12 : 277-280.
16. Pearl Rk, Hooks VH, Abracian H : Island flap anoplasty for the treatment of anal stricture and mucosal ectropion. *Dis Colon Rectum* 1990; 33 : 581-3.

Correspondence to : Dr.B.Bülent MENTEŞ
Gazi Üniversitesi Tıp Fakültesi
Genel Cerrahi Anabilim Dalı
Beşevler
06500 ANKARA - TÜRKİYE
Phone : 312 - 214 10 00 / 5719

REFERENCES

1. Nickel WB, Woodard ER : Advancement flaps for treatment of anal stricture. *Arch Surg* 1972; 104 : 223-4.
2. Khubchandani IT : Mucosal advancement anoplasty. *Dis Colon Rectum* 1985; 28 : 194-196.
3. Caplin DA, Kodner IJ : Repair of anal stricture and mucosal ectropion by simple flap procedures. *Dis Colon Rectum* 1986; 29 : 92-94.
4. Ramanujan PS, Venkatesh KS, Cohen M : Y-V anoplasty for severe anal stenosis. *Contemp Surg* 1988; 33 : 62-69.
5. Oh C, Zinberg J : Anoplasty for anal stricture. *Dis Colon Rectum* 1982; 25 : 809-810.
6. Ferguson JA : Whitehead deformity of anus, S-plasty repair. *Dis Colon Rectum* 1969; 12 : 286-7.
7. Rosen L : V-Y advancement for anal ectropion. *Dis Colon Rectum* 1986; 29 : 596-598.
8. Corman ML, Veidenheimer MC, Coller JA. Anoplasty for anal stricture. *Surg Clin North Am* 1976; 56 : 727-731.
9. Kaplan HY, Freund H, Muggia-Sullmen M, Wexler MR : Surgical correction of ectropion of the anal mucosa. *Surg Gynecol Obstet* 1982; 154 : 82-84.