

EPITHELIAL- LINED (TRUE) ADRENAL CYST ARISING FROM HETEROTOPIC ADRENAL CORTICAL TISSUE IN THE LESSER PERITONEAL SPACE

B.Bülent MENTEŞ, M.D.,

Naci EDALI*, M.D.,

Erdal YILMAZ, M.D.,

Sevilay KURŞAKLIOĞLU*, M.D.,

Meral ŞEN, M.D.,

Burçak KAYHAN**, M.D.

Gazi University, Faculty of Medicine, Department of General Surgery Pathology*, and Internal Medicine**, Ankara, Turkey

Gazi Medical Journal 1998; 9 : 175-180

SUMMARY : Adrenal cortical rests located outside the region of the embryonic or adult urogenital tract are very rare. In addition to the unusual location of an adrenal cortical rest in the lesser peritoneal space, an epithelial-lined (true) adrenal cyst originating from this heterotopic adrenocortical tissue is described. During surgery, the loose connective tissue attachments to the stomach, spleen, and mesocolon were easily dissected and a prominent vascular supply was not encountered. The inner surface of the cyst was lined by a layer of cuboidal to columnar epithelium that was focally flattened or denuded. Covering this lining, frequent patches of adrenocortical tissue were noted all around the cyst. Immunohistochemistry suggested a parenchymal origin for the inner lining cells, which stained strongly with vimentin. The cystic lesion was identified as a glandular retention cyst arising from heterotopic adrenal cortical tissue. Evidence is presented that epithelial retention cysts might develop in the adrenal cortical tissue, and for the first time, in an adrenocortical rest.

Key Words : Adrenal Cortex, Heterotopia, Cysts.

INTRODUCTION

Adrenal cortical heterotopias are not infrequent and are found exclusively in association with urogenital structures, owing to the close proximity of the adrenal cortical primordia to the developing gonad and to the mesonephric kidney, embryologically (1, 2). In practice, accessory (heterotopic) adrenocortical tissue is most often encountered around the adrenal glands themselves (2). Adrenal cortical rests located outside the region of the embryonic or adult urogenital tract are very rare (1, 3). Single cases have been reported in the wall of the gallbladder (4), in the pancreas (5), in the mediastinum (3), several cases in the liver (6,7) and in the lung (8, 9). These rests were regarded as bizzare occurrences that defied embryological

concepts.

Adrenal cortical rests are usually incidental findings during surgery or autopsy (2,5,10), and pathological conditions originating from such heterotopic adrenocortical tissue are extremely rare. Under unusual circumstances, such tissue takes on tumorous proportions (5,11). A single case of a virilizing adrenal cortical neoplasm arising ectopically in the thorax has been reported (12). For the first time in the literature, this case report describes an epithelial-lined (true) cyst of heterotopic adrenocortical tissue located in the lesser peritoneal cavity. Actually, even adrenal cysts located within the adrenal gland itself are uncommon, the epithelial subgroup being the most controversial as to its mode of origin (13-15). An

epithelial cyst arising from heterotopic adrenal cortical tissue may thus provide additional data for the theories about the poorly understood development of true adrenocortical cysts. The possible etiopathogenetic mechanisms involved and the diagnostic difficulties are discussed.

CASE REPORT

A 32-year-old woman presented with back pain and abdominal discomfort of six months' duration. Previous medical history was insignificant and systematic inquiry was unremarkable. Physical examination revealed a large, nontender, fixated mass deep in the epigastrium, slightly invading the left hypochondrium. Other physical findings, and routine laboratory investigations, were normal. Abdominal ultrasound (US) showed a 14 x 12 cm purely cystic mass medial and adjacent to the spleen. Computerized tomography (CT) confirmed the presence of the cystic lesion behind the stomach, ventral to the pancreas, and medial to the spleen, the adrenals and other abdominal and retroperitoneal structures being normal (Fig. 1). The organ from which the cyst originated could not be identified. Intravenous urography revealed normal renal outlines and collecting systems with a slight pressure effect on the superior pole of the left kidney. On angiography, upward displacement of the splenic artery and downward displacement of the left renal artery were noted. The splenic and portal veins were patent, and the lesion was avascular with slight delineation of its borders.

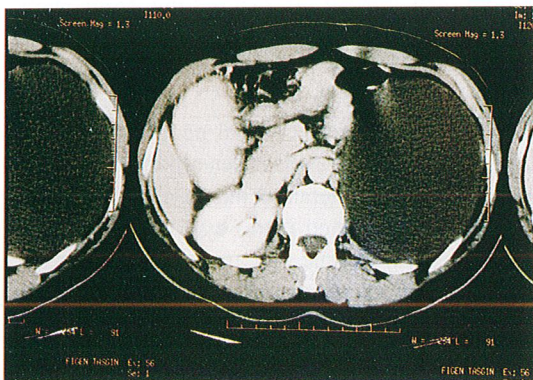


Fig - 1 : CT appearance of the large cystic lesion.

At laparotomy, an apparent mass was seen to bulge from behind the greater gastric curvature. Gastrocolic omentum was opened, and the cystic mass was seen to fill most of the lesser peritoneal cavity (Fig. 2). Grossly, the cyst wall was thin and membranous with scattered patches of yellowish tissue. With a fine needle, some yellowish, thin, turbid fluid was aspirated from the cyst. Instant cytological examination of this fluid sample revealed no malignant cells. The cyst fluid was also negative for echinococcus scolex and bacteria. The cystic lesion was located on the transverse mesocolon, and its loose connective tissue attachments to the stomach, spleen, and mesocolon were easily dissected. The dissection was bloodless, and a prominent vascular supply was not encountered. The cyst was totally excised, the controversial operative diagnosis being a mesenteric cyst.

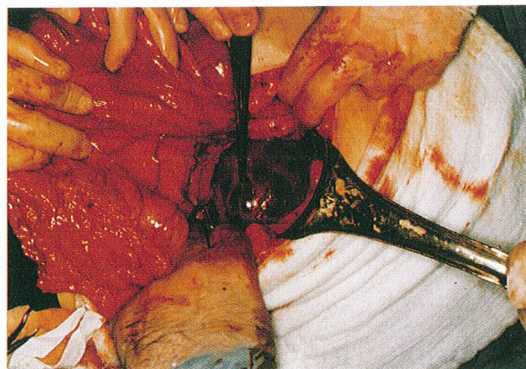


Fig - 2 : Operative view of the cyst following transection of the gastrocolic omentum. The transverse mesocolon is reflected caudally.

On gross examination, the specimen consisted of a partially collapsed cystic lesion with an irregular wall that contained scattered patches of yellowish tissue (Fig. 3). The clear, serous fluid content lacked any clotted blood or amorphous material. Histologically, the inner surface of the cyst was lined by a layer of cuboidal to columnar cells that were focally multilayered, flattened, or denuded. Over this lining, a fibrous wall was present. Scattered patches of adrenocortical tissue were noted within and over the fibrous cyst wall. This adrenocortical tissue and some lining cells

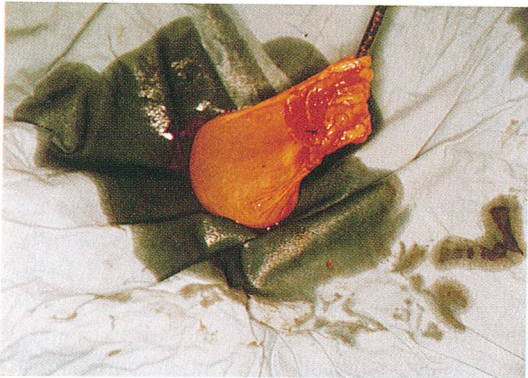

Fig - 3 : Gross view of the resected cystic lesion.

contained an intracellular yellow-brown pigment consistent with lipofuscin. Some patches of the adrenocortical tissue were well-differentiated to demonstrate typical zones. In some sections, the fibrous tissue predominated with a rather crowded epithelial lining. This fibrous wall was purely collagenous, and did not contain any elastic fibers or smooth muscle, confirmed by Verhoef's elastic and Masson's trichrome stains (components from Merck, Darmstadt, Germany).

Immunohistologic studies on formalin - fixed, paraffin - embedded sections were carried out with antibodies that react with low or high molecular weight cytokeratins (35 BH 11 and 34 BE 12, DAKO, Santa Barbara, CA), factor VIII - related antigen (DAKO), (1- antitrypsin (Biomedica, Foster City, CA), epithelial specific antigen (Novocastra, Newcastle, UK), or vimentin (Zymed, San Francisco, CA). The lining cells were not stained by any of these antibodies except for that against vimentin. Vimentin reactivity was strong and diffuse (Fig. 4). The pathological diagnosis was an epithelial cyst arising in heterotopic adrenal cortical tissue.

The postoperative course of the patient was uneventful. Additional laboratory investigations performed on the seventh postoperative day (after the pathological diagnosis) and two months later revealed comparable normal levels of 24-hour urinary free cortisol and 17-ketosteroids, as well as normal serum adrenocorticotrophic hormone, cortisol, androstenedione, estrogen, free

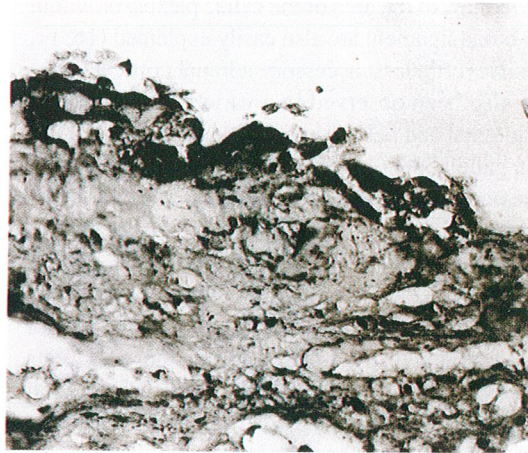


Fig - 4 : Positive staining with vimentin was shared by the inner lining cells of the cyst wall and some of the eccentric cells of the heterotopic adrenocortical tissue (vimentin, x 400).

testosterone, and aldosterone levels. The patient has been free of symptoms to the present.

DISCUSSION

In this study, we report a woman with clinical evidence of a large intraabdominal cystic lesion, which turned out to be an heterotopically located adrenal cortical cyst. The evidence that this cystic lesion was of adrenal origin was purely pathological. Unfortunately, the surgical team did not consider perioperatively that the cyst originated from heterotopic adrenal cortical tissue, and a more detailed analysis of the cystic fluid is therefore unavailable. The systematic inquiry and the physical findings did not suggest a functioning adrenal cortical lesion, although a complete endocrine evaluation of the patient could be provided only postoperatively.

Embryologically, the adrenal cortex is derived from primordia of mesodermal origin arising in the coelomic epithelium at the mesenteric root during the sixth week of gestation (2). These primordia develop medial to the developing gonad and anterior to the mesonephric kidney. During early development, the adrenal primordia are not encapsulated. Adrenal cortical rests are believed to arise when some cells derived from these unencapsulated primordia migrate with the developing gonad. Therefore, ectopic adrenocortical tissue may be found along the path of descent of or in association with the gonads (2, 5, 10). Common locations include the spermatic cord,

the epididymis, the hilum of the testis or ovary, and the fallopian tube. Rests found under the capsule of the kidney, in the area of the celiac plexus, or within the broad ligament are also easily explained (16, 17, 14). Nevertheless, accessory adrenal cortical tissue has also been observed in a variety of antithetical abdominal and pelvic sites, including the liver (6, 7, 18), gallbladder (4), pancreas (5) and placenta (19). The occurrence of adrenal cortical rests above the diaphragm is exceedingly rare, and only three cases have been reported in the literature (8, 9, 12). A mediastinal foregut cyst containing an intramural adrenal cortical rest was also reported by Wright and Gillis (3). Such rare adrenal cortical rests located outside the region of the embryonic or adult urogenital tract were regarded as bizarre occurrences that defied embryological concepts. Adrenal medulla is, by definition, absent in these adrenal cortical rests, and explained by the independent origin of the medulla from the neural groove and its relatively later migration into the adrenal gland cortex (2). The term 'adrenocortical rest' also excludes the rare cases of ectopia of the entire adrenal gland, such as that reported to occur in the cranium (20).

In our case, the location of the heterotopic adrenal tissue below the pancreas and above the transverse mesocolon defies embryological concepts. The cyst originating from this heterotopic tissue lacked any attachments to the neighboring organs, and the loose connective tissue adhesions to the transverse mesocolon were easily dissected. A definitive vascular supply that would suggest a possible origin was also absent. It is worth emphasizing that the cyst was not located within the transverse mesocolon and its dissection did not interfere with the integrity of the mesocolon. Therefore, the explanation for the unusual location of this lesion in the lesser peritoneal space is not possible with conventional embryological theories. In an attempt to explain intrathoracic adrenal cortical rests, it was suggested that misplaced mesothelial cells, which shared a common origin with the primitive pleural mesothelial cells, eventually differentiated to form these rests (8). Wright and Gillis hypothesized that the mesodermal primordia of adrenal cortical heterotopias could become trapped within the wall of the developing foregut and, as a result, become incorporated within structures that are foregut derivatives, such as the liver, gallbladder, and pancreas (3). This scheme could explain the rare

cases of adrenocortical rests occurring in the chest or abdomen, but not in the placenta. Nevertheless, a possible random misplacement of some cells of the mesodermal primordia of the adrenal cortex is theoretically in accordance with the independent location of the heterotopic cortical tissue in our case. Far from being satisfactory, these statements actually prove how little we really know about heterotopias.

Although reports vary greatly as to the actual incidence of adrenal cortical rests, these rests are almost always clinically silent and are usually incidental findings at surgery or autopsy (2,4,10). Pathological conditions originating from such heterotopic adrenocortical tissue are extremely rare. Adrenocytomegaly involving the cortical rest located in the lung of a newborn, as well as both orthotopic adrenals, was such a rare example (8). Massive hyperplasia of testicular adrenal rests was reported in a patient with Nelson's syndrome (11). An adrenal cortical neoplasm attached to the posterior pericardium was described by Medeiros and coworkers to be the cause of virilization in a 44-year-old woman (12). These interesting cases deserved a unique place within the colorful spectrum of human pathology, and they obfuscated the already confusing area of heterotopic adrenal tissue.

In addition to the unusual location of the adrenal cortical rest in the lesser peritoneal space in our patient, we are not aware of a similar case reported previously of an adrenal cyst arising from a heterotopic adrenocortical tissue. Actually, even adrenal cysts located within the adrenal gland itself are uncommon, and approximately 300 adrenal cysts have been reported in the literature (13-15). This number encompasses a heterogeneous group of lesions of different etiologies that includes endothelial-lined cysts, pseudocysts, parasitic cysts, and epithelial-lined or true adrenal cysts (15, 21-23). Although beyond the scope of this article, the reader should recall that endothelial cysts and pseudocysts represent 80% of all adrenal cysts (24). Endothelial cysts are the most common type, and they can be further subdivided into a lymphangiomatous and angiomatous group, with the former being the more common. They possess an endothelial lining and may result from faulty development with the isolation of small vascular spaces, which can occasionally enlarge. Pseudocysts have a pure fibrous lining and are

believed to result from infarction or hemorrhage and subsequent clot organization within a normal gland. The possibility of an infrequent hemorrhage into a benign or malignant tumor appearing as a cystic mass has also been emphasized (25). Parasitic cysts represent another entity and are most commonly echinococcal in origin. Epithelial-lined or true cysts of the adrenal gland are the least common. They have been further subdivided into subgroups based on proposed theories of pathogenesis: Glandular or retention cysts, cysts arising within adrenal adenomas, and embryonal cysts (26). An epithelial cyst lining of mesothelial origin, analogous to the hypothesized pathogenesis of primary splenic cysts, was also suggested by Medeiros and coworkers (22). These are briefly mentioned for an easy background necessary to figure out the formation of an adrenal cortical cyst.

The cyst reported in this paper possessed a non uniform epithelial cluster that closely resembled the adrenal cortex. Therefore, the possibility of origin from an embryonal rest appeared to be a logical suggestion. The inner surface of the cyst was lined by a layer of cuboidal to columnar epithelium that was focally flattened or denuded. Covering this lining, frequent patches of adrenocortical tissue were noted all around the cyst. Therefore, the histopathological differential diagnosis should include all kinds of adrenocortical cysts that were briefly mentioned above. First of all, the presence of a cellular lining was inconsistent with a pseudocyst, by definition. Also, there existed no gross or histological evidence of a parasitic (echinococcal) origin. The cyst wall contained no elastic fibers or smooth muscle tissue, and the cuboidal to columnar lining cells were not stained by anti - factor VIII, all arguing against an endothelium-lined cyst of vascular origin. With these findings, the cyst was identified as an epithelial (true) cyst of heterotopic adrenocortical tissue, and a difficult differentiation between the above mentioned subgroups of such epithelial cysts was attempted. There is unfortunately very little precedent in the literature that would mediate this discussion. Besides, the pressure effect of the cystic fluid on the very inner lining cells possibly obscured their microscopical or immunohistochemical differentiation. Immunohistochemistry with low or high molecular weight cytokeratin negativity was strong evidence against a mesothelial origin, although an epithelial membrane antigen positivity could not be obtained

in the same order. The cells also failed to stain with antibodies to $\alpha 1$ - antitrypsin, arguing against the presence of residual histiocytic cells substituting for the focally destructed lining cells of the cyst lumen. Strong and diffuse staining with vimentin suggested a parenchymal origin for the inner lining cells. This vimentin positivity is a well - described feature of zona glomerulosa cells, as well as mesothelial cells that had been ruled out in our case by the failure to stain with antibodies to cytokeratins (2, 27). Positive staining with vimentin was shared by the inner lining cells and some of the eccentric cells of the heterotopic adrenocortical tissue, resembling the cells of zona glomerulosa. An embryonal cyst, on the other hand, should have an epithelial lining foreign to the adrenal cortex and arising from displaced embryonic rests, such as ciliated or mucinous epithelium (28). The present cyst lacked any demonstrable feature to suggest an embryonal cyst, although we cannot contradict this hypothesis which has been exemplified by a single case in the literature (28). No adenomatous changes were noted within the surrounding heterotopic adrenocortical tissue, either. A glandular retention cyst, as a result, appeared to be a theoretical possibility for the classification of this epithelial cyst. The existence of glandular retention cysts has been doubted on the grounds that adrenal cortex cannot form acini (24). Other authors have considered acini and microcyst formation as part of the normal development of the adrenal cortex (29, 26). The transition from the normal adrenal cortex into acinar formation and then cyst formation was clearly demonstrated in two cases of adrenal cysts reported by Ghandur-Mnaymneh and coworkers, who suggested that epithelial retention cysts may occur in the adrenal cortex as a recapitulation of the normal embryonic development (26). The same mechanism might apply to the cyst reported in this paper. The adrenal cortical rest from which the cyst originated probably represented a rather less differentiated adrenocortical tissue and it lacked a prominent vascular supply. Still, other factors need to be defined that mediate the pathogenesis of such epithelial cysts because adrenocortical heterotopias are so common, while cysts originating from these rests have not been reported until now. The authors are aware that once the histopathological differential diagnosis of an epithelial adrenal cortical cyst is provided, any further classification is only speculative.

Nevertheless, the features of this cystic lesion provided considerable evidence that epithelial retention cysts could develop in the adrenal cortical tissue, and for the first time, in an adrenocortical rest.

In summary, an epithelial-lined (true) cyst of a heterotopic adrenocortical tissue located in the lesser peritoneal cavity is described. Its features might provide additional insight into the possible pathogenesis of some epithelial cysts of the adrenal cortex, which has been poorly understood. The abnormal location of the heterotopic adrenal cortical tissue and the very unusual true cystic lesion arising from this rest combine to provide another example of bizarre occurrences that increase the breadth of knowledge and imagination of clinicians and pathologists.

Correspondence to : Dr.B. Bülent MENTEŞ
Gazi Üniversitesi Tıp Fakültesi
Genel Cerrahi Anabilim Dalı
Beşevler
06500 ANKARA - TÜRKİYE
Phone : 312 - 214 10 00 / 5719

REFERENCES

1. Schechter DC : Aberrant adrenal tissue. *Ann Surg* 1968; 167: 421-426.
2. Carney JA : Adrenal gland. In: Sternberg SS, ed. *Histology for Pathologists*. New York: Raven Press, 1992 : 322-340.
3. Wright JR, Gillis DA : Mediastinal foregut cyst containing an intramural adrenal cortical rest: a case report and review of supradiaphragmatic adrenal rests. *Pediatr Pathol* 1993; 13 : 401-407.
4. Busuttill A : Ectopic adrenal within the gall - bladder wall. *J Pathol* 1973; 113 : 231-233.
5. Gualtieri T, Segal AD : Report of a case of adrenal type tumor of the spermatic cord: A review of the aberrant adrenal tissues. *J Urol* 1949; 61 : 949-955.
6. Weller CV : Heterotopia of the adrenal in liver and kidney. *Am J Med Sci* 1925; 109 : 696-712.
7. Vestfrid MA : Ectopic adrenal cortex in neonatal liver. *Histopathology* 1980; 4 : 669-672.
8. Boziec C : Ectopic fetal adrenal cortex in the lung of a newborn. *Virchows Arch Pathol Anat Histol* 1974; 363 : 371-374.
9. Armin A, Castelli M : Congenital adrenal tissue in the lung with adrenal cytomegaly. *Am J Clin Pathol* 1984; 82 : 225-228.
10. Mares AJ, Shkolnik A, Sacks M, Feuchtwanger MM : Aberrant (ectopic) adrenocortical tissue along the spermatic cord. *J Pediatr Surg* 1980; 15 : 289-292.
11. Johnson RE, Scheithauer B : Massive hyperplasia of testicular adrenal rests in a patient with Nelson's syndrome. *Am J Clin Pathol* 1982; 77 : 501-507.
12. Medeiros LJ, Anasti J, Gardner KL, Pass HI, Nieman LK : Virilizing adrenal cortical neoplasm arising ectopically in the thorax. *J Clin Endocrin Metab* 1992; 75 : 1522-1525.
13. Ince JS, Lui PS, Merriam JC, Austin G, Widrich WC, Gerzof SG : Morphology and pathogenesis of adrenal cysts. *Am J Pathol* 1979; 95 : 423-432.
14. Falls JL : Accessory adrenal cortex in the broad ligament. Incidence and functional significance. *Cancer* 1955; 8 : 143-147.
15. Davenport M, Pollard K, Smith SEW, MacMahon MJ : Adrenal cysts - report, review and classification. *Postgrad Med J* 1988; 64 : 71-73.
16. Mitchell N, Angrist A : Adrenal rests in the kidney. *Arch Pathol* 1943; 35 : 46-52.
17. Graham LS : Celiac accessory adrenal glands. *Cancer* 1953; 6 : 149-152.
18. Wallace EZ, Leonidas JR, Stanek AE, Avramides A : Endocrine studies in a patient with functioning adrenal rest tumor of the liver. *Am J Med* 1981; 70 : 1122-1124.
19. Labarrere CA, Caccamo D, Telenta M, Althabe O, Gutman R : A nodule of adrenocortical tissue within a human placenta: light microscopic and immunocytochemical findings. *Placenta* 1984; 5 : 134-144.
20. Wiener MF, Dallgaard SA : Intracranial adrenal gland. *AMA Arch Pathol* 1959; 67 : 228-233.
21. Buchino JJ, Dougherty HK, Shearer LT : Adrenal cyst. *Arch Pathol Lab Med* 1985; 109 : 377-379.
22. Medeiros LJ, Weiss LM, Vickery AL : Epithelial - lined (true) cyst of the adrenal gland: a case report. *Human Pathol* 1989; 20 : 491-492.
23. Sroujeh AS, Farah GR, Haddad MJ, Abu - Khalaf MM : Adrenal cysts: diagnosis and management. *Br J Urol* 1990; 65 : 570-575.
24. Foster DG : Adrenal cysts. Review of the literature and report of a case. *Arch Surg* 1966; 92 : 131-143.
25. Bush WH, Elder JS, Crane RE, Wales LR : Cystic pheochromocytoma. *Urology* 1985; 25 : 332-334.
26. Ghandur - Mnaymneh L, Slim M, Muakassa K : Adrenal cysts: pathogenesis and histological identification with a report of six cases. *J Urol* 1979; 122 : 87-91.
27. Carter D, True L, Otis CN : Serous membranes. In: Sternberg SS, ed. *Histology for Pathologists*. New York: Raven Press, 1992 : 505.
28. Abeshouse GA, Goldstein RB, Abeshouse BS : Adrenal cysts: review of the literature and report of three cases. *J Urol* 1959; 81 : 711-719.
29. Rodin AE, Hsu FL, Whorton EB : Microcysts of the permanent adrenal cortex in perinates and infants. *Arch Pathol Lab Med* 1976; 100 : 499-502.