

EXTREMELY DISTAL ORIGIN OF EXTENSOR INDICIS MUSCLE

Mustafa Fevzi SARGON, Ph.D., H.Selçuk SÜRÜCÜ, Ph.D.

Hacettepe University, Faculty of Medicine, Department of Anatomy, Ankara, Turkey
Gazi Medical Journal 5 : 175-177, 1994

SUMMARY : *The extensor indicis muscle originates from the posterior surface of the ulna below the extensor pollicis longus and the interosseous membrane. Its tendon passes under the extensor retinaculum; opposite the head of the second metacarpal bone and joins the ulnar side of extensor digitorum for the index finger. In our cadaver, the muscle was originated from the scaphoid bone and it was inserted to the extensor expansion of the index finger.*

Key Words : *Extensor Indicis Muscle, Variation.*

INTRODUCTION

The extensor indicis is a narrow, elongated muscle, medial to and parallel to the extensor pollicis longus muscle. It arises from the posterior surface of the ulna under the extensor pollicis longus and from the interosseous membrane. Its tendon passes under the extensor retinaculum in the compartment containing the tendons of the extensor digitorum; opposite the head of the second metacarpal bone it joins the ulnar side of the tendon of the extensor digitorum for index finger. The muscle occasionally sends accessory slips to the extensor tendons of other digits. Rarely its tendon may be interrupted on the dorsum of the hand by an additional muscle belly (extensor indicis brevis manus) (9).

The extensor indicis assists in extension of the index finger independently, however, allowing extension of this finger without that of the remaining fingers. According to Jones, it is also an excellent adductor of the digit (4).

We have encountered this variation during the gross anatomical dissection of a 42 year old male cadaver.

CASE REPORT

During dissection of the deep group muscles of the extensor aspect of left forearm and hand, an anomalous origin of the extensor indicis muscle was observed in our cadaver. The muscle seemed to be originating from the scaphoid bone and it is inserted to extensor expansion of the index finger (Fig 1, 2, 3). The belly of this muscle was approximately 5.2 cm. and its tendon was approximately 10.6 cm in length.

Extensor indicis muscle of the right side was normal in every aspect.

DISCUSSION

Anomalies of the extensor muscles of the forearm are reported by many authors. Cauldwell, Anson and Wright studied the extensor indicis muscle in 263 specimens. They found an abnormal origin

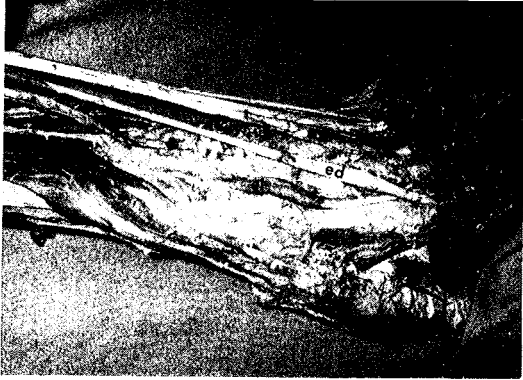

Fig - 1 : The extensor indicis muscle in our cadaver showing variation of its origin.

ed : Tendon of extensor digitorum going to the index finger.
ei : Extensor indicis muscle.




Fig - 2 : The extensor indicis muscle in our cadaver showing variation in its origin.

ei : Extensor indicis muscle.

of the muscle in three cases. In one case, the muscle had an usual origin from ulna, became tendinous and then again became muscular with a secondary attachment to the region of carpal bones. In the second case a muscle with a rudimentary origin at the normal site is inserted into a second muscle arising in two heads from the proximal carpal bones. In the third case a short muscle was found to be arising from the distal end of the radius, proximal carpal bones and related ligaments (1). Jones described an anomalous extensor indicis muscle arising from the soft tissues on the dorsum of the wrist under cover

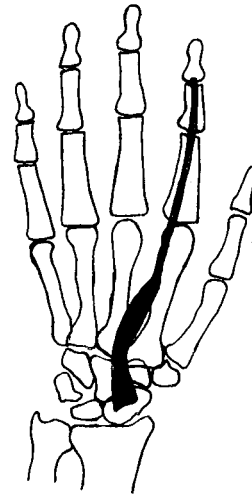


Fig - 3 : Schematic drawing of the abnormal extensor indicis muscle in our cadaver.

of the extensor retinaculum (5). Murakami and Todani observed an extensor indicis brevis muscle with an unusual ganglion. This muscle arose from the undersurface of the extensor retinaculum with a poorly developed muscle belly and became continuous with a tendon which is inserted into the ulnar side of the extensor hood of the index finger. The muscle and its tendon were densely adherent to the ganglion throughout the course (6). An anomalous muscle, the extensor digitorum brevis was found bilaterally in a 45 year old man who presented with a swelling on the dorsum of both hands (3). Schroeder and Botte dissected 58 adult hands to determine the incidence and anatomy of the extensor medii proprius and extensor indicis et medii communis. The incidence of the extensor medii proprius was 10.3 % and the incidence of the extensor indicis et medii communis was 3.4 % in their series (8).

Anomalous muscles are often confused with ganglia, synovial cysts, synovitis, tumors and exostosis (2). The presence of the muscle can be demonstrated by EMG (7). These type of abnormal muscles may constrict the extensor retinaculum and they may cause symptoms such as pain and discomfort. A clinician must always remember the possibility of the presence of an abnormal muscle under the extensor retinaculum in such type of symptoms.

Correspondence to : Dr. Mustafa Fevzi SARGON
Hacettepe Üniversitesi Tıp Fakültesi
Anatomi Anabilim Dalı
06100 ANKARA - TÜRKİYE
Phone : 312 - 488 71 28

REFERENCES

1. Cauldwell EW, Anson BJ, Wright RR : The extensor indicis proprius muscle. A study of 263 consecutive specimens. *Quart Bull Northwestern Univ Med School* 1943; 17 : 267.
2. Gama C : Extensor digitorum brevis manus : A report on 38 cases and a review of the literature. *J Hand Surg* 1983; 8 : 578-582.
3. Gebuhr P, Klaserkow B : Extensor digitorum brevis manus : A case report. *Acta Orthop Scand* 1987; 58 : 85-86.
4. Hollinshead WH : *Anatomy for surgeons : volume 3, The back and limbs*, 2nd edition, Hoeber Medical Division, New York 1969; p. 433.
5. Jones BV : An anomalous extensor indicis muscle. *J Bone Joint Surg* 1959; 41 B (4) : 763-765.
6. Murakami Y, Todani K : The extensor indicis brevis muscle with and unusual ganglion. *Clin Orthop and Rel Research* 1982; 162 : 207-209.
7. Reef TC, Brestin SG : The extensor digitorum brevis manus and its clinical significance. *J Bone Joint Surg* 1975; 57-A : 704-706.
8. Schroeder HP, Botte MJ : The extensor medii proprius and anomalous extensor tendons to the long finger. *J Hand Surg* 1991; 16-A : 1141-1145.
9. Williams PL, Warwick R : *Gray's Anatomy*. 36th. edition, Churchill Livingstone, Edinburgh, London, Melbourne and New York 1980; p. 583.