

BILATERAL RENAL ANGIOMYOLIPOMATOSIS IN TUBEROUS SCLEROSIS: A CASE REPORT

Ülver DERİCİ, M.D., Tarkan KARAKAN*, M.D., Turgay ARINSOY, M.D.,
Toygun ORBAY**, M.D., Musa BALI, M.D., Şükrü SİNDEL, M.D.

Gazi University, Faculty of Medicine, Departments of Nephrology, Internal Medicine* and Neurosurgery**, Ankara, Turkey
Gazi Medical Journal 1998; 9 : 139-141

SUMMARY : A 19-year-old woman with the diagnosis of tuberous sclerosis was found to have bilateral renal angiomyolipomas. About 80 % of patients with tuberous sclerosis have bilateral renal angiomyolipomas. Nevertheless, only 50 % of angiomyolipomas are associated with tuberous sclerosis. These lesions carry the risk of severe hemorrhage and even hypovolemic shock with respect to their size. Here we describe a case of tuberous sclerosis associated with bilateral renal angiomyolipomas. We discussed the importance of early diagnosis and periodic follow-up of angiomyolipomas in these patients, risk factors for complications, and recent therapy modalities in the literature.

Key Words: Tuberous Sclerosis, Angiomyolipoma, Kidney Neoplasms.

INTRODUCTION

Tuberous sclerosis is an inherited disorder characterized by seizures, mental retardation, cutaneous lesions, and visceral hamartomas (1) Angiomyolipomas (hamartomatous tumors in the kidney) are usually bilateral and multiple, and contain variable amounts of fatty, muscular and vascular components (2). For this reason, the term angiomyolipoma is widely used. In 1911, Fischer initially described histologic appearance of angiomyolipoma, and in 1951, Morgan et al. defined the name of the lesion (2, 3). Two variant forms exist: 1) Unilateral, solitary, symptomatic, moderate-sized and middle age women predominant type (M: F=4:11), 2) Bilateral, multiple, various size and associated with tuberous sclerosis. Previous series reveal that 20-50 % of angiomyolipomas are associated with tuberous sclerosis and 40-80 % of tuberous sclerosis patients have angiomyolipoma. Histological aspects of

these two types are similar and possibly two variant forms of the same disease (2, 4). Herein, we describe a case of tuberous sclerosis with bilateral angiomyolipoma, which is a relatively rare clinical situation.

CASE REPORT

A 19-year-old woman was admitted to our hospital for loss of vision and exophthalmus. Since seven years, the patient had skin lesions on her face and trunk. These lesions later diagnosed as adenoma sebaceum. She had generalized seizures since two years. One and a half month ago, she had blurred vision with an acute onset, nausea, vomiting and finally an intracranial mass lesion was diagnosed by cranial computerized tomography. Two weeks ago, her vision had gradually diminished and finally lost.

Physical examination on admission revealed a cachectic, chronically ill woman. The blood

pressure was 110/60 mmHg, the pulse rate was 84/min; the temperature was 36.2°C. There were multiple adenoma sebaceum on the skin of her face, neck and trunk. Hipopigmented nodules were also present in left subcostal area and lateral to the left patella, 3x4 and 2x2 cm in size, respectively. Bilateral exophthalmus and upward gaze palsy were noticed. Pupils were middilated with bilateral positive light reflexes. Minimal diffuse hyperplasia of the thyroid gland was noticed. No lymphadenopathy was noted. The results of chest and cardiovascular examinations were unremarkable. Neurological examination revealed neck rigidity, left central facial palsy, and extensor plantar response on the right lower limb.

Routine laboratory examinations were normal, including complete blood count, erythrocyte sedimentation rate, urinalysis, and blood chemistry. Cranial MRI revealed a lobulated mass lesion of 3x2.5x2.5 cm localized at the left lateral ventricular atrium and continuous with ependymal region. The mass showed both hypointense and hyperintense signals in T1A and T2A weighted images. A heterogeneous distribution of contrast substance was noted. These lesions resembled subependymal giant-cell astrocytoma that is common in tuberous sclerosis (Fig. 1). Abdominal ultrasound revealed multiple solid lesions in both kidneys with hyperechoic and hypoechoic areas. These lesions were smaller than 2.5 cm and resembled angiomyolipomas (Fig. 2). Bilateral papilledema was noted in fundoscopic

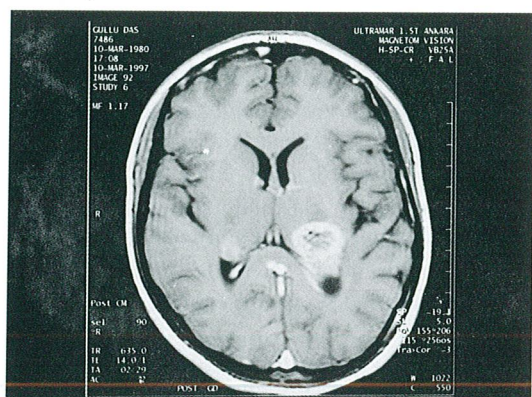


Fig - 1 : Cranial MRI appearance: a lobulated mass lesion localized at the left lateral ventricular atrium and continuous with ependymal region.

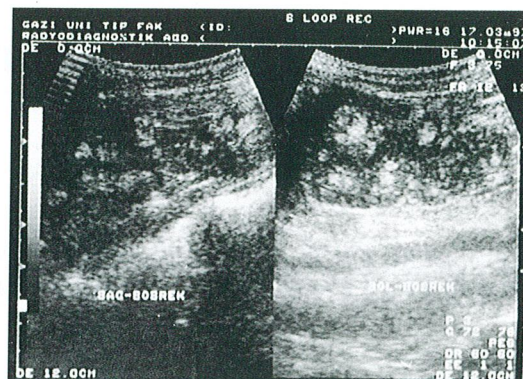


Fig - 2 : Ultrasound image of angiomyolipomas. These multiple solid lesions containing hyperechoic and hypoechoic areas were also demonstrated in both kidneys.

examination. Computerized tomography (CT) scanning of the orbits showed optic nerve sheath swelling, bilateral global exophthalmus, oculomotor nerve, and especially left abducence nerve compression. Thyroid function tests were in normal limits and the nature of exophthalmus could not be determined. The patient was given dexamethasone (48 mg/day) for increased intracranial pressure and phenytoin (300 mg/day) for generalized seizures. Dexamethasone dosage tapered gradually. Partial regression of symptoms was achieved, and the patient was discharged on her own will.

DISCUSSION

Most of the tuberous sclerosis patients are asymptomatic for their renal involvement, and in this respect, great attention must be paid. The mortality of tuberous sclerosis patients is high due to neurological complications. Mortality rate is 30-40% at the age five, and 75 % at 20. Therefore, chronic renal failure, as a late complication, is very seldom(1,4). Three types of renal involvement have been described in tuberous sclerosis: a) angiomyolipoma (40-80 %), b) cystic disease (occasionally), c) renal cell carcinoma (1). On the other hand, the previous studies demonstrated that only 20-50 % of angiomyolipomas are associated with tuberous sclerosis (2, 4). The demonstration of fat on renal ultrasound and CT can accurately diagnose angiomyolipoma in 95 % of the cases (2). The radiographic features of angiomyolipomas on

ultrasound examination (echogenic areas) or CT scanning (areas of fatty tissue; -20 to -60 Hounsfield units) are pathognomonic (5).

Multiple bilateral angiomyolipomas can decrease renal reserve and may cause renal function deterioration. Also there are very seldom forms that may grow and compress to adjacent structures such as renal vein, inferior vena cava and even right atrium. Spleen, lymph node and retroperitoneal soft tissue invasion can also be observed. Most surgeons agree that these tumors are multicentric with rare local invasion rather than metastatic spread (2) Generally, growth and metastasis of these lesions are very rare; but especially for lesions greater than 3.5-4 cm-in size and during pregnancy periods, the risk of hemorrhage and hypovolemic shock is critical (3,6). In our case, the size of the lesion was 2.5x2 cm, which was below the critical size for hemorrhage risk. Ultrasonographic follow-up of these patients with the interval of 6 months is advised in the literature (3). The risk of renal failure secondary to growth of size or number of lesions should also be carefully followed.

Lesions greater than 3.5-4 cm size are at great risk of serious spontaneous hemorrhage and need to be explored. Especially, when the lesions are greater than 10 cm, preferred route of treatment is partial nephrectomy or selective arterial embolisation (2, 3, 6). Our case was an example of tuberous sclerosis together with bilateral angiomyolipomas. Although our patient did not carry a high risk of complications described above, the possibility of greater lesions in other tuberous sclerosis cases should be kept in mind. On the other hand, a smaller lesion should be followed carefully for the possibility of growth in the future.

Correspondence to : Dr. Ülver DERİCİ
Gazi Üniversitesi Tıp Fakültesi
Nefroloji Bilim Dalı
Beşevler
06500 ANKARA - TÜRKİYE
Phone : 312 - 214 10 00 / 5232

REFERENCES

1. Kalra OP, Verma PP, Kochhar S, Jha V, Sakhuja V : Bilateral renal angiomyolipomatosis in tuberous sclerosis presenting with chronic renal failure: Case report and review of the literature. *Nephron* 1994; 68 : 256-258.
2. Kennelly MJ, Grossman HB, Cho KJ : Outcome analysis of 42 cases of renal angiomyolipoma. *J Urol* 1994; 152 : 1988-1991.
3. Steiner MS, Stanford MG, Fishman EK, Marshall FF : The natural history of renal angiomyolipoma. *J Urol* 1993; 150 : 1782-1786.
4. Munjal AK, Schultz S : Adult onset of renal angiomyolipoma in a patient with tuberous sclerosis. *Urol Radiol* 1992; 14 : 144-147.
5. Neumann HPH : Case 18-1994: Tuberous sclerosis. *NEJM* 1994; 331 : 813.
6. Van Baal JG, Smits NJ, Keeman JN, Lindhout D, Verhoef S : The evolution of renal angiomyolipomas in patients with tuberous sclerosis. *J Urol* 1994; 152 : 35-38.