

CASE REPORTS

MASSIVE INTRASCROTAL BLADDER HERNIA

Kenan İSEN, M.D., Zafer SINIK, M.D., Öge TAŞÇILAR*, M.D., Hasan BİRİ, M.D.,
Metin ONARAN, M.D., İbrahim BOZKIRLI, M.D.

Gazi University, Faculty of Medicine, Departments of Urology and General Surgery*,
Ankara, Turkey
Gazi Medical Journal 1998; 9 : 35-37

SUMMARY :

Massive inguinoscrotal bladder hernia is a rare entity. A massive inguinoscrotal hernia was found in a 52-year-old man who complained of scrotal swelling and a 2-stage micturation. The case is presented and discussed in view of the literature.

Key Words: Bladder, Hernia, Intrascrotal Hernia.

INTRODUCTION

The bladder may be a component of inguinal hernias in man over the age of 50 years and only a small portion of the bladder is usually involved (1). However massive bladder hernia, also called scrotal cystocele, is a rare entity (2). Preoperative diagnosis of such hernias is important to avoid injury to the bladder and ureter. Intravenous pyelography (IVP), retrograde cystography, pelvic ultrasonography (USG) and computerized tomography (CT) have been useful in preoperative diagnosis of inguinoscrotal hernia (3-5).

CASE REPORT

A 52-year-old man complained of 2-stage micturation, nocturia, dysuria and has a three-year history of right scrotal enlargement which diminished after voiding. Medical history was remarkable only for hypertension. On physical examination, the right scrotum was massively enlarged. The right testicle was palpable and of normal size. Rectal examination revealed a normal

prostate. Laboratory studies including complete blood count, blood chemistry, urine analysis and urine culture were normal. IVP showed good renal function, the distal ureteric segments appeared to be in normal position. Cystography demonstrated the bladder descending into the scrotum (Fig. 1). At pelvic USG herniation in the right scrotum with a passage way to the bladder was observed. The patient was operated with the diagnosis of inguinoscrotal bladder hernia. Through an inguinal approach, the herniated part was reduced and the inguinal floor repaired. Control pelvic USG, cystography performed one month after the operation (Fig. 2). The contours of the bladder were normal and no inguinoscrotal herniation was detected.

DISCUSSION

Involvement of the bladder has been reported in 1-4% of all inguinal hernias (6). However massive inguinoscrotal herniation is rare, with only 75 cases reported in literature (6). Large inguinoscrotal hernias is termed as scrotal cystocele by Levine (2).

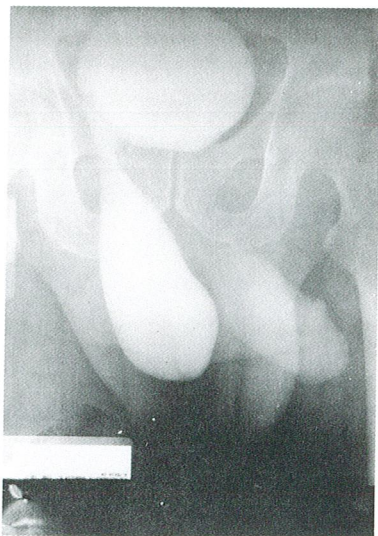


Fig - 1 : Preoperative cystography of the patient showing the bladder descending into the scrotum.

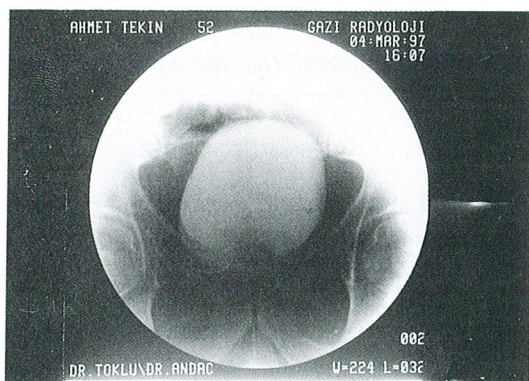


Fig - 2 : Postoperative cystography of the patient.

Seventy percent of vesical hernias occur in an inguinal location especially in male patients (7). Watson (8) reported a ratio of 1:3 femoral to inguinal hernias, and femoral hernias are more common in women. Rarely the bladder can herniate in the obturator canal, suprapubic space, ischiorectal fossa, abdominal wall or other pelvic&abdominal openings (7, 8). The majority of these hernias occur on the right side and are direct hernias. Bladder hernias are anatomically categorized as paraperitoneal, intraperitoneal and extraperitoneal (9).

The etiology of bladder hernias involves a

structural defect or senile atrophy in the supportive tissue of the abdominal wall. Urinary outlet obstruction (secondary to the prostatic enlargement, prostatitis, bladder neck contracture or urethral stricture), perivesical fat protrusion, loss of bladder tone with weakness of supporting structures, traumatic diastasis of pubic symphysis and obesity are also predisposing factors (7, 10).

While most of the small bladder hernias are asymptomatic massive inguinoscrotal hernias are almost always associated with symptoms (6). Some symptoms are nonspecific including frequency, nocturia, dysuria, urgency and hematuria which may be related to bladder outlet obstruction or infection (2,10). The predominant symptom, also present in our case, is 2-stage micturation in which the first stage is spontaneous and the second with manual compression of the hernia sac (3, 4, 10). Reduction in the size of herniation after voiding is a more specific finding (3, 9).

Preoperative identification of bladder herniation is important for avoiding trauma to the bladder or ureter during operative repair (5). Only 7 % of the cases are diagnosed preoperatively while 16 % are diagnosed postoperatively because of urinary leakage and sepsis (8). Complications of bladder herniation are strangulation, bladder rupture, hydronephrosis, carcinoma and calculi (5, 11).

Bladder hernia was first demonstrated radiographically in 1929 (12). Lateral displacement of distal third of one or both ureters, a small asymmetrical bladder and association of bladder with an inguinal hernia on IVP are characteristic for bladder hernia (13). Routine IVP will often not detect a hernia of the bladder because the focus may not be centered low enough to include the herniation. IVP should include erect, prone, delayed and post-voiding films (5,7).

Because of limited visualization of the bladder base on IVP the importance of cystography has been stressed by several investigators (6,10). Retrograde cystography probably diagnoses bladder herniation most easily when the herniation is large as in this case. A dumbbell configuration of the herniated segment of the contrast filled bladder may be seen clearly in cystography (1, 6, 7, 10). Cystography is recommended for every male patients with a large inguinal hernia over an age of 50 (5, 7, 13).

USG demonstrates a passage way between the bladder and the cystic mass in the scrotum. This is the most valuable finding, also observed in our case. This abnormality must be differentiated from scrotal abscess and cystic lesions of the scrotum, such as hydrocele/epididymal cyst (3).

CT shows anterior and inferior angulation of the base of the bladder over the pubic bone. If the neck of the bladder is wide the hernia can be clearly seen entering the inguinal canal. However when it is narrow or when the bladder is not well distended, even a large hernia may not be detected unless imaging is continued inferiorly through the scrotum. Advantage of CT is not only evaluating the genitourinary system but also excluding the presence of other structures in the hernia sac and ruling out tumor or testicular involvement (3-5).

Surgical repair of scrotal herniation the bladder is usually done via an inguinal incision (14). Preoperative diagnosis of the condition may influence surgical approach. A modified Pfannenstiel incision may be used instead of the standart inguinal incision to gain better approach (10). Resection or reduction of the herniated bladder is then performed in conjunction with repair of the inguinal floor (15). Reduction of the hernia allows for avoidance of cystostomy and possible wound contamination, decreased risk of ureteral damage and preservation of bladder volume (6, 9, 10). Resection of the bladder is indicated for possible tumorigenesis or strangulation with necrosis (6). Hernia sac should not be a contraindication to reduction (6, 9). In our case, through an inguinal approach, the herniated part was reduced and the inguinal floor repaired. Postoperatively, no complications were observed.

In conclusion, routine preoperative radiologic evaluation is recommended in men older than 50 years who have prostatism associated with an inguinal or femoral hernia. Preoperative diagnosis of such hernias is important to avoid injury to the bladder and ureter during the repair of hernia.

Correspondence to : Dr.Kenan İSEN
Gazi Üniversitesi Tıp Fakültesi
Üroloji Anabilim Dalı
Beşevler
06500 ANKARA - TÜRKİYE
Phone : 312 - 214 10 00 / 6233
Fax : 312 - 212 90 21

REFERENCES

1. Croushore JH, Black RB : Scrotal cystocele. J Urol 1979; 12: 541-542.
2. Levine B : Scrotal cystocele. JAMA 1951; 147 : 1439-1441.
3. Yağcı C, Aytacı S, Özcan H, Aydos K : Radiographic findings of massive bladder hernia. Turkish Journal of Medical Sciences 1997; 25: 95-97.
4. İzes BA, Larsen CR, İzes JK, Malcon MJ : Computerized tomographic appearance of hernias of the bladder. J Urol 1993; 149 : 1002-1005.
5. Pasquale MD, Shabahang M, Evans SRT : Obstructive uropathy secondary to massive inguinoscrotal bladder herniation. J Urol 1993; 190 : 1906-1908.
6. Thompson JE, Taylor JB, Nazarian N, Bennion RS : Massive inguinal scrotal hernias: a review of literature with two new cases. J Urol 1986; 136 : 1299-1231.
7. Curry N : Hernias of the urinary tract. In: Pollack HM (ed). Clinical urography. Philadelphia: Saunders Company. 1990: 2570-2577.
8. Watson LF : Hernia: Its Anatomy, Etiology, Symptoms, Differential Diagnosis, Prognosis and Treatment. 3rd ed. St. Louis: The CV Mosby Co: 1948 : 73-76.
9. Soloway HM, Portney F, Kaplan A : Hernia of the bladder. J Urol 1960; 84 : 539-541.
10. Gomella LG, Spires SM, Burton JM : The surgical implications of herniation of the bladder. Arc Surg 1985; 120 : 964-967.
11. Brown R, Griffiths VMT : Perforation of herniated bladder. Br J Urol. 1993; 71 : 102-103.
12. Robins SA : Hernia of urinary bladder: case report. AJR 1929; 22 : 353-354.
13. Reardon JV, Lowman RM : Massive herniation of the bladder: "the roentgen findings". J Urol 1967; 97 : 1019-1021.
14. Bell ED, Witherington R : Bladder hernias. Urology 1980; 15 : 127-130.
15. Redman JF, Williams EW, Meacham KR, Scriber LJ : The treatment of massive scrotal herniation of the bladder. J Urol 1973; 110 : 59-61.