

# ACCESSORY SLIP OF THE EXTENSOR CARPI RADIALIS LONGUS MUSCLE

## EXTENSOR CARPI RADIALIS LONGUS KASININ AKSESUAR TENDONU

N. Şimşek CANKUR, M.D., Senem TURAN ÖZDEMİR, M.D.

Uludağ University, Faculty of Medicine, Department of Anatomy, Bursa-Turkey  
Gazi Medical Journal 2003; 14: 197-199

**SUMMARY:** We report a rare variation of the extensor carpi radialis longus muscle, which was observed in a 49-year-old male cadaver during routine dissections. An accessory slip of the extensor carpi radialis longus muscle with a short belly part arising from the ulnar side and a long, thin tendon extending to the radial side of the wrist crossing over the main tendon was found and traced up to its insertion point on the dorso-lateral side of the first metacarpal bone. An embryologic explanation is proposed for this anatomic variation and its clinic importance is discussed.

**Key Words:** Extensor Carpi Radialis Longus Muscle, Variation.

**ÖZET:** Bu çalışmada, 49 yaşındaki bir erkek kadavranın disseksiyonu esnasında gözlemlediğimiz extensor carpi radialis longus kasına ait nadir bir varyasyonu rapor ettik. Ekstensor carpi radialis longus kasının, ulnar taraftan ayrılan kısa bir karın parçası ve kasın asıl tendonunu üstten çaprazlayan uzun ve ince bir tendonu olan bir aksesuar bölümü tespit edildi ve birinci metakarpal kemiğin radyal yüzü üzerindeki yapışma yerine kadar izlendi. Bu, anatomik varyasyonun embriyolojik gelişmesi irdelenerek klinik önemi tartışıldı.

**Anahtar Kelimeler:** M. Extensor Carpi Radialis Longus, Varyasyon.

### INTRODUCTION

The origin and insertion variations of the muscles and their tendons extending on the dorsal side of the hand have been well defined in anatomical and surgical studies (1-3). The variation incidence in the extensor compartments of the forearm reaches very high values, such as over 55% as defined by Jackson et al. (1). Extensor group muscles of the wrist have been studied in detail in humans and a large number of variations in the insertion of the extensor carpi radialis longus (ECRL) muscle are well described in the literature (4).

One of the superficial muscles with variational attachments is the ECRL. This muscle normally originates from the distal part of the lateral supracondylar ridge and the adjacent part

of the lateral intermuscular septum (5). Its tendon extends distally to the dorsal aspect of the metacarpal bone of the index finger. As a common abnormality, there may be some accessory slips extending to the first or third metacarpals. In cases of upper extremity reconstructions, ECRL is one of the preferable muscles because of the presence of other extensor muscles for the motion and dominance in its vascular structure (6, 7). It can be dissected as a pure muscle island and can be easily transposed to cover large defects in the ante-cubital area. Therefore, it is a useful and important muscle in tendon transfers for median or ulnar nerve palsies. Having some knowledge of the existence of such kinds of anatomical variations may be surgically useful in planning tendon repairs and/or transfers.

In the present study, we report an unusual variation of the ECRL muscle. An embryologic explanation is proposed for this anatomical variation and its clinical importance is discussed.

### CASE REPORT

During routine practical dissections of the forearm region for medical students, an unusual variation of the ECRL muscle was observed on the dorsal side of the right forearm of a 49-year-old male cadaver (Fig. 1). The ECRL muscle normally originates from the distal part of the lateral supracondylar ridge and the adjacent part of the lateral intermuscular septum. An accessory slip (tendo accessorius) of the ECRL muscle with a short belly part arising from the ulnar side and a long, thin tendon extending to the radial side of the wrist crossing over the main tendon was found and traced up to its insertion point on the dorso-lateral side of the first metacarpal bone. The other extensor muscles were normally situated on the dorso-lateral side of the wrist.

### DISCUSSION

In terms of embryological development, the upper extremity muscles originate from the migrating somitic mesoderm, whereas the tendons originate from the lateral mesodermal plate (8). In the early stages of embryological growth, the precursor extensor mass differentiates into the superficial, radial and deep

layers. Some external or internal factors may affect development during these embryological stages and may have negative effects on development, such as arrest, or resulting in abnormally shaped structures. This may explain the origin of the muscle variations. In contrast to our case, variations of superficial layer muscles were defined as less common than those of deep layer muscles (9). Yoshida reported a similar variation of ECRL in a study performed on 245 Japanese cadavers. He defined it as 1 of the 5 types of these tendons (10).

Several anatomic variations of the carpal extensor muscles have been described in a number of anatomical studies (1-4, 6, 10). Khaledpour and Schindelmeiser reported a case of a bicipital and bipennate accessory ECRL (11). Gümüşalan et al. described a case of an accessory extensor carpi radialis brevis muscle and a muscular bundle, connecting the extensor carpi radialis brevis and longus (3). The other additional muscles in the region of the radial extensor muscles were reported as extensor carpi radialis accessorius and extensor carpi radialis intermedius (12).

Claassen and Wree reported a case of an accessory tendon of the ECRL muscle with a route very similar to that in the case presented here (4). The only difference between these 2 cases concerned the insertion points of the

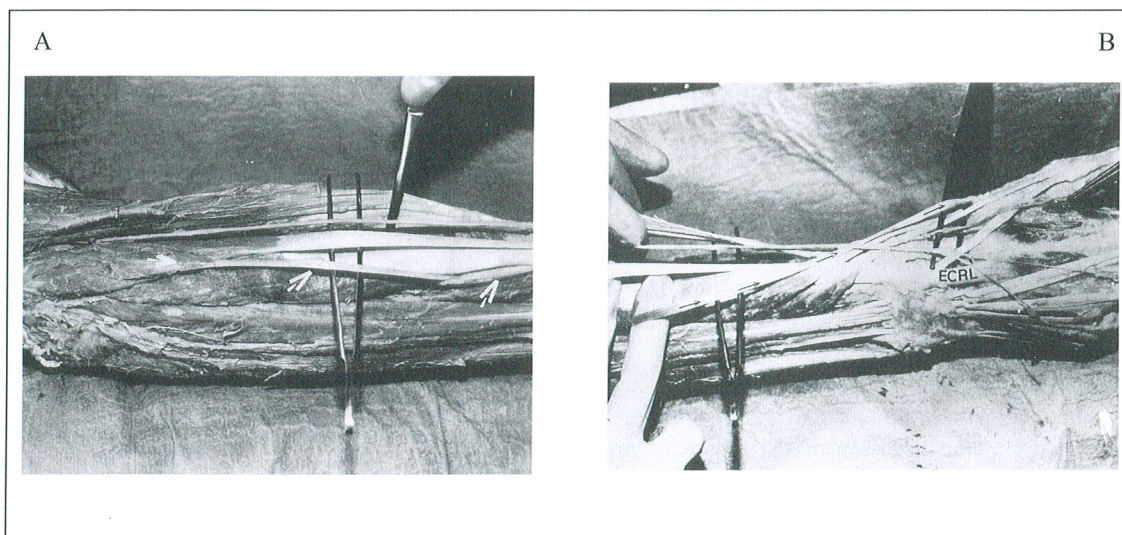


Fig. 1AB: The dorsal appearance of the forearm. The accessory head of the extensor carpi radialis longus muscle is indicated with an arrow (A). The dorsal appearance of the wrist and hand. The accessory slip of the extensor carpi radialis longus muscle is indicated with an arrow (B).

a: M. brachioradialis      b: M. extensor carpi radialis longus      c: M. extensor carpi radialis brevis      d: M. extensor digitorum  
e: M. abductor pollicis longus      f: M. extensor pollicis brevis



described tendons. In our case, it was inserted in the dorso-lateral side of the base of the first metacarpal bone, while in the other case it was inserted in the middle part of the same bone. The presented additional muscle slip had possibly functioned as an abductor pollicis muscle, similar to the case described by Claassen and Wree (4).

Although variations of the ECRL are common, detailed knowledge of individual variations is important in the diagnosis of certain diseases and in hand surgery. In all cases, especially in the distal regions of the upper extremity, the accessory muscles and supernumerary tendons should always be borne in mind as a valuable source for autograft tendon transfer operations when tendon reconstruction is required. Many types of tendon transfer techniques have been described for the restoration of thumb opposition failures (13). For instance, the tendon of the extensor carpi radialis brevis or longus can be used for opponensplasty. In addition, half of an ECRL tendon can be used as a graft (14). It can be split into 2 halves and cause no apparent loss of strength because of its appropriate thickness. In cases involving an accessory muscle bundle in the ECRL region, the surgeon has to be aware of its attachments and importance.

**Correspondence to:** N. Şimşek CANKUR, M.D.  
Uludağ Üniversitesi Tıp Fakültesi  
Anatomi Anabilim Dalı  
16059 BURSA - TÜRKİYE  
Phone : 224 - 442 92 42  
Fax : 224 - 442 83 13  
E-mail: [cankur@uludag.edu.tr](mailto:cankur@uludag.edu.tr)

## REFERENCES

1. Jackson WT, Viegas SF, Coon TM, Stimpson KD, Frogameni AD, Simpson JM. Anatomical variations in the first extensor compartment of the wrist. *J. Bone Joint Surg [Am]* 1986; 68: 923-926.
2. Abu-Hijleh MF. Extensor pollicis tertius: an additional extensor muscle to the thumb. *Plast Reconstr Surg* 1993; 92: 340-343.
3. Gümüşalan Y, Kalaycioglu A, Yazar F, Arifoglu Y, Sinav A. Accessory extensor carpi radialis muscle and interconnecting muscle bundle. *Acta Anat* 1997; 159: 57-60.
4. Claassen H, Wree A. Multiple variations in the region of mm. extensores carpi radialis longus and brevis. *Ann Anat* 2002; 184: 489-91.
5. Williams PL, Warwick R, Dyson M, Bannister LH. *Gray's Anatomy*. 37th ed. London: Churchill Livingstone; 1989. p. 612-622.
6. von Schroeder HP, Botte MJ. Anatomy of the extensor tendons of the fingers: variations and multiplicity. *J Hand Surg [Am]* 1995; 20: 27-34.
7. Janevicius RV, Greager JA. The extensor carpi radialis longus muscle flap for anterior elbow coverage. *J Hand Surg [Am]* 1992; 17: 102-106.
8. Moore KL, Persaud TVN. *The developing human, clinically oriented embryology*. 6th ed. Philadelphia: WB Saunders; 1998. p. 426-428.
9. Gschwend N. Anatomische varianten von muskeln und sehnen der hand, *Handchir Mikrochir Plast Chir* 1987; 19: 244-247.
10. Yoshida Y. Anatomical studies on the extensor carpi radialis longus and brevis muscles in Japanese. *Okajimas Folia Anat Jpn* 1994; 71: 127-135.
11. Khaledpour C, Schindelmeiser J. Atypical course of the rare accessory extensor carpi radialis muscle. *J Anat* 1994; 184: 161-163.
12. Albright JA, Linburg RM. Common variations of the radial wrist extensors. *J Hand Surg [Am]* 1978; 3: 134-138.
13. Baek GH, Jung JM, Yoo WJ, Chung MS. Transfer of extensor carpi radialis longus or brevis for opponensplasty. *J Hand Surg [Br]* 1999; 24: 50-53.
14. Malaviya GN. Radial half of extensor carpi radialis longus tendon as graft to elongate muscle tendon unit for correction of finger clawing. *Plast Reconstr Surg* 2003; 111: 1914-1917.