

ANAL INCONTINENCE AFTER A DOG BITE TREATED BY NEOSPINCTER FORMATION WITH THE GLUTEUS MAXIMUS TRANSPOSITION FLAP: REPORT OF A CASE

KÖPEK ISIRMASI SONRASI GELİŞEN ANAL İNKONTİNANS VAKASINDA GLUTEUS MAKSİMUS TRANSPOZİSYON FLEBİ İLE NEOSFİNKTER OLUŞTURULMASI: OLGU SUNUMU

B.Bülent MENTEŞ, M.D., Yakup SARIGÜNEY, M.D., Kenan YUSİFZADE, M.D.,
Mehmet OĞUZ, M.D., Erdal YILMAZ, M.D.

Gazi University, Faculty of Medicine, Department of From the Colorectal Surgery Unit, Ankara-Turkey

Gazi Medical Journal 2003; 14: 143-146

SUMMARY: A case of traumatic anal incontinence after a dog bite is described. The patient had the worst possible score of anal incontinence, and an anal manometric study failed to note any pressure patterns. The patient was treated by surgical neosphincter construction with the gluteus maximus transposition flap. Two symmetrical muscle bundles were detached from the sacrococcygeal junction, split into two equivalent portions, and rotated inferiorly to surround the anal canal anteriorly and posteriorly. No postoperative complications were noted, and four months after the operation, the patient had improved significantly (anal incontinence score 6).

Key Words: Anal Incontinence, Anorectal Injury.

INTRODUCTION

Of the various reasons for anal incontinence, sphincter injuries due to obstetric or iatrogenic trauma are the leading ones, and they usually result from difficult and/or instrumental vaginal deliveries or anorectal surgery (hemorrhoidectomy, sphincterotomy, fistulotomy, etc.) (1). Other traumatic factors that may lead to anal incontinence, such as insertion of foreign bodies or deviant sexual practices, are interesting but uncommon causes (1, 2). Here, we report a case of traumatic anal incontinence after a dog bite that was successfully treated with neosphincter formation with the gluteus maximus transposition muscle flap.

ÖZET: Köpek ısırması sonrası bir travmatik anal inkontinans vakası anlatılmıştır. Hastada olası en kötü anal inkontinans skoru bulunmuş olup anal manometrik değerlendirme yapılamamıştır. Hasta gluteus maksimus transpozisyon flep rekonstrüksiyon ile tedavi edilmiştir. Hazırlanmış iki simetrik kas flebi sakrokosigeal bileşim yerinden ayrıldı, iki eşdeğer parçaya disseke edilerek aşağı kaydırıldı ve anal kanal ön ve arka planlarda sarıldı. Posoperatif dönemde herhangi bir komplikasyon olmadı ve operasyondan 4 ay sonra anlamlı iyileşme tespit edildi (anal inkontinans skoru 6).

Anahtar Kelimeler: Anal İnkontinans, Anorektal Hasar.

REPORT OF A CASE

A 47-year-old woman was admitted for complete anal incontinence to gas and solid and liquid stools. She had been bitten by a dog when she was six years old, and an urgent operation had been carried out for this anal/perineal injury. We had no details of this operation, but a colostomy had not been performed and a long and troublesome postoperative course had followed the operation. Postoperatively, the patient had become incontinent to gas and fluid stools, and this had led to severe depression and social isolation in the urban region in which she lived. For the same reasons, she never went to school or sought specialist help. Years later, when she was 40 years old, a Thiersch procedure was

performed at a state hospital for anal incontinence. The encirclement wire had to be removed a week later because of infective complications, and the patient became even worse. The incontinence score according to Jorge and Wexner's classification (3) was 20 (the highest possible score).

On physical examination, extensive scarring was noted around the patulous anus with no baseline tonus or voluntary contraction (Fig. 1). An anal manometric study failed to note any pressure patterns. An ultrasonographic examination had to be performed transvaginally, and it revealed almost complete loss of the sphincter muscles with patches of external sphincter on the left side. The other physical examination and routine laboratory investigation findings were unremarkable.

Under epidural anesthesia and in a prone jackknife position, two symmetrical linear incisions were made, corresponding to the projection of the lower edge of the gluteus maximus muscle and extending from the ischial tuberosity to the sacrococcygeal junction on both sides. The dissection was deepened to expose the lower portion of the gluteus maximus muscle, and a bundle of the muscle, 4-5 cm in width, was dissected from the main body, taking care not to injure its neurovascular supply (Fig. 2a). This bundle was detached from the sacrococcygeal junction and split into two equivalent portions (Fig. 2b). Again symmetrically, two lateral circumanal incisions were made and deepened to

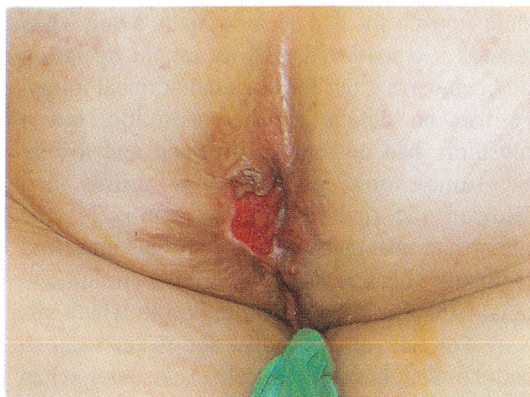

Fig. 1: Extensive scarring around the patulous anus with no baseline tonus or voluntary contraction.

form tunnels for the transposition of the muscle flaps. The muscle flaps were then rotated inferiorly to pass the tunnels and surround the anal canal anteriorly and posteriorly. With the help of additional small anterior and posterior incisions, the two ends of the transposed muscle bundles were sutured to each other to form two opposing muscular slings (Fig. 2c). A protective colostomy was not performed. Suction drains were placed, and the incisions were closed primarily. The postoperative course was uneventful with no infective or other complications. Four weeks later, biofeedback therapy was started.

Four months after the operation, the patient declared gas and some liquid incontinence, but she was continent to solid stools (incontinence score 6). Anal manometry revealed a resting pressure of 25 and squeeze pressure of 55 mmHg. Transvaginal ultrasound demonstrated the muscle wrap around the anal canal (Fig. 3a, b).

DISCUSSION

Apart from the common obstetric and other types of iatrogenic anorectal injuries, the anorectum is infrequently affected by gunshot or stab wounds. Other causes of anorectal injury are interesting from the perspective of forensic medicine but extremely rare. For example, criminal assault with knives or other weapons may target the rectum (4). Intrarectal tear from water skiing is another extreme example that has been reported (5). To our knowledge, anorectal injury and traumatic anal incontinence due to a dog bite or any other animal assault has not been reported before. It is certain in our case that the lack of a proper surgical consultation and care after the trauma had contributed negatively to the course of the patient. In our opinion, the delayed attempt at repair in the form of a Thiersch procedure was also a bad choice, and it proved unsuccessful. At the end, all the patient had left were scarce patches of external sphincter that were barely noticeable by ultrasound. Because there was not sufficient sphincter to be repaired or rehabilitated, sphincter reconstruction was mandatory.

Various techniques have been defined for anal incontinence in the literature, and all of them contain some advantages and disadvantages. Sphincter repair techniques (direct apposition,

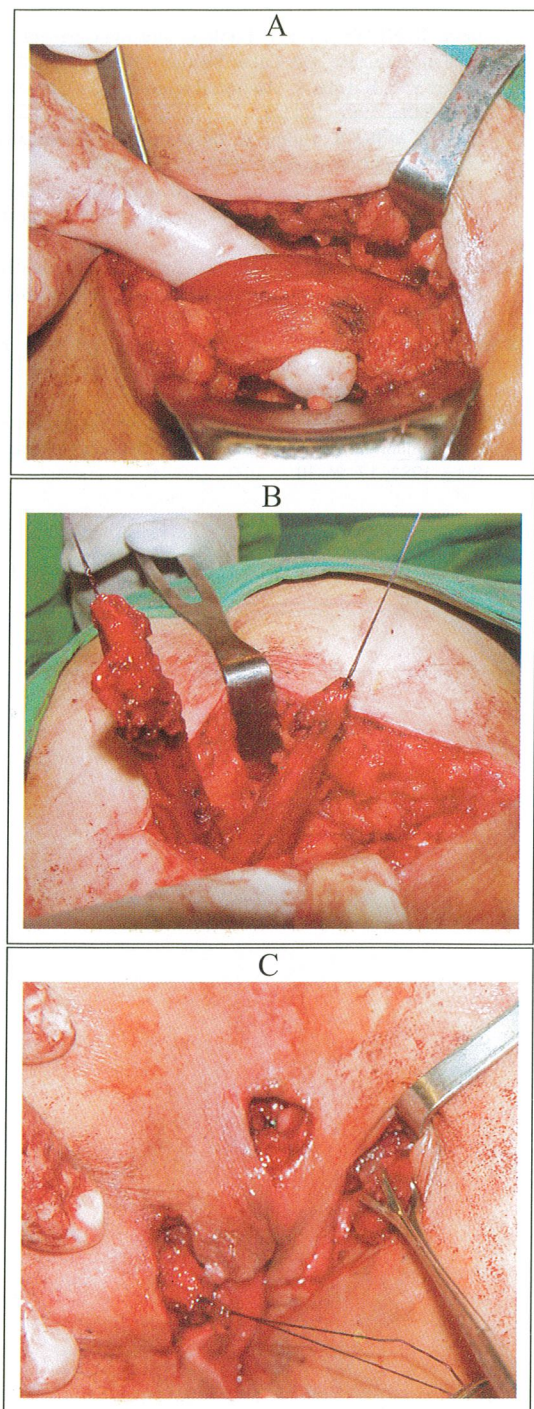


Fig. 2: Two symmetrical linear incisions were made, corresponding to the projection of the lower edge of the gluteus maximus, and a bundle of the muscle, 4-5 cm in width, was dissected from the main body, taking care not to injure its neurovascular supply (A), this bundle was detached from the sacrococcygeal junction and split into two equivalent portions (B), and the muscle flaps were then rotated inferiorly to pass the tunnels and surround the anal canal anteriorly and posteriorly. The two ends of the transposed muscle bundles were sutured to each other to form two opposing muscular slings (C).

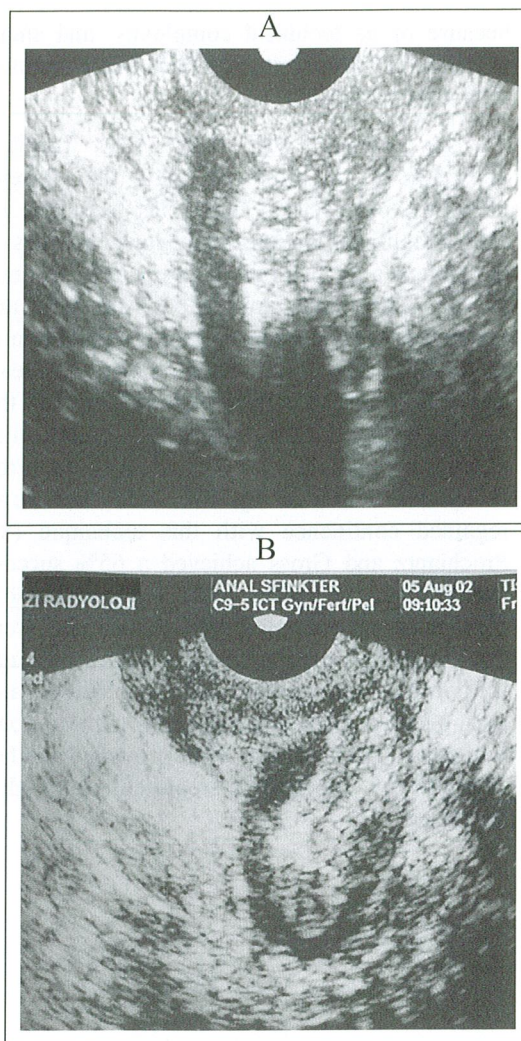


Fig. 3: Transvaginal ultrasound of the anal sphincters demonstrated an almost complete loss of the sphincter muscles preoperatively (A), and the complete muscle wrap around the anal canal postoperatively (B).

plication procedures, overlapping repair), encirclement procedures (muscle transfer, synthetic material) and fecal diversion can be used in selective patients depending on the degree of anal sphincter injury. Neosphincter formation using muscle transfer has become a current issue in serious anatomic sphincter deformation. Dynamic graciloplasty is technically demanding and associated with high morbidity. In addition, the necessity for long-term muscle stimulation is another disadvantage. The sartorius muscle appears to be less well suited because of its segmental vascularization, which restricts the arch of rotation when the muscle is transposed. Nevertheless, free muscle transfer has never gained widespread popularity

because of its technical complexity, and small numbers of clinical studies have been reported with various results (1).

This patient was treated by surgical neosphincter construction with the gluteus maximus transposition flap. This technique of muscle transposition utilizes the lower bundles of the gluteus maximus muscle to encircle the anus (1, 6). The nerve and blood supplies are preserved, and therefore no motor stimulation is required. Of the seven cases reported by Pearl and coworkers, six were able to control the passage of liquid stools and one was continent to gas, postoperatively (7). Likewise, four out of the six patients treated by Yuli and Xuenheng regained continence with this technique (8). Prochiantz and Gross achieved a 65% success rate after 15 operations (9). In a considerable number of patients, diverting colostomies were used, and the major concern has been the high incidence of postoperative infection. Without any postoperative complications and with a good functional outcome, our case provided another example of successful treatment with this technique.

3. Jorge JMN, Wexner SD. Etiology and management of fecal incontinence. *Dis Colon Rectum* 1993; 36: 77-97.
4. Eckert WG, Katchis S. Anorectal trauma. *Am J Forensic Med Pathol* 1989; 10: 3-9.
5. Lee RY, Miller S, Thorpe C. Intrarectal tear from water skiing. *Am J Gastroenterol* 1992; 87: 662-663.
6. Hentz VR. Construction of a rectal sphincter using the origin of the gluteus maximus muscle. *Plast Reconstr Surg* 1982; 70: 82-85.
7. Pearl RK, Prasad ML, Nelson RL, Orsay CP, Abcarian H. Bilateral gluteus maximus transposition for anal incontinence. *Dis Colon Rectum*. 1991; 34: 478-481.
8. Yuli C, Xueheng Z. Reconstruction of rectal sphincter by transposition of gluteus muscle for fecal incontinence. *J Pediatr Surg*. 1987; 22: 62-64.
9. Prochiantz A, Gross P. Gluteal myoplasty for sphincter replacement: Principles, results and prospects. *J Pediatr Surg*. 1982; 17: 25-30.

Correspondence to: B. Bülent MENTEŞ, M.D.
Gazi Üniversitesi Tıp Fakültesi
Genel Cerrahi Anabilim Dalı
Beşevler
06510 ANKARA - TÜRKİYE
Phone: 312 - 215 35 15
Fax: 312 - 223 05 28
e-mail: bmentes@gazi.edu.tr

REFERENCES

1. Rotholtz NA, Wexner SD. Surgical treatment of constipation and fecal incontinence. *Gastroenterol Clin North Am* 2001; 30: 131-165.
2. Fallon WF. Wounds, foreign bodies, and fecal impaction. In: Zuidema GD and Condon RE (eds). *Shackelford's Surgery of the Alimentary Canal*. WB Saunders, Philadelphia 1996; 21-31.