

CASE REPORTS

COLONIC TUBERCULOSIS AS A DIAGNOSTIC CHALLENGE: REPORT OF A CASE

BİR TANİ KARMAŞASI OLARAK KOLONİK TÜBERKÜLOZ: OLGU SUNUMU

Kenan Yusuf ZADE, M.D., Barış BAĞBANCI, M.D., Arzu DEMİRTOLA, M.D.,
B.Bülent MENTEŞ, M.D., Ayşe DURSUN*, M.D., Mehmet OĞUZ, M.D.,
Erdal YILMAZ, M.D.

Gazi University, Faculty of Medicine, Departments of Colorectal Surgery Division and Pathology*,
Ankara-Turkey
Gazi Medical Journal 2003; 14: 127-129

SUMMARY: Gastrointestinal tuberculosis may be a diagnostic challenge, particularly in the absence of evidence of pulmonary infection. It may mimic other abdominal diseases, such as other infectious processes, tumors or Crohn's disease. Colonoscopic examinations have not always been used successfully to diagnose the disease either. In the absence of specific laboratory/radiological findings, the diagnosis can be established only by histopathological examination of the specimen. Therefore, as suggested previously, isolated colonic tuberculosis may be a diagnostic challenge even in the era of modern surgery, as exemplified in this case report.

Key Words: Colonic Tuberculosis, Surgery, Colorectal Carcinoma.

INTRODUCTION

Colonic tuberculosis is a rare granulomatous disease of the bowel in Western countries (1, 2), while it is endemic in developing countries such as India (1-3). Gastrointestinal (GI) tuberculosis may be a diagnostic challenge, particularly in the absence of evidence of pulmonary infection. It may mimic other abdominal diseases, such as other infectious processes, tumors or Crohn's disease (1, 4). In the absence of positive laboratory and radiological tests, the diagnosis is often established definitively by examination of the surgical specimen. Its radiological findings are often difficult to differentiate from those of other diseases. Colonoscopic examination has not always been used successfully to diagnose the

ÖZET: Gastrointestinal tüberkülozu tanısı, pulmoner enfeksiyon kanıtları olmaksızın zor bir tanıdır. Enfeksiyöz prosesler, tümörler ve Crohn hastalığı gibi diğer pek çok abdominal patolojiyi taklit edebilir. Kolonoskopik değerlendirme bile tanının konulmasında her zaman çok başarılı olamamaktadır. Tüberkülozun spesifik laboratuvar ve radyolojik bulguları olmaksızın tanı, ancak spesimenin histopatolojik incelemesi ile konulabilir. Tüm diagnostik testlerle dahi kolonik tüberküloz tanısı bu olgu sunumunda örneklendirildiği gibi zor olabilmektedir.

Anahtar Kelimeler: Kolonik Tüberküloz, Cerrahi, Kolorektal Karsinoma.

disease either. Thus, most patients undergo exploratory laparotomy. The patient reported here exemplifies another rare case of isolated colonic tuberculosis that could not be diagnosed definitively in spite of a detailed preoperative evaluation.

CASE REPORT

A 41-year-old man was admitted with complaints of abdominal pain, fatigue, and weight loss. The patient had a two-year history of intermittent abdominal pain attacks, and, two weeks before admission, the pain had become continuous with the addition of weight loss (about 5 kg in two weeks) and permanent fatigue. His medical history was otherwise unremarkable. On physical examination, a mass lesion could be

palpated in the lower right quadrant of the abdomen. The laboratory analysis of the blood, including CEA, was normal, and serology for HIV was negative. A barium enema revealed a mass lesion (Fig. 1A) in the cecum, obliterating the lumen and concordant with colon carcinoma (Fig. 1B). In colonoscopy, a mass lesion possibly from outside the lumen and with a normal mucosal lining was found to obliterate the proximal right colon (Fig. 2). Proximal to this mass lesion, noduloulcerative lesions with surrounding erythematous mucosa could be seen. Because we could not pass the colonoscope behind the stricture, we could not obtain biopsies or examine the ileocecal region. Colonic tuberculosis was thought to be an alternative diagnosis, but neither the chest X-ray nor the PPD test (11 mm) was suggestive.

The patient underwent laparotomy. A bulky

tumoral lesion surrounded densely by the omentum was noted. A definitive differential diagnosis was still impossible, and an extended right colectomy en-bloc with the adhering omentum and ileocolic anastomosis was performed. The postoperative course was uneventful. The resected specimen revealed an ulcerative lesion 7 x 6.5 cm in size in the cecum. A histopathological examination demonstrated epithelioid cell granulomas with Langerhans type giant cells in the mucosa and submucosa of the colon and paracolic lymph nodes (Fig. 3). Caseous necrosis of some granulomas and acid-fast bacilli were also found. The patient was discharged from the hospital on the 6th postoperative day without any complications, and was commenced on antituberculous therapy, which is currently continuing.

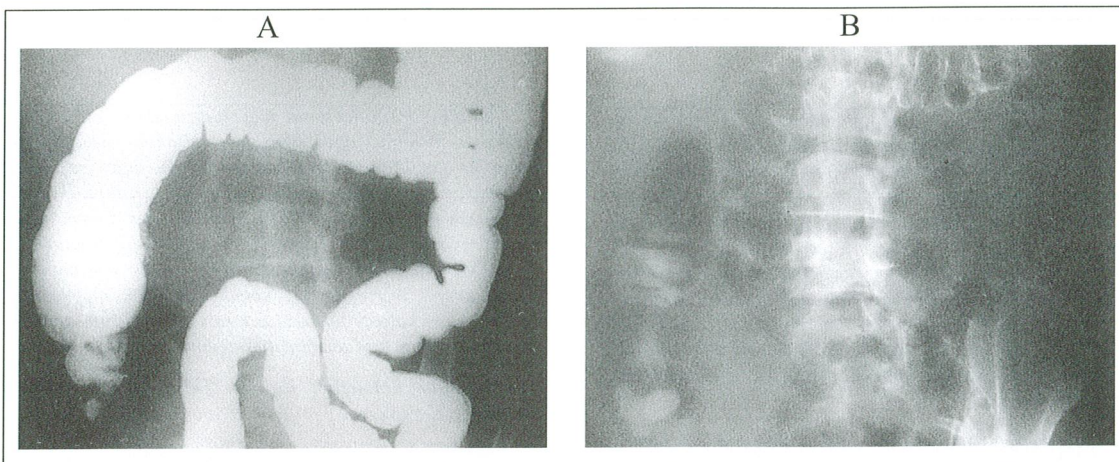


Fig. 1: Radiological view of the right colon (A). Radiological view of the cecal segment of the colon (B).

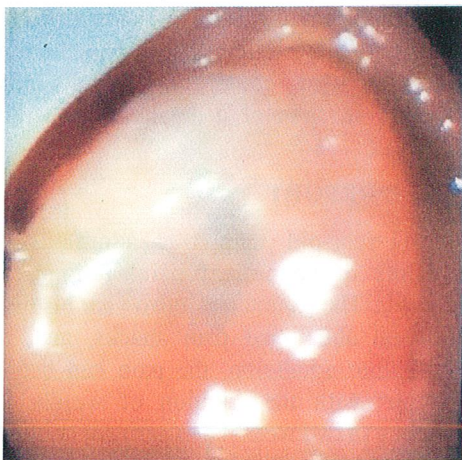


Fig. 2: Colonoscopic view of the ulcerative lesion of the cecum.

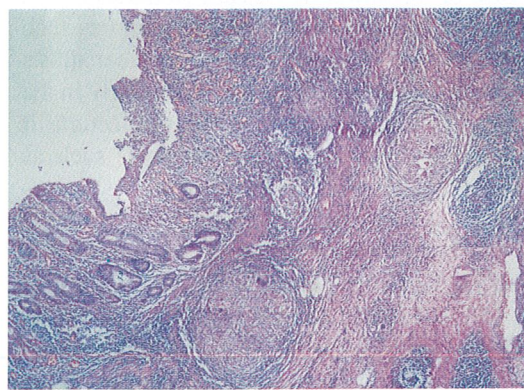


Fig. 3: The base of the ulcerative lesion with necrotizing granulomas (H & E x 40).

DISCUSSION

The small bowel and ileocecal segment of the bowel are the most common sites of tuberculous involvement of the gastrointestinal tract (5-7). Isolated involvement of the colon represents the next most common site of gastrointestinal tuberculosis, with the reported incidence of colonic involvement ranging from 3 to 12% (5-7). Colonic tuberculosis can present in several forms. The most common involvement is in the form of segmental ulcers and colitis, inflammatory strictures and hypertrophic lesions resembling polyps or masses, as in the present case (1, 6, 7). The hypertrophic form causes a diagnostic dilemma at the time of surgery because it mimics colonic carcinoma (6).

Colonoscopy is a non-invasive procedure that provides much information about the areas and nature of involvement and facilitates biopsy collection. Colonoscopic findings of nodular, noduloulcerative or ulcerative lesions with erythematous surrounding mucosa and thickened edematous ileocecal valve are suggestive of tuberculosis (1, 7). In patients with suspicious clinical symptoms, the histopathological verification of the percutaneous aspiration and biopsy, laparoscopy and colonoscopic biopsies plays a major role in the establishment of a definitive diagnosis (4, 8, 9). In the present case, it was impossible to take biopsies during the colonoscopy because of stricture of the acendoccecal segment of the colon. The colonoscopic findings and radiological views were largely suggestive of colon carcinoma and the patient was treated by extended right hemicolectomy according to oncological principles. In patients with established intestinal tuberculosis, antituberculous chemotherapy is indicated initially (2). On the other hand, patients with occluding lesions or complications of tuberculous ulcers such as perforation or bleeding are candidates for surgical resection (10-12).

In conclusion, the patient reported here exemplifies another rare case of isolated colonic tuberculosis that could not be diagnosed definitively in spite of a detailed preoperative evaluation. In the absence of specific laboratory/radiological findings, the diagnosis could be established only by a histopathological examination of the specimen. Therefore, as suggested previously (1, 4-6), isolated colonic

tuberculosis may be a diagnostic challenge, even in the era of modern surgery.

Correspondence to: B. Bülent MENTEŞ, M.D.
Gazi Üniversitesi Tıp Fakültesi
Genel Cerrahi Anabilim Dalı
Beşevler
06510 ANKARA - TÜRKİYE
Phone: 312 - 202 57 47
Fax: 312 - 223 05 28

REFERENCES

1. Singh V, Kumar P, Kamal J, Prakash V, Vaiphei K, Singh K. Clinicocolonoscopy profile of colonic tuberculosis. *Am J Gastroenterology* 1996; 91: 565-568.
2. Das HS, Rathi P, Chodankar CM, Vyas K, Patrawala V, Dhadphale S. Colonic tuberculosis: colonoscopic appearance and clinico-pathologic analysis. *J Assoc Physicians India* 2000; 48: 708-710.
3. Gupta NM, Motup T, Joshi K. Isolated colonic tuberculosis perforation as a rare cause of peritonitis: report of a case. *Surg Today* 1999; 29: 273-275.
4. Naga MI, Okasha HH, Ismail Z, El-Fatary M, Okasha SH, Monir BE. Endoscopic diagnosis of colonic tuberculosis. *Gastrointest Endosc*, 2001; 53: 789-793.
5. Chaudary A, Gupta NM. Colorectal tuberculosis. *Dis Colon Rectum* 1986; 29: 738-741.
6. Devanesan JD, Sable RA, Pitchumoni CS, Lev R, Zapiach L. Segmental tuberculosis of the colon mimicking carcinoma. *Arch Surg* 1980; 115: 90-91.
7. Bhargava DK, Kushwah AKS, Dasarathy S, Shrinivas, Chopra P. Endoscopic diagnosis of segmental colonic tuberculosis. *Gastrointest Endosc* 1992; 38: 571-574.
8. Wong SS, Chow E. Endoscopic diagnosis of colonic tuberculosis: unusual presentation with two colonic strictures. *Endoscopy* 1996; 28: 783.
9. Akgün Y, Yılmaz G, Taçyıldız İ. Intestinal and peritoneal tuberculosis. *Turkish J Trauma Emergency Surg* 2002; 8: 43-48.
10. Bromberg SH, Faroud S, Castro FF, Morrone N, de Codoy AC, Franca LC. Isolated ileocecal tuberculosis simulating malignant neoplasia and Crohn's disease. *Rev Assoc Med Bras* 2001; 47: 125-128.
11. Kacem C, Kamoun A, Bahout M, Zermani R, Najjar T, Zaouche A. Colonic tuberculosis: an exceptional cause of a massive surgical hemorrhage apropos of a case and review of the literature. *Tunis Med* 1999; 77: 530-533.
12. Bannura G, Valencia C, Fernandez W. Colonic perforation secondary of ileocecal tuberculosis. Report of one case. *Rev Med Chil* 1999; 127: 704-708.