

# ROLE OF INTERFERON-ALPHA 2B AND OCTREOTIDE IN PREVENTION OF EXPERIMENTALLY INDUCED CORNEAL NEOVASCULARIZATION IN RATS

## RATLARDA DENEYSEL OLARAK İNDÜKLENEN KORNEA NEOVASKÜLARİZASYONUNUN ÖNLENMESİNDE İNTERFERON-ALFA 2B VE OKTRETİDİN ROLÜ

Tamer DEMİR, M.D., Fatih ULAŞ, M.D., Ülkü ÖZKAYA ÇELİKER, M.D.

Fırat University Faculty of Medicine, Department of Ophthalmology, Elazığ-Turkey  
Gazi Medical Journal 2003; 14: 115-121

### ABSTRACT

**Purpose:** To investigate the effects of interferon-alpha2b (IFN- $\alpha$ 2b) and octreotide, a long-acting analogue of somatostatin, on experimentally induced corneal neovascularization. **Methods:** Chemical keratitis was induced unilaterally in the eyes of 30 rats by silver nitrate cauterization. Ten of these animals received subcutaneous IFN- $\alpha$ 2b (250,000 IU) four times every other day (interferon group) and ten rats were injected with octreotide (10  $\mu$ g) (octreotide group). The remaining ten rats were used as controls. The corneas of all animals were biomicroscopically and histopathologically examined on day 8 by electron microscope to observe whether there was inhibition of neovascularization or not. **Results:** Corneal neovascularization and histopathological scores were lower in both the interferon group ( $p < 0.005$ ) and the octreotide group ( $p < 0.001$ ) compared to the controls. These parameters were lower in the octreotide group compared with the interferon-injected rats ( $p < 0.05$ ). **Conclusion:** We suggest that the application of both IFN- $\alpha$ 2b and octreotide is effective in the inhibition of corneal neovascularization and these preventive effects were more significant in the latter group.

**Key Words:** Alpha Interferon, Corneal Neovascularization, Octreotide.

### INTRODUCTION

Corneal neovascularization resulting in vision loss is an important problem for both patients and physicians. Neovascularization of the cornea with recurrent epithelial erosion and inflammation may cause significant clinical symptoms, and vision may be lost as a result (1).

### ÖZET

**Amaç:** Bu çalışmanın amacı interferon-alfa2b (IFN- $\alpha$ 2b)'nin ve uzun etkili somatostatin analogu olan oktreotidin, deneysel olarak uyarılan kornea neovaskülarizasyonu üzerine etkilerini araştırmaktır. **Metod:** Gümüş nitrat koterizasyon ile 30 ratın birer gözünde kimyasal keratit oluşturuldu. Denekler rastgele onarlı üç gruba ayrılarak bir gruba günde dört kez subkütan IFN- $\alpha$ 2b (250.000 IU), diğer gruba oktreotid (10 $\mu$ g) injeksiyonu yapıldı. Geri kalan grup ise kontrol grubu olarak çalışmaya dahil edildi. Tüm deneklerin korneaları sekizinci günde biomikroskopik ve histopatolojik olarak elektron mikroskopu ile neovaskülarizasyonun önlenip önlenemediği konusunda değerlendirildi. **Bulgu:** Bu çalışmada kornea neovaskülarizasyonu ve histopatolojik skorlar hem IFN ( $p < 0,005$ ), hem de oktreotid ( $p < 0,001$ ) gruplarında kontrol grubu ile karşılaştırıldığında daha düşük bulundu. Oktreotid grubunda bu parametreler IFN grubuna göre daha düşük olarak saptandı ( $p < 0,05$ ). **Sonuç:** Sonuç olarak, IFN- $\alpha$ 2b ve oktreotidin kornea neovaskülarizasyonunun önlenmesinde etkili olduğunu düşünmekteyiz. Bu etki oktreotid grubunda daha belirgin olarak saptandı.

**Anahtar Kelimeler:** Alfa İnterferon, Kornea Neovaskülarizasyonu, Oktreotid.

It is known that interferons inhibit angiogenesis and mediate cell differentiation (2). IFN- $\alpha$ 2b, applied subcutaneously to prevent cornea neovascularization, gives good results (3). It was reported that growth factors have a stimulating effect on a number of tissues (4). As octreotide, a long-acting analogue of somatostatin, has inhibitory effects on growth factors, the potential

inhibitory role of octreotide on neovascularization may be taken into consideration (5, 6).

This study was set up as a preliminary study to investigate the effect of octreotide on experimentally induced corneal neovascularization.

### MATERIALS AND METHODS

This study was carried out on unilaterally cauterized eyes of 30 Wistar Albino rats (of either sex weighing 150 to 200 g). All animals in this study were used in accordance with the rules approved by the Firat Medical Center Hospital Animal Care and Use Committee and in accordance with the Association for Research in Vision and Ophthalmology.

The rats were randomly divided into three groups of 10 rats: control, interferon and octreotide groups. The rats were anesthetized with intramuscularly administered ketamine hydrochloride (25 mg/kg) (Ketalar, Park-Davis CO, Morris Plains, NJ, USA) and xylazine hydrochloride (3 mg/kg) (Rompun, Mobay Corp, Shownee, KS, USA). One eye of the animals was concurrently anesthetized by instillation of 0.5% proparacaine hydrochloride (Alcon, Humacao, Puerto Rico) (7) for manipulation. Anterior segments of all the rats were photographed before forming the corneal burn with the intention of indexing the normal corneal and iris structure of the rats.

Unilateral chemical keratitis was formed by applying a silver nitrate applicator stick (San Jose Surgical Supply) for 5 seconds onto a central circular area 1.8 mm in diameter on the all rats' eyes (3). Octreotide (10 µg) (Sandostatin, Sandoz Pharma, Basel, Switzerland) was subcutaneously

applied three times a day at 8 hour intervals in the octreotide group (n=10). Four times every other day, IFN-α2b (250,000 IU) (Intron-A, Schering Corp, Kenilworth, NJ, USA) was subcutaneously applied to the interferon group (n=10) immediately on the same day. No treatment was applied to the control group (n=10).

On the 8th day after the chemical cauterization, administering the same anesthetics, corneal neovascularization was evaluated by a method similar to that described by Mahoney and Waterbury [3] under a slit lamp microscope with a camera mounted on it. Accordingly, the corneas on the photographs were divided into 5 circular areas encircling each other and the circular areas were numbered from the periphery to the center of the cornea on which there was an opaque white lesion approximately 2 mm in diameter formed by silver nitrate cauterization. The grading of neovascularization was carried out according to the presence or absence of blood vessels within each circular area. The average corneal neovascularization scores of eyes were unilaterally obtained for each rat. The scoring procedures were carried out in a blinded manner.

The burn stimulus was graded according to the height of the blister formed and the scoring of neovascularization was determined with regard to the most proximal circular area (to the center of the cornea) showing circumferential vascular invasion. Accordingly, burn stimulus grade and corneal neovascularization scores are shown in tables 1 and 2, respectively. After scoring the burn stimulus and neovascularization the animals were killed with an overdose of systemically administered pentobarbital sodium (Somnlethal, JA Webster, Billerica, MA, USA). The corneas of freshly enucleated eyes were immediately

Table- 1: Burn Stimulus Grade.

Grade 0	Darkened cauterized area, not raised above corneal surface
Grade 1	White opaque blister raised slightly above corneal surface
Grade 2	Blister raised moderately above corneal surface
Grade 3	Large blister raised definitely above corneal surface

Table- 2: Neovascularization Grade.

Grade 0	No neovascularization visible
Grade 1	Neovascular growth on the circular area 1/5 the distance to the burn
Grade 2	Neovascular growth on the circular area 2/5 the distance to the burn
Grade 3	Neovascular growth on the circular area 3/5 the distance to the burn
Grade 4	Neovascular growth on the circular area 4/5 the distance to the burn
Grade 5	Neovascular growth on the circular area 5/5 the distance to the burn

excised along the limbus and were fixed in 2.5% glutaraldehyde in 0.1 M sodium phosphate buffer (pH 7.4) for 72 hours, and each cornea was dissected into 4 longitudinal pieces (2x3x0.5 mm) from limbus to limbus so that every longitudinal piece included a part of each circular area. Four longitudinal pieces (2x3x0.5 mm) from each cornea were postfixed in 2% osmium tetroxide in 0.1 M sodium phosphate buffer for one hour, dehydrated in graded alcohol, propyleneoxide and embedded in Araldite CY 212. Sections were cut on a LKB ultratome. Thick sections (1 micron) were stained with toluidine blue and inspected by light microscope. Then ultrathin sections (600A) were stained with uranyl acetate and lead citrate and examined on a transmission electron microscope (Zeiss EM 952). For light microscopy, paraffin blocks were prepared from corneas that were dehydrated in a graded alcohol series and sections of 5 mm thickness were stained with Hematoxylin-eosin. A BH-2 Olympus photomicroscope was used for the examination. A light microscopic examination was performed on every microscopic section, prepared from the periphery to the center of each cornea and evaluated with regard to the intensity of polymorphonucleated leukocyte, edema and fibroblastic activity and scored from grade 0 to grade 3. Grade 0: no change, grade 1: mild degree, grade 2: moderate degree, grade 3: severe degree [3]. Average scores for every cornea were calculated from the total of all microscopic sections of the corneas. Average histopathologic scores of the eyes were obtained for each rat.

The results are expressed as means  $\pm$  SEM and statistical analyses were carried out using the Mann-Whitney U test. P values  $<$  0.05 are considered statistically significant.

## RESULTS

Levels of burn induction in all groups were observed to be similar (+3). Mean neovascularization scores were  $4.6 \pm 0.54$  in the

control group,  $3.2 \pm 0.44$  in the interferon group and  $2.3 \pm 0.83$  in the octreotide group. Average histopathologic scores were  $2.3 \pm 0.67$  in the control group,  $1.5 \pm 0.54$  in the interferon group and  $1.0 \pm 0.70$  in the octreotide group. When the interferon and control groups were compared, it was observed that the corneal neovascularization and histopathologic scores of the interferon group were significantly lower than those of the control group ( $p < 0.005$ ,  $p < 0.005$ , Table 3). The corneal neovascularization and the histopathologic scores of the octreotide group were also significantly lower than those of the control group ( $p < 0.001$ ,  $p < 0.001$ , Table 3). It was also observed that corneal neovascularization and histopathologic scores of the octreotide group were significantly lower than those of the interferon group ( $p < 0.005$ ,  $p < 0.005$ , Table 3).

Under the light microscope, it was observed that the cells of the corneal epithelium that had undergone chemical burn had lost their integrity and showed edema and vacuolization. The basement membrane under this epithelium lost its continuity and the Bowman membrane was absent. Instead, keratocytes became dense in these regions. The stroma was observed to be edematous (Fig. 1a). The epithelium in the neighborhood of the burned area was observed to have kept its integrity. However, newly formed vascular structures, activated keratocytes and various polymorphonucleated leukocytes were observed in the stroma all over this region (Fig. 1b). Although the vascularization and PNL infiltration were lower in similar regions of the octreotide and interferon groups when compared with the control group (Fig. 1c, 1d), the vascular elements in the stroma of the octreotide group were fewer than those in the other groups (Fig. 1d).

The electron microscopic evaluation revealed that the epithelium in the burned area was destroyed and degenerated (Fig. 2a) and newly formed blood vessels, keratocytes, neutrophils

Table- 3: Comparison of the neovascularization and histopathologic scores between the interferon, octreotide and control groups.

GROUPS (eyes)	n	neovascularization score	Histopathological score
Control	10	$4.6 \pm 0.54$	$2.3 \pm 0.67$
Interferon	10	$3.2 \pm 0.44^*$	$1.5 \pm 0.54^*$
Octreotide	10	$2.3 \pm 0.83^{**}$	$1.0 \pm 0.70^{**}$

(\*  $p < 0.005$ ; between the control and the interferon groups, \*\* $p < 0.001$ ; between the control and the octreotide groups,  $p < 0.05$  between the interferon and the octreotide groups. Mann-Whitney U test)

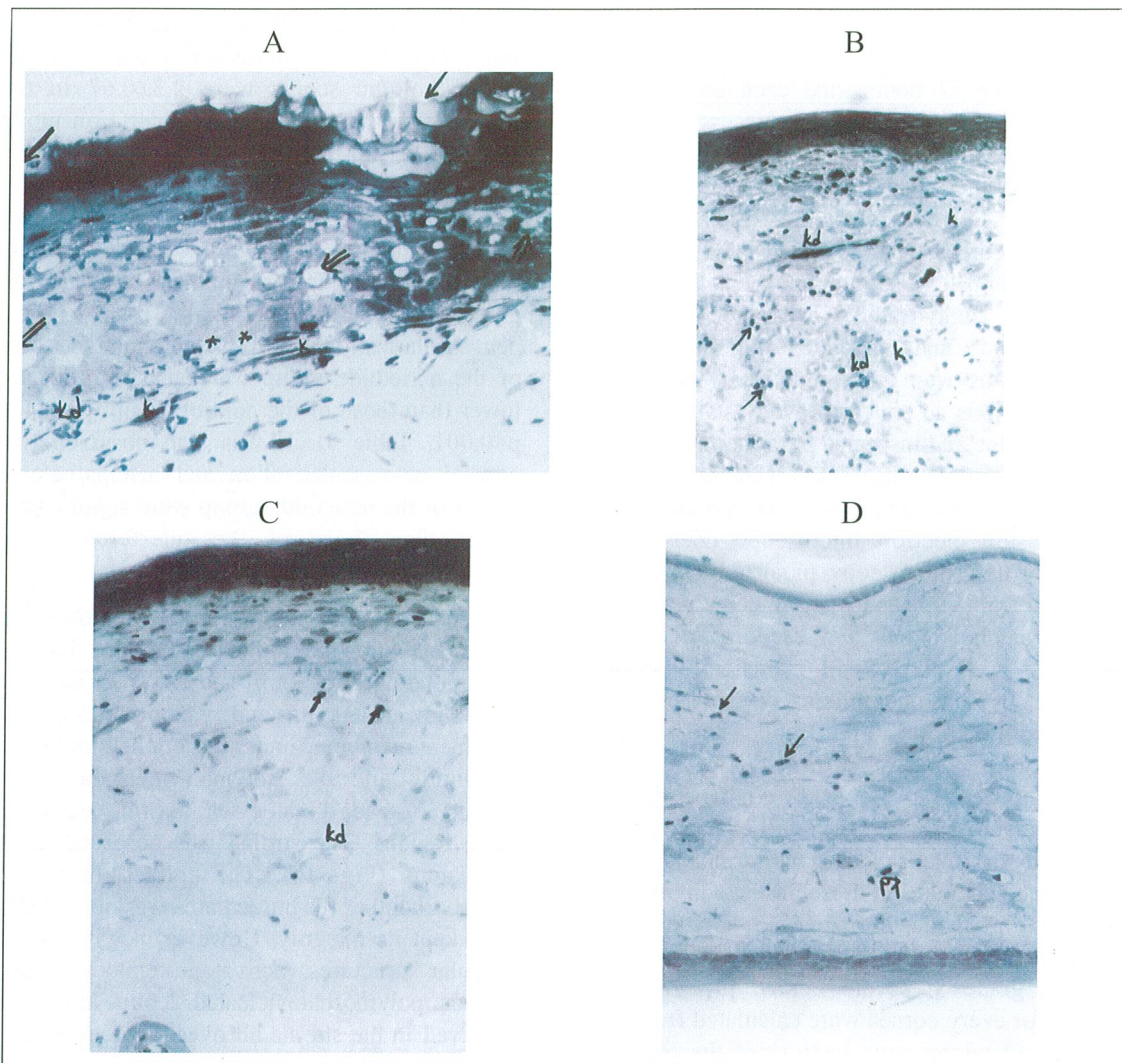


Fig. 1: Degeneration and detonation of corneal epithelial cells of the control group (arrows), separation between the cells and vacuolization (double arrows). Basement membrane losing its integrity under the epithelium (\*\*), dense keratocytes (k) and blood vessels (kd) in these areas. Toluidine blue. Original magnification x 80 (A). Keratocytes in the stroma (k), blood vessels (kd) and PMNL (arrows) in the regions neighboring the burned area of the control group. Toluidine blue. Original magnification. x 40 (B). PMNLs (arrows) and blood vessels (kd) in the stroma of the areas neighboring the burned area in the cornea of the interferon group. It is obvious that the PMNLs and blood vessels are fewer than in the control group. Toluidine blue. Original magnification. x 40 (C). Although corneal structures in the octreotide and interferon groups show similarities, blood vessels (kd) and PMNLs (arrows) are reduced in the octreotide group. Toluidine. Original magnification x 40 (D).

and dense collagen fibers are the dominant structures of this region (Fig. 2b). In the treatment groups, blood vessels (Fig. 2c) and the basal cells of the epithelium, basal lamina and hemidesmosomes were observed (Fig. 2d).

### DISCUSSION

The cornea is an avascular tissue and blood vessels may develop in certain pathologies (8). Inflammation, ischemia and corneal neovascularization resulting from metabolic and

toxic causes are some important corneal pathologies; these destroy the corneal transparency and cause vision loss. They may restrict the indications for keratoplasty (9). As the treatment of corneal neovascularization is difficult, preventive approaches are more valuable in neovascularization.

Photothrombosis, cryotherapy, irradiation, heat cauterization, superficial keratectomy and conjunctival grafts are among the various

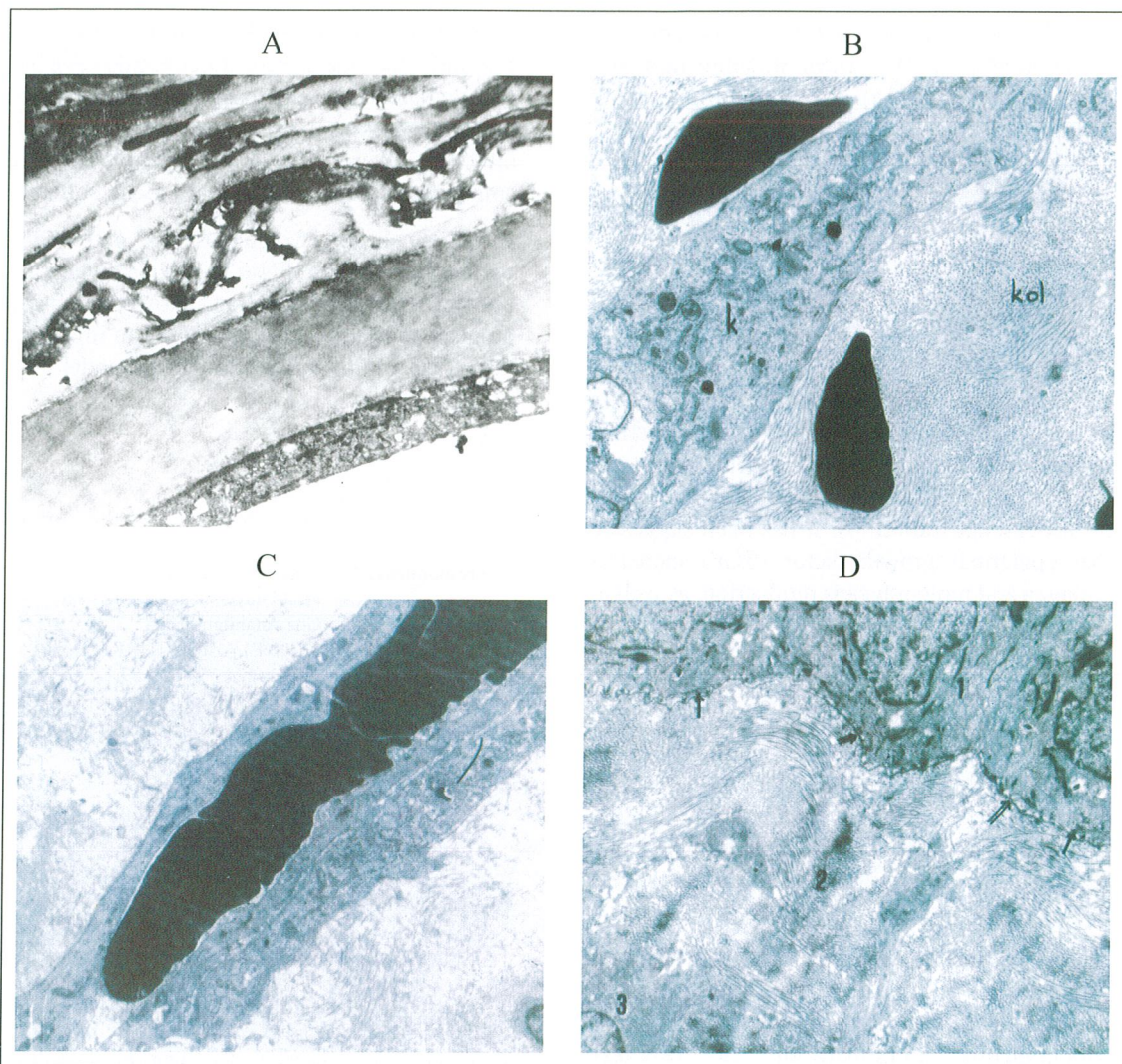


Fig. 2: Electron microscopic appearance of the control group, degeneration and deterioration are observed in the cells. Lead citrate uranyl acetate. Original magnification x 6000 (A). Blood vessels (kd) PMNLs (arrows) and collagen fibers (kol) and keratocytes (k) in the stroma of the control group. Lead citrate uranyl acetate. Original magnification x 4400 (B). Blood vessels persist in the stroma of the octreotide group. Lead citrate uranyl acetate. Original magnification x 8800 (C). Basement lamina (double arrows) showing integrity under the basal cells of the epithelium and hemidesmosomes (arrows) are observed. Basal cells (1), stroma and collagen fibers (2), keratocytes (3). Lead citrate uranyl acetate. Original magnification x 6000 (D).

invasive techniques previously used in corneas with vascular invasion (10). Several medical treatments have been tested for the prevention of corneal neovascularization. Nonsteroid anti-inflammatory drugs have been used for suppressing increased inflammatory cells due to inflammation, but their effects have been limited (1). For the same purpose, corticosteroids were also used. However, using corticosteroids over a long period may cause some side effects such as cataracts, glaucoma, and Herpes simplex infection recurrence (11). Systemic administration of amiloride, a plasminogen

activator inhibitor, may result in the suppression of neovascularization by causing lysis of the extracellular matrix, the first step of angiogenesis. Nevertheless, dehydration due to the diuretic effect of amiloride may be observed (12). It is known that cyclosporine A provides a suppressive effect on some cytokines responsible for neovascularization, and rapamycin, an antifungal agent, may suppress corneal neovascularization. However, their clinical use is limited because of their serious side effects (13, 14).

It has been reported that IFN- $\alpha$ 2b is effective in the treatment of corneal inflammation and neovascularization (15). In addition to the many cellular effects of IFN- $\alpha$ 2b, it has been demonstrated that IFN- $\alpha$ 2b inhibits the migration and proliferation of endothelial cells in vitro (16). Moreover, it has a blocking effect on the receptors of growth factors (17). Miller et al (18) suggested that IFN- $\alpha$ 2b has a selective effect on the regression of experimental iris neovascularization.

Octreotide, a long-acting somatostatin analogue, shows a direct antiproliferative effect in vivo and in vitro on many cell types (19). Several growth factors have a stimulatory effect on neovascularization (4). It has been suggested that epidermal growth factor (EGF) increases collagen and proteoglycans production, as well as fibronectin synthesis in the extracellular matrix, and causes neovascularization by increasing the rate of mitosis in the vascular endothelium and releasing plasminogen activator (20, 21). There are also reports about fibroblast growth factor (FGF) induced proliferation of vascular endothelial cells and cellular migration (22, 23). In another study endothelial cell growth factor (ECGF) was found to cause severe neovascularization in rabbits (24).

In our study, it was found that IFN- $\alpha$ 2b and especially octreotide inhibited corneal neovascularization. The results indicating that subcutaneous administration of IFN- $\alpha$ 2b suppresses the response of neovascularization are in agreement with the literature.

It has been suggested that octreotide administered intravitreally may slow down the progression of proliferative eye diseases (25). Luo et al (26) have reported that octreotide suppresses the development of proliferative vitreoretinopathy (PVR). It has been demonstrated that subcutaneous administration of octreotide prevents and inhibits neovascularization in proliferative and nonproliferative retinopathy characterized by elevated levels of insulin-like growth factor (IGF) (27, 28). It has also been suggested that octreotide may be beneficial in Graves ophthalmopathy by preventing the volume increase of extraocular muscles (29, 30).

IFN- $\alpha$ 2b has no reported severe side effects

apart from fever, muscular pain and fatigue (2). Similarly, the side effects of octreotide have been reported to induce dyspepsia, weight loss and gall bladder stones (27, 29). Compared with the side effects of other medications, these two drugs are some what innocent with regard to side effects.

In conclusion, we suggest that octreotide is more effective than IFN- $\alpha$ 2b in the prevention of corneal neovascularization. However, further clinical studies must be carried out to investigate the effects of octreotide in a human model.

**Correspondence to:** Tamer DEMİR, M.D.  
Fırat Üniversitesi Tıp Merkezi  
Göz Anabilim Dalı  
23200 ELAZIĞ - TÜRKİYE  
Phone: 424 - 247 69 87  
Fax: 424 - 238 80 96  
e-mail: tamerperumay@yahoo.com

#### REFERENCES

1. Richard C, William W, Anthony PA. Ocular angiogenesis. In: Albert MD, Jacobiec AF (eds.): Principles and Practice of Ophthalmology Basic Sciences. Philadelphia: The Curtis Center: 1994. p.1100-1106.
2. Pegram M, Mitsuyasu RT. Immune modulation; interferons and interleukins. In: Rich RR, Fleisher TA, Schwartz BD (eds.): Clinical Immunol Principles and Practice. Mosby: 1995. p. 2030-2045.
3. Mahoney J, Waterbury LD. Drug effects on the neovascularization response to silver nitrate cauterisation of the rat cornea. *Current Eye Res* 1985; 4: 531-535.
4. Funatsu H, Yamashita H, Noma H, Mimura T, Yamashita T, Hori S. Increased levels of VEGF and interleukin-6 in the aqueous humor of diabetics with macular edema. *Am J Ophthalmol* 2002; 133: 70-77.
5. Yogesh C, Murthy KK, Escher EE. Mechanism of action of somatostatin. An overview of receptor function and studies of the molecular characterisation and purification of somatostatin receptor proteins. *Metabolism* 1990; 39: 63-69.
6. Higgins RD, Yan Y, Schrier BK. Somatostatin analogs inhibit neonatal retinal neovascularization. *Exp Eye Res* 2002; 74: 553-559.
7. Green CJ. *Animal Anaesthesia Laboratory*. London: Oxford Press; 1982.
8. Granzyna M, Niederkon K, Niederkon JY. Spontaneous corneal neovascularization in nude mice. *Invest Ophthalmol Vis Sci* 1993; 31: 222-230.

9. Steinmann LT, Koppler BH, Jennings CD. Corneal allograft rejection following immunization. *Am J Ophthalmol* 1988; 106: 575-578.
10. Kinoshita S, Manabe R. Chemical burns. In: Brightbill FS (ed): *Corneal Surgery*. St Louis: Mosby Year-Book: 1992. p. 316-317.
11. Nirankari US, Dandona L, Rodrigues MM. Laser photocoagulation experimental corneal stromal vascularization. *Ophthalmol* 1994; 100: 111-118.
12. Avery RL, Connor TB, Farazdaghi M. Systemic amiloride inhibits experimentally induced neovascularization. *Arch Ophthalmol* 1990; 108: 1474-1476.
13. Belin MW, Bouchard CS, Frantz S, Chmielinska J. Topical cyclosporine in high risk corneal transplants. *Ophthalmology* 1989; 96: 1144-1150.
14. Olsen TW, Benegas NM, Joplin AC, Evangelista T, Mindrup EA, Holland EJ. Rapamycin inhibits corneal allograft rejection and neovascularization. *Arch Ophthalmol* 1994; 112: 1471-1475.
15. Park WC, Rho and Shin DH. Regression of experimental cornea vascularization with subconjunctival injection of interferon alpha-2a. *Invest Ophthalmol* 1994; 35: 1351-1357.
16. Boye DB, Zetter BR. Inhibition of cell motility by interferon. *Science* 1980; 28: 516-518.
17. Poliner SL, Tornabe EP, Michelson EP, Heitzman GJ. Interferon alpha 2-a for subfoveal neovascularization in age-related macular degeneration. *Ophthalmol* 1993; 9: 1417-1424.
18. Miller JW, Stinson WG, Folkman W. Regression of experimental iris neovascularization with systemic alpha interferon. *Ophthalmol* 1993; 100: 145-148.
19. Parmar H, Bogden A, Mollard M, de Rouge B, Phillips RH, Lightman SL. Somatostatin and somatostatin analogues in oncology. *Cancer Treat Rev* 1989; 16: 95-115.
20. Tripathi RC, Raja SC, Tripathi BJ. Prospects for epidermal growth factor in the management of corneal disorders. *Surv Ophthalmol* 1990; 34: 457-459.
21. Leibowitz HM, Morello S, Stern M, Kupferman A. Effect of topically administered epidermal growth factor on corneal wound strength. *Arch Ophthalmol* 1990; 108: 734-737.
22. Baudoin C, Reygrobellet DF, Caruelle JP. Acidic fibroblast growth factor distribution in normal human eye and possible implications in ocular pathogenesis. *Ophthalmic Res* 1990; 22: 73-81.
23. Reygrobellet FD, Boudouin C, Negre F, Caruelle JP, Gastaud P. Acidic FGF and other growth factors in preretinal membranes from patients with diabetic retinopathy and proliferative vitreoretinopathy. *Ophthalmic Res* 1991; 23: 154-161.
24. Satoh T, Kan M, Masuko K, Obinata M. Characterisation of a new endothelial cell growth factor (f-ECGF) partially purified from the supernatant of human fibroblast cells. *Biol Cell Jpn Soc* 1989; 14: 731-740.
25. Robertson JE, Westra I, Woltering EA, Winthrop KL, Barrie R, O'Dorisio TM, Holmes D. Intravitreal injection of octreotide acetate. *J Ocul Pharmacol Ther* 1997; 13: 171-177.
26. Luo Q, Peyman GA, Conway MD, Woltering EA. Effect of a somatostatin analogue (octreotide acetate) on the growth of retinal pigment epithelial cells in culture. *Curr Eye Res* 1996; 15: 909-913.
27. Grant MB, Mames RN, Fitzgerald C, Hazariwala KM, Cooper-DeHoff R, Caballero S, Estes KS. The efficacy of octreotide in the therapy of severe nonproliferative and early proliferative diabetic retinopathy: a randomized controlled study. *Diabetes Care*. 2000; 23: 504-509.
28. Kurg AW, Michon J, Tai KS, Chan FL. The effect of somatostatin versus corticosteroid in the treatment of Graves' ophthalmopathy. *Thyroid* 1996; 6: 381-384.
29. Günal AI, Işık A, Çeliker H, Eren O. Short term reduction of left ventricular mass in primary hypertrophic cardiomyopathy by octreotide injections. *Heart* 1996; 76: 418-421.
30. Bartalena L, Marcocci C, Tanda L, Pinchera A. Management of thyroid eye disease. *Eur J Nucl Med Mol Imaging*. 2002; 29 Suppl 2: 458-65.