

MIDGUT NON-ROTATION ANOMALY IN AN ADULT

Alp DEMİRAĞ, M.D., Fikret EZBERCİ, M.D., Ercüment TEKİN, M.D.,
Ferit TANERİ, M.D., Mehmet OĞUZ, M.D.

Gazi University, Faculty of Medicine, Department of General Surgery , Ankara, Turkey
Gazi Medical Journal 4 : 217-219, 1993

SUMMARY : *The most common abnormality of midgut rotation and fixation is nonrotation of the midgut. This most commonly presents in the neonatal. However, this condition present outside the neonatal period as chronic abdominal pain in the adults. Such a case is reported in this paper.*

Key Words : *Intestinal Nonrotation, Abdominal Pain.*

INTRODUCTION

Between the 4th and 11th weeks of intrauterine life, the midgut undergoes a complex process of herniation out of the abdominal cavity, rotation, return to the abdominal cavity, and fixation (3). Disturbances of this process can result in a number of anatomic abnormalities, the most common of which is nonrotation (2). By estimate, nonrotation of the midgut occurs in 0.2 % to 0.5 % of the adult population, and is clinically significant in only a minority of cases (4). It can also be the cause of significant abdominal pain in adults. The pain is recurrent and often associated with a feeling of distention. Each diagnostic or therapeutic delay increases the risk of strangulation and may end as an abdominal disaster. We describe such a case which was recently managed at our institution.

CASE REPORT

A 26-year-old woman presented to the emergency department with a 7 days history of intense right-sided abdominal pain that radiated to the whole abdomen, distention, emesis, and intermittent

vomiting. She had no change of bowel habit. She had had several similar episodes in the past not requiring hospitalization for observation. Her history was remarkable for the absence of prior surgical procedures or medical problems. Physical examination revealed moderate right-sided abdominal tenderness without peritoneal findings. The patient was afebrile. Laboratory and plain radiographs were unremarkable. Her pain resolved over approximately 3 days. An upper gastrointestinal series and barium enema were obtained, revealing a midgut nonrotation (Fig 1, 2).

A laparotomy was performed on the patient through a right-side paramedian incision. Operative findings were : nonrotation of the midgut and caecum, transvers colon, and sigmoid were found encased altogether by peritoneal bands. These were released and the appendix was removed but the caecum was not fixed. During one month of follow-up, she has had the same complaints.

DISCUSSION

By the 5th week of gestation, the alimentary

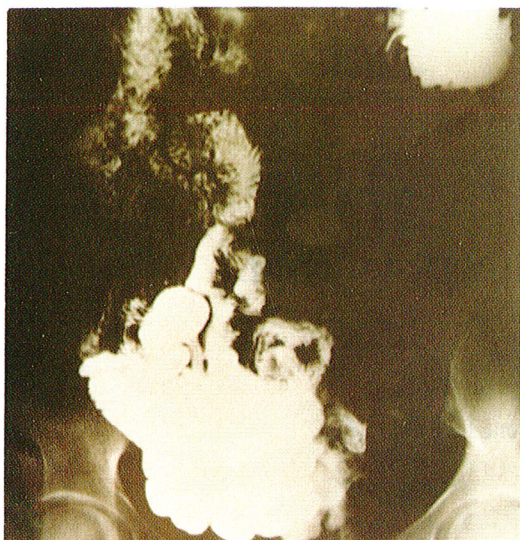


Fig - 1 : Small bowel follow-through showing the small bowel lying entirely on the right side of the abdomen.

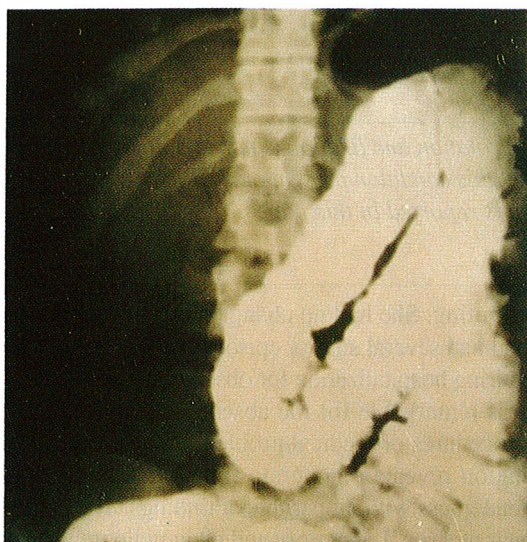


Fig - 2 : Barium enema revealing nonrotation. All of the colon is on the left side of the abdomen.

tract has divided into three main constituents based on blood supply. These are the foregut, midgut, and hindgut. The midgut forms a loop in the sagittal plane which has herniated into the umbilical cord (3). Rotation of the midgut occurs from the 5th to the 10th week of intrauterine life and the normal adult position (6, 12). This rotation has been divided roughly into three stages and at the end of these stages, caecum and right colon normally become fixed to the posterior abdominal wall, and the transverse colon lies over the mesenteric artery. When the midgut's rotation and fixation are complete, the duodenum and right colon are fixed to the posterior abdominal wall, and the mesentery of the small bo-

wel develops along an oblique line connecting these two fixed points. This arrangement does not allow volvulus of the midgut. Arrest of rotation can occur in any of the stages. The resulting anomalies are named for the stage in which arrest occurred. The most commonly faced abnormality of the midgut is midgut nonrotation.

The classical findings in nonrotation are 1) all the small bowel is placed on the right 2) all the large bowel is on the left 3) the duodenum descends straight down to the right of the superior mesenteric artery and the ligament of Treitz is deficient, and 4) the terminal ileum crosses the midline to enter the caecum from the right side instead of the left (11). This results in a midgut loop with a narrow base which is freely mobil about its long axis. The narrow base consists of duodenum, right colon, and superior mesenteric vessels. The clinic consequences of this arrangement are midgut volvulus and/or duodenal obstruction.

In the neonate, midgut nonrotation is often associated with other anomalies (5). In the older child and adult this usually is not the case. The clinical presentation is caused either by extrinsic obstruction of the duodenum by abnormal peritoneal bands, or by volvulus of the midgut. The presenting symptoms in adults are usually chronic abdominal pain, failure to thrive, chronic intermittent emesis, and constipation. The history usually mimics recurrent or partial obstruction. Typically the pain will be severe, last for a specified period of time, and then resolve spontaneously (9). Physical examination often will show only generalized abdominal tenderness and mild abdominal distension even during the acute stage. Most of these patients are misdiagnosed for a long time and many are considered to have psychiatric problems or malingering (7). These patients often present with acute complaints needing emergent evaluation.

Diagnosis is by intraoperative findings in the acute situation. In the chronic or semiacute situations, the diagnosis can be reliably established by upper gastrointestinal series complimented by barium enema (1).

The appropriate surgical procedure is that described by Ladd (8). The bands are released, allowing the base of the mesenteric loop to broaden. The appendix is removed. There is controversy regarding the need for pexing the right colon and duodenum in order to ensure that midgut loop has a broader and

fixed base to prevent subsequent volvulus (10). The alternative is to place the caecum in the left upper quadrant and rely on postoperative adhesions to prevent subsequent volvulus.

Correspondence to : Dr.Mehmet OĞUZ
Gazi Üniversitesi Tıp Fakültesi
Genel Cerrahi Anabilim Dalı
06510 ANKARA - TÜRKİYE
Phone : 312 - 212 65 65 / 225

REFERENCES

1. Balthazar EJ : Intestinal malrotation in adults. Roentgenographic assessment with emphasis on isolated complete and partial nonrotations. *AJR* 1976; 126 : 358-367.
2. Bill AH : Malrotation of the intestine. In : Ravich MM, Welch KJ, Benson CD, et al, editors. *Pediatric Surgery*. Chicago : Year Book Medical Publishers, 1979 : 912-922.
3. Dott NM : Anomalies of intestinal rotation. *Br J Surg* 1923; 11 : 251-286.
4. Estrada RL : Anomalies of intestinal rotation and fixation. Springfield, IL : Charles C Thomas, 1958; pp. 41-64.
5. Filston HC, Kirks DR : Malrotation-the ubiquitous anomaly. *J Pediatr Surg* 1981; 16 : 614-620.
6. Gardner CE, Hart D : Anomalies of intestinal rotation as cause of intestinal obstruction; report of 2 personal observations; review of 103 reported cases. *Arch Surg* 1934; 29 : 942-981.
7. Ingram NP, Gardner BP : An unusual presentation of intestinal malrotation in an adult. *Br J Clin Pract* 1981; 35 : 166-167.
8. Ladd WE : Surgical diseases of alimentary tract in infants. *N Engl J Med* 1936; 215 : 705-708.
9. Rowsom JT, Sullivan SN, Girvan DP : Midgut volvulus in the adult. A complication of intestinal malrotation. *J Clin Gastroenterol* 1987; 9 : 212-216.
10. Stauffer UG, Herrmann P : Comparison of late results in patients with corrected intestinal malrotation with and without fixation of the mesentery. *J Pediatr Surg* 1980; 15 : 9-12.
11. Wang CA, Welch CE : Anomalies of intestinal rotation in adolescents and adults. *Surgery* 1963; 54 : 839-855.
12. Yanez R, Spitz L : Intestinal malrotation presenting outside the neonatal period. *Arch Dis Child* 1986; 61 : 682-685.