

EFFECT OF VITAMIN E ON MAST CELLS

Azita AKHTEH, M.Sc., Aydan BABÜL, Ph.D., Gülten ALAN*, M.Sc., Sibel DİNÇER, M.D.

Gazi University, Faculty of Medicine, Departments of Physiology and Histology*, Ankara, Turkey
Gazi Medical Journal 4 : 161-165, 1993

SUMMARY : *In this study, the relationship between mast cells and vitamin E was examined. Fourteen mice which had been immunized were used in these experiments. The animals were separated into two groups, one of them being the control group. During ten days, 0.002 ml/gr saline was injected daily (im) to the control group and 0.3 mg/gr alpha tocopherol acetate (vitamin E) was injected (im) daily to each animal of the experimental group. At the end of this study, histamine levels were determined in the mesenteric tissue; intra peritoneal fluid and blood samples. Moreover in the peritoneal fluid and mesenteric tissue samples; mast cells were stained with toluidin blue and examined under light microscope.*

Level of histamine in the blood of control group was 1.68 ± 0.45 µg/ml while it was found to be 0.24 ± 0.05 µg/ml in the experimental group and the difference between the two groups was significant ($p < 0.01$). The level of histamine in the peritoneal fluid of the control group was 1.83 ± 0.35 µg/ml, while it was 0.29 ± 0.09 µg/ml in the experimental group, the difference was also significant ($p < 0.01$). There was also a statistically significant difference in the levels of histamine in the mesenteric tissue ($p < 0.001$) since its average was 20.86 µg/gr in the control group while 2.15 ± 0.12 µg/gr in the experimental group. Histologically, the increase in the number and granulation of mast cells was seen in the preparations of the control group; moreover cell-cell combination was also seen in them while only a very little amount of pale coloured cells were found on mice which had been pretreated with vitamin E.

In this study, the levels of histamine and histological differences were found to be similar and these results show that vitamin E has a stabilizing effect of the hiperactivity of mast cells.

Key Words : *Vitamin E, Mast Cells.*

INTRODUCTION

Histamine, mediator of acute inflammatory, allergic and anaphylactic reactions, is found mainly in mast cells (12). It has been shown that free oxygen radicals were also released through degranulation of mast cells either by chemical or anaphylactogenic antibodies (14, 3). On the other hand, free oxygen radical scavengers like superoxide dismu-

tase and peroxidase were also found in mast cells besides amines. Although these scavengers may have a protective effect from the physiologically active mediators released by degranulation of these cells; when histamine is released in high amounts, they were ineffective to protect the organism (2). Therefore in these conditions, it is necessary to inhibit the synthesis of these radicals by using some

antioxidant drugs. It is well known that ascorbic acid and vitamin E can protect the organism from the harmful effects of free oxygen radicals (2).

Ascorbic acid has also been identified as the vitamin that detoxifies histamine (4) since it has an effect preventing free radical formation and degranulation (14). Vitamin C has a dose - dependent double effect on tissue oxidation, ie : causing peroxidation of unsaturated free fatty acids at low concentrations while having a strong antioxidant effect in doses higher than 0.5 mmol/L (11).

In the present literature; of the two vitamins C and E that are said to have antioxidant features, only studies involving the mast cell- vitamin C associations could be found. However; no studies could be found about the relation of mast cell activation and vitamin E which is supposed to have a different action due to its lipid solubility. As a result; this preliminary study was planned to investigate the interaction between mast cell functions and vitamin E.

MATERIALS AND METHODS

In this study; 14 Swiss Albino mice with augmented immune sensitivity were used. 0.2 ml of complete Freund adjuvant was injected as a single dose- intraperitoneally - so as to increase the mast cell activity (5).

The mice were randomly allocated into two groups; the first - control - group receiving saline (im) 0.002 ml/gr of body weight for 10 days while the 7 animals in the experimental group receiving 0.3 mg Alpha Tocopherol Acetate (Vitamin E) / gr of body weight (im) - prepared as a solution consisting of 0.3 mg vitamin E in 0.002 ml saline - for 10 days.

After the completion of the experimental period; peritoneal fluid was obtained by Thon and Uvnas method (17). For this technique; 2 ml of Sorenson's buffer - pH: 6 - was injected into the peritoneal cavity and the abdomen was gently massaged for 1-2 minutes. Later on, abdominal cavity was opened and 0.5 ml of the lavage solution was mixed with 1 ml of Ficoll solution to be centrifuged for 35 min at 1400 rpm at 21 °C. The ring consisting mast cells was pipetted, washed with saline for 3 times and the histamine level in 1 ml of the resulting volume was measured (6, 16).

After the peritoneal lavage, the mice were killed by decapitation and histamin level was measured in both blood and mesenterical tissue specimens.

For morphological investigations; peritoneal fluid was smeared and mesenteric tissue blocks were paraffin embedded and sectioned to be stained with toluidine blue. Mast cells were histologically examined. Histamine level results were analysed according to student's t test.

RESULTS

When the groups were compared on the aspect of histamine levels; control values were always higher than in the vitamin E applied group (Graph 1).

The histamine levels varied between 0.172 µgr/ml and 2.875 µgr/ml in the control group while between 0.083 µgr/ml and 0.5 µgr/ml in the experimental group. The mean histamin levels of the two groups had a statistically significant difference of 70.3 % ($p < 0.01$).

The difference was also statistically significant ($p < 0.01$) when the peritoneal fluid histamin levels were compared; the control group having higher values by 63.9 %.

The greatest difference was observed between the mesenterical tissue specimens being 97.% ($p < 0.001$). The mean histamine level in the control group was 20.855 ± 4.767 µgr/gr while 2.15 ± 0.115 µgr/gr in the experimental group.

Both mesenterical tissue and peritoneal fluid specimens stained with toluidine blue were examined by a BH₂ Olympus photomicroscope and the pictures were compared. Although the peritoneal fluid of the saline applied sensitized mice contained a large amount of mast cells (Fig 1b); these cells were either very few or absent in the group receiving vitamin E (Fig 1a). Comparisons made with higher magnification (x40) revealed structural differences of the mast cells between the groups. Mast cells of the control group (Fig 2b) were almost 2 times bigger and more densely stained than in the experimental group (Fig 2a).

Mesenteric tissue preparations also displayed findings that support the observations made in the peritoneal fluid specimens. The cells were densely stained and focally degranulated in the control group (Fig 3b) while little and sparsely granulated in the experimental group (Fig 3a).

DISCUSSION

Most of the studies on mast cell functions are conducted on rats. The choice of this animal depends on their higher sensitivity and higher cellular

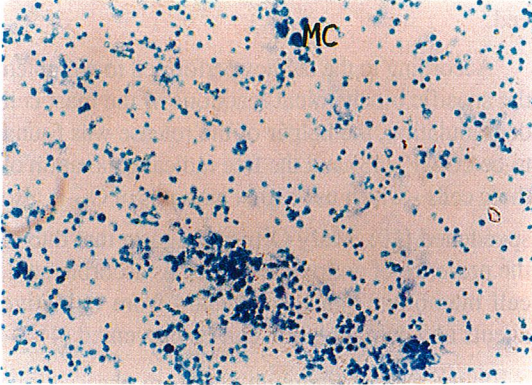


Fig - 1a : Effect of vitamin E on peritoneal suspension. Mast cells MC. Toluidine - blue, x200

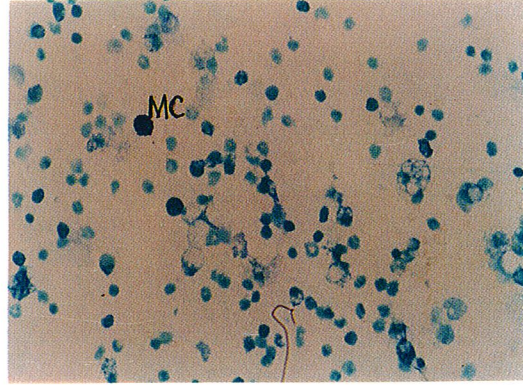


Fig - 2a : Vitamin E Group. Mast cell : MC. Toluidine blue, x400.

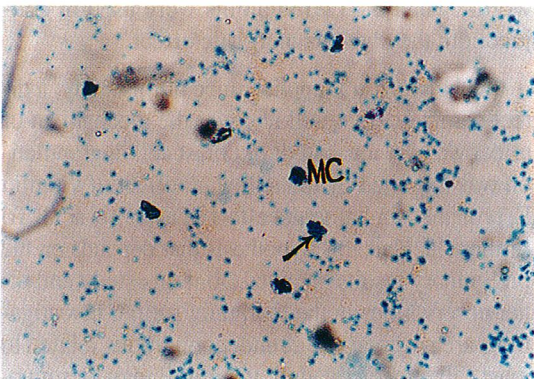


Fig - 1b : Control peritoneal suspension. Mast cells : MC. Toluidine - blue, x200

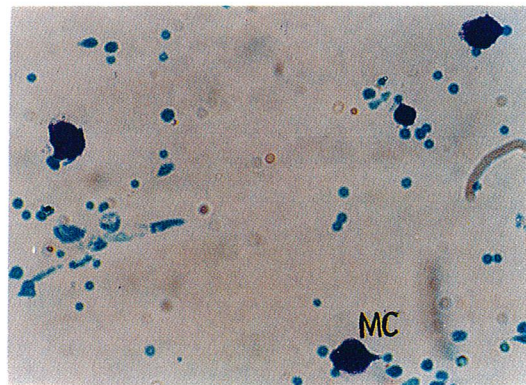


Fig - 2b : Control, peritoneal suspension. Mast cell, MC, Toluidine blue, x400.

density. Mice are almost poor of mast cells; however their intraabdominal organs are very rich of histamine (1). Furthermore, increasing the sensitivity of the mice using the complete Freund's adjuvant is a common technique (8). In this study; both the presence of mast cells on histological specimens and measurable quantities of histamine support the reliability of the applied technique. The high histamine levels of the blood obtained from control group may be another proof of the increasing mast cell activation.

In the studies about the mast cells; cellular count usually has a positive or negative correlation with the other findings. For example, in the antigen - ant-

body reactions; mast cell count and histidin decarboxylase activity were increased consequently (12). However; in case of mechanical trauma or acute inflammation (9); the degranulation is increased while the cell count is decreased. Slutsky et al suggest that after immunological and non immunological stimulation of the mast cell cultures obtained from rat peritoneum; cellular dimensions are also changed (15).

Due to the different observations in the literature; in this study conducted on mice, mast cell contents of peritoneal fluid and mesenteric tissue were compared to the histamine levels. As a result; the cellular density was found to change in parallel with the histamine levels in both groups of mice.

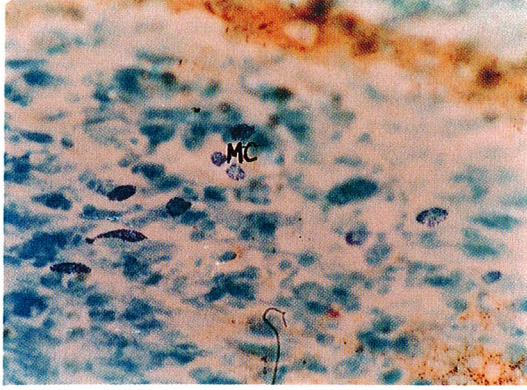


Fig - 3a : Vitamin E Group. Mast cell : MC. Toluidine blue, x400.

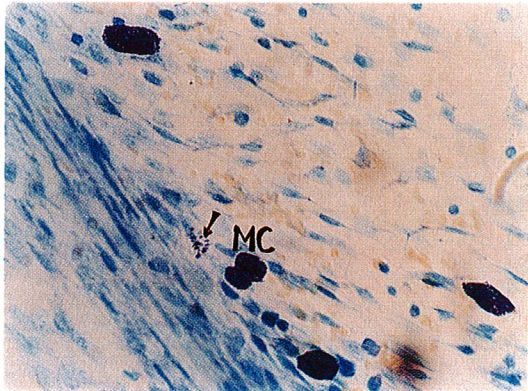


Fig - 3b : Control. Mast cells : MC. Degranulation (Arrow). Toluidine blue, x400.

Histamine is found in minute amounts in human plasma (0.5 - 5.5 µg/ml) and is released 2-3 mg/day from the tissues. When it overrides these amounts, it will give rise to many pathologies (11). In such conditions; prevention and lessening of degranulation is vital for decreasing the strength of the reactions. In this study; significant intergroup variations of the histamine levels were observed, but the difference between the groups was found to be significant in all preparations. The mean histamine levels of the vitamin E group was found to be lower than the other group and additionally; the lesser cell count and granule density are supportive observations. In accordance with these findings; numerical increase of the mast cells and appearance of bigger

cells resulting from cellular combination are both probably prevented by vitamin E. And as a result of this; an effect stabilizing the high activity of mast cells and decreasing the histamine release is observed.

According to the studies performed to enlighten the specific biochemical reactions of the mast cell degranulation, the helper of the release was found to be cGMP; (13) and the free radical generation of these cells - which use higher amounts of O₂-is also speedened (10). Mary Ortner suggests that due to the presence of antioxidants such as ascorbic acid, cell membrane can be protected from oxidative agents and degranulation can be prevented (4).

In the present literature, there are observations suggesting that vitamin E prevents free radical formation such as vitamin C. On the other hand; in a study performed on liposomes by Doba et al in 1985 (7); these two vitamins were found to have co-oxidant interrelations in the organism due to their solubility in aqueous and lipid mediums. In other words; when the two vitamins were used in conjunction; they had a synergistic effect.

In the vitamin E applied mice of this study; a direct parameter that will uncover the mechanism of effect was not measured; but mast cell degranulation was inhibited by the reductant effect of vitamin E, probably similar to the effect of ascorbic acid. To further elucidate this hypothesis that depends on the preliminary results obtained from this study and other observations in the literature; further investigations are necessary. But under conditions related to mast cell hyperactivation; vitamin E may be supposed to prevent responses such as skin rash, oedema and bronchoconstriction.

Correspondence to :

Dr.Aydan BABÜL
Gazi Üniversitesi Tıp Fakültesi
Fizyoloji Anabilim Dalı
Beşevler
06510 ANKARA - TÜRKİYE
Phone : 312 - 212 81 28 / 317

REFERENCES

1. Anton AH, Sayre DF : A modified fluorometric procedure for tissue histamine and its distribution in various animals. *J Pharmacol Exp Therap* 1969; 166 : 285-292.
2. Basaga HS : Biochemical aspect of free radicals. *Biochem Cell Biol* 1990; 68 : 989-998.
3. Boucek RJ : Factors affecting wound healing. *Otolaryngol Clin North Am* 1984; 17 : 243-264.
4. Chatterjee IB, Dasgupta S, Majumder AK, Nandi BK, Subramanian N : Effect of ascorbic acid on histamine metabolism in scorbutic guinea-pigs. *J Physiol* 1975; 251 : 271-279.
5. Coligan JE, Kruisbee AM : Antibody detection and preparation. In "Current Protocols in Immunology" New York 1992; pp. 1-5.
6. Demay C, Lyman MA, Cheng J : Procedures for immunoc- hemical study of histamine release from leukocytes with small volume of blood. *J of Allergy* 1970; 46 : 12.
7. Doba T, Burton GW, Ingold KU : Antioxidant and coantio- xidant activity of vitamin C, either alone or in the presence of vitamin or a water-soluble vitamin E analogue, upon the peroxidation of Aqueous Multilamellar phospholipid lipo- somes. *Biochimica et Biophysica Acta* 1985; 835 : 298-303.
8. Flint KC, Leung KBP, Hundspith BN, Brostoff J, Pearce UL, Geraint - James D, Johnson N : Bronchoalveolar mast cells in sarcoidosis : Increased numbers and accentuation of mediator release. *Thorax* 1986; 41 : 94-99.
9. Grosman N : Effect of TMB-8 on histamine release from iso- lated rat mast cells. *Int Archs Allergy Appl Immun* 1986; 79 : 253-258.
10. Henderson WR, Kaliner M : Immunologic and Nonimmu- nologic Generation of superoxide from mast cells and ba- sophils. *J of Clin Invest* 1978; 61 : 187-196.
11. Hershko C : Mechanism of Iron Toxicity and its possible role In : Red cell membrane damage. *Semin Hematol* 1989; 26 : 277-285.
12. Maslinski C : Histamine and its metabolism in mammals. Part I : Chemistry and Formation of Histamine, Agents and Actions 1975; 5 : 89-107.
13. Nakamoto T, McCroskey M, Mallek HM : The role of ascor- bic acid deficiency in human gingivitis-A new hypothesis. *J Theor Biol* 1984; 108 : 163-171.
14. Ortner MJ : The oxidation of endogenous ascorbic acid dur- ing histamine secretion by rat peritoneal mast cells. *Exp Cell Res* 1980; 129 : 485-487.
15. Slutsky B, Jarvis D, Bibb P, Feldberg RS, Cochrane DE : Vi- ability and recovery from degranulation of isolated rat peri- toneal mast cells. *Exp Cell Research* 1987; 168 : 63-78.
16. Shore PA, Burkhalter A, Cohn VII : A method for the fluoro- metric assay of histamine in tissues. *J Pharmacol Exp Therap* 1959; 127 : 182-186.
17. Thon IL, Uvnas B : Mdoe of storage of histamine in mast cells. *Acta Physiol Scand* 1966; 67 : 455-470.