

HYALINIZING TRABECULAR TUMOR OF THE THYROID GLAND

Metec Kaan BOZKURT¹, Levent SAYDAM², Lale KUTLUAY³

ABSTRACT:

Hyalinizing thyroid trabecular tumor (HTTT) is a rare benign encapsulated neoplasm of the thyroid gland that was first described by Carney in 1987. Besides its morphological variations this thyroid lesion is histologically characterized by a trabecular growth pattern interspersed with hyaline material. As the differential diagnosis is complicated because of its similarity with papillary and medullary carcinomas of the thyroid immunohistochemical studies must be performed to confirm the diagnosis. Here we present a case that was initially misdiagnosed as medullary carcinoma of the thyroid. Subsequent histopathological and immunohistochemical evaluations (negative for calcitonin, chromogranin, neuron-specific enolase and synaptophysin, and positive for thyroglobulin) of the specimen, including completion left total thyroidectomy material, resulted in the final diagnosis of HTTT.

Key words: Trabecular Tumor, Thyroid Gland, Medullary Carcinoma

TİROİD BEZİNİN TRABEKÜLER ADENOMU

ÖZ:

1987 yılında Carney tarafından tanımlanan trabeküler tümör tiroid glandın nadir görülen, benign, enkapsüle bir neoplazisidir. Değişik morfolojik özellikler gösteren bu tiroid lezyonu histolojik olarak trabeküler büyüme paterni içine serpistirilmiş hyalinize materyal ile karakterizedir. Sitolojik ve histolojik görünümünün kolaylıkla papiller ve medüller tiroid karsinom ile karışılabilmesi nedeniyle trabeküler adenomun tanısı klinik pratikte yanlışlıklara yol açabilmektedir. Bu nedenle nihai patolojik tanı bahsedilen tiroid kanserlerini ekarte edebilmek için immünhistokimyasal tetkikler ile mutlaka desteklenmelidir. Bu çalışmada patolojik incelemesi medüller tiroid karsinom olarak rapor edilen fakat immünhistokimyasal tetkik sonucu [Kalsitonin: negatif (-), Kromogranin: negatif (-), Sinaptofizin: negatif (-), NSE: negatif (-), Tiroglobulin: pozitif (++)] tanısı trabeküler tümör olarak değiştirilen bir olgu sunulmaktadır.

Anahtar Kelimeler Trabeküler Adenom, Tiroid Gland, Medüller Karsinom

INTRODUCTION

Hyalinizing thyroid trabecular tumor (HTTT) was first described in 1987 by Carney et al.¹ as a rare encapsulated benign follicular tumor. Histopathologically, the tumor is characterized by hyaline material dispersed within a trabecular growth pattern. Pathologists may easily misdiagnose this tumor as a papillary or medullary thyroid cancer (PTC and MTC, respectively) due to some cytological and histopathological similarities; however, it is much more difficult to distinguish HTTT from PTC since both tumors share a common follicular epithelial origin and express thyroglobulin. Furthermore, making a differential diagnosis between HTTT and PTC based solely on cytopathological features is practically impossible since both neoplasms demonstrate nuclear grooves, cytoplasmic intranuclear pseudoinclusions, and psammoma bodies.^{2,3} Immunohistochemistry plays a key role in the differential diagnosis of HTTT from MTC, despite their great histopathological similarity. Positive immunostaining for thyroglobulin, and negative immunostaining for calcitonin and other neuroendocrine markers support the diagnosis of HTTT over MTC.

Herein, we present a case initially misdiagnosed as MTC in which subsequent immunohistochemical studies led us to change the initial diagnosis to HTTT.

CASE REPORT

A 39-year-old woman presented with a slow-growing right-sided neck mass of 1-year duration. Head and neck physical examination findings were normal, except for a 3 cm solitary thyroid nodule on the right lobe. Ultrasonographic (US) examination revealed a hypoechoic, solid thyroid nodule occupying almost the entire right lobe. Blood tests, including free T3, T4, and TSH levels, were normal. Preoperative fine needle aspiration biopsy (FNAB) was suspicious for malignancy and a right thyroid lobectomy, including isthmusectomy, was performed. The perioperative frozen section was inconclusive. Upon the pathological diagnosis of MTC, a completion thyroidectomy was performed 2 d after the initial operation. Immunohistochemical studies performed later to confirm the initial diagnosis were inconsistent with MTC (negative for calcitonin, chromogranin, neuron-specific enolase (NSE) and synaptophysin, and positive for thyroglobulin) and the final diagnosis was changed to HTTT. The patient is alive and free of recurrence 3 years after surgery.

Pathological findings:

Macroscopically, a nodular tumoral lesion clearly demarcated from the surrounding normal thyroid parenchyma was identified. The cut surface was smooth and had a brownish-yellow discoloration. Microscopically, the lesion consisted of uniform atypical cells that had granular eosinophilic cytoplasm with hyperchromat-

¹ Selçuk Üni. Meram Tıp Fak., KBB, Konya, Türkiye

² Bayındır Hastanesi, KBB, Ankara, Türkiye

³ Bayındır Hastanesi, Patoloji, Ankara, Türkiye

ic round nuclei and poorly defined nucleole that formed rare follicular or pseudopapillary structures in a richly vascular hyalinized stroma septated by thin fibrous bands, which produced the typical trabecular appearance. Pseudopsammomatous calcifications within the homogeneous eosinophilic material were noted in some follicles. Amyloid in the tumor stroma was negative (Figures 1-3).

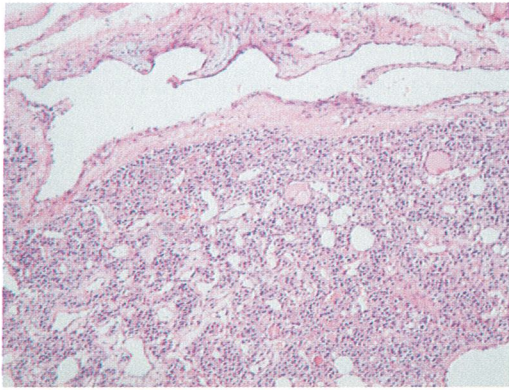


Figure 1. Some portions of the nodule were hypercellular with uniform cells forming sheets and trabeculae embedded in a highly vascular stroma. (Original magnification H.E. x40)

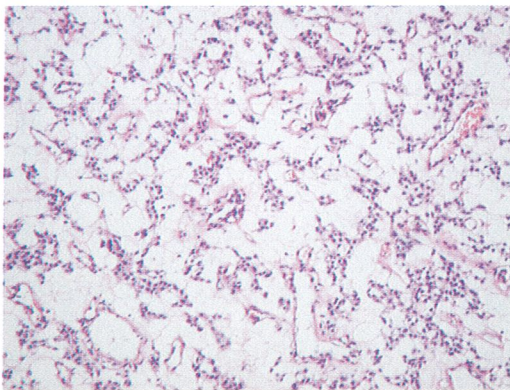


Figure 2. Some parts of the nodule were hypocellular and cords of cells were observed in an edematous vascular stroma. (Original magnification H.E. x40)

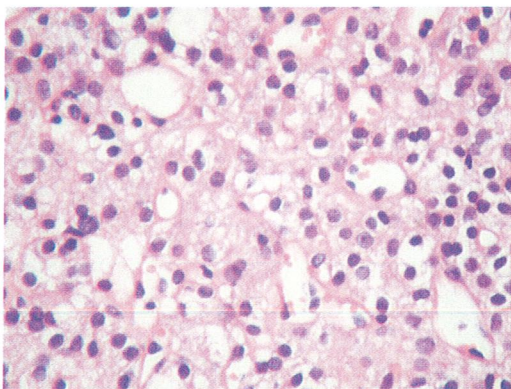


Figure 3. The nodule was composed of cells with uniform hyperchromatic nuclei and moderately large, granular eosinophilic cytoplasm. (Original magnification H.E. x400)

Immunohistochemical findings:

Immunostaining for calcitonin, chromogranin, synaptophysin, and NSE was negative. Cytoplasmic immunoreactivity for thyroglobulin was positive (Figure 4).

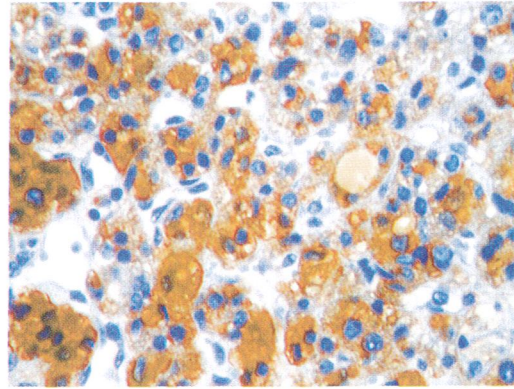


Figure 4. Immunohistochemically the cells of the nodule stained strongly positive for thyroglobulin. (Original magnification H.E. x400)

DISCUSSION

HTTT is a rare encapsulated benign thyroid tumor that is usually encountered in adult women. Due to similar cytological and histopathological features, it can easily be misdiagnosed as PTC or MTC. As described by Carney et al.¹, this tumor demonstrates typical features, including fine nuclear grooving, perinuclear vacuoles, oval or elongated nuclei, and infrequent mitotic figures. Histopathologically, PTC and HTTT share similar features, such as nuclear grooves, intranuclear cytoplasmic pseudoinclusions, and psammoma bodies. Since HTTT and PTC have a common follicular cell origin, and thyroglobulin positivity can make differential diagnosis difficult, Hirokawa and Carney³ suggest evaluating the MIB-1 antibody, which is uniquely expressed by HTTT. In our case, the prominent trabecular pattern and elongated oval nuclei were sufficient for differentiating from PTC. The similarity between MTC and HTTT is mainly due to the presence of hyaline fibrosis mimicking amyloid matter within the trabecular epithelial pattern, and elongated spindle cellular structures seen with light microscopy. With HTTT, however, the hyaline material is composed of collagen, not amyloid, and does not show argyrophil granules as in MTC. In terms of immunohistochemical staining, thyroglobulin positivity, which suggests a follicular cell origin, negative results for calcitonin, and other neuroendocrine markers are keystones for discriminating HTTT from MTC.

In the presented case, positive staining for thyroglobulin and negative calcitonin results were concordant with previous findings in the literature.^{1,4,5}

CONCLUSION

The diagnostic possibility of HTTT should always be kept in mind during the differential diagnosis of MTC or PTC prior to making a definitive diagnosis of a malignant lesion.

Correspondence Address: Mete Kaan BOZKURT
Selçuk University, Selçuklu School of
Medicine Otolaryngology-Hand and
Neck Surgery
42075, Selçuklu, Konya, Turkey
Pbx: 033241 5000-40147
E-mail: bozkurtmetekaan@hotmail.com

REFERENCES

- 1) Carney JA, Ryan J, Goellner JR. Hyalinizing trabecular adenoma of the thyroid gland. *Am J Surg Pathol* 1987; 11(8): 583-591.
- 2) Kuma S, Hirohawa M, Miyauchi A, et al. Cytologic features of hyalinizing trabecular adenoma of the thyroid. *Acta Cytol* 2003; 47: 399-404.
- 3) Hirokawa M, Carney JA. Cell membrane and cytoplasmic staining for MIB-1 in hyalinizing trabecular adenoma of the thyroid gland. *Am J Surg Pathol* 2000; 24(4): 575-578.
- 4) Cheung CC, Boerner SL, MacMillan C, et al. Hyalinizing trabecular tumor of the thyroid: A variant of papillary carcinoma proved by molecular genetics. *Am J Surg Pathol* 2000; 24(12): 1622-1626.
- 5) Kaleem Z, Davila RM. Hyalinizing trabecular adenoma of the thyroid. A report of two cases with cytologic, histologic and immunohistochemical findings. *Acta Cytol* 1997; 41: 883-888.