

BLIND ENDING URETER: A RARELY DIAGNOSED URETERAL DUPLICATION ANOMALY IN CHILDHOOD

Mehmet BALASAR², Mehmet Mesut PİŞKİN¹, Faruk ÇİÇEKÇİ³, Recai GÜRBÜZ¹

ABSTRACT:

Blind ending ureter is a rare congenital malformation of the urinary system and is classified as a ureteral duplication anomaly. Most cases are not diagnosed until they become symptomatic. Although it is a congenital malformation, patients are usually diagnosed in the 3rd and 4th decades and presentation in childhood is very rare. Mostly they manifest with loin pain, urinary tract infection, or stone disease. Intravenous pyelogram, retrograde pyelogram, and computerized tomography can be used for diagnosis. Voiding cystourethrography must be performed to exclude associated vesicoureteral reflux. Herein, we report an 11-year-old child who had a blind ending duplicated ureter associated with vesicoureteral reflux causing renal atrophy.

Key words: Urogenital Abnormality, Ureter, Vesicoureteral Reflux, Blind Ending Ureter

BLIND ENDING URETER: A RARELY DIAGNOSED URETERAL DUPLICATION ANOMALY IN CHILDHOOD

ÖZ:

Kör sonlanan üreter, üreteral duplikasyon anomalileri içinde sınıflanan, üriner sistemin nadir görülen bir anomalisidir. Olguların çoğunluğuna semptomatik olmadıkça tanı konulamaz. Konjenital bir anomali olmasına rağmen hastalar genellikle üçüncü dördüncü dekatta tanı alır, çocukluk çağında ortaya konulan olgu son derece azdır. Genelde böğür ağrısı, üriner sistem enfeksiyonu ya da taş hastalığı ile ortaya konulur. İntravenöz pyelografi, retrograde pyelografi, bilgisayarlı tomografi tanı amaçlı kullanılabilir. Renal atrofiye neden olan veziköüreteral reflü ile birlikte seyreden 11 yaşında bir çocuk olguyu sunuyoruz.

Anahtar Kelimeler: Ürogenital Anomali, Üreter, Vesicöüreteral Reflü, Kör Sonlanan Üreter

INTRODUCTION

Ureteral duplication is the most common congenital malformation of the urinary tract. The incidence is 0.85% and it has a wide spectrum of imaging findings¹. Blind-ending ureter is a rare anomaly in the spectrum of ureteral duplication. They are mostly clinically insignificant pathologies unless the patient is symptomatic. This malformation is more commonly seen in females than in males, and right side locations dominate^{2,3}. Mostly it is of caudal origin as in the case we describe below⁴. Patients usually present in the third and fourth decades; diagnosis in childhood is very rare⁵. We report an 11-year-old child with refluxing blind ending left ureter that was diagnosed with voiding cystourethrography (VCUG) during a vesicoureteral reflux investigation.

CASE REPORT

An 11-year-old girl presented with intermittent left loin pain. The patient's complaints had been continuing for 2 years and 2 previous urinary tract infections had been diagnosed in other health centers. Her physical examination revealed slight tenderness in the left flank region and her temperature was 36.8 °C. Urine analysis showed microscopic hematuria and leukocyturia. Complete blood count and blood urea and nitrogen were within normal ranges. The ultrasound revealed that the left kidney was 53 x 16 mm with hydronephrosis in the renal pelvis, while the right kidney was 105 x 36 mm with a normally appearing collecting system. Antibiotic treatment was administered for 10 days. Three weeks following the initial treatment, VCUG was performed. The VCUG revealed refluxing duplicated left ureters one of which was blind ending (Figure 1). The Tc⁹⁹ DMSA scan showed an atrophic left kidney with a differential function of 5.35%. The right kidney had normal function and parenchyma structure. Under general anesthesia cystoscopy was performed and 2 lateralized ureteral orifices were seen; then left nephroureterectomy was performed and the duplicated ureters were removed from within their sheaths with an extended flank incision (Figure 2). The postoperative period was uneventful and patient was discharged on the 3rd postoperative day.

DISCUSSION

At the end of the 4th week of gestation, two major components of the urinary system including the ureteric bud and metanephrogenic blastema begin to develop. The ureteric bud is derived from the mesonephric duct (wolffian) and forms the ureter, renal pelvis, renal calices, and collecting tubules. When the ureteric bud grows cranially, it contacts with the metanephrogenic blastema and induces the development of blastema. The metanephrogenic blastema finally covers the cranial end of the ureteric bud and it

¹ Selek University Meram Medical Faculty, Department of Urology, Konya, Turkey

² Konya Hospital, Department of Urology, Konya, Turkey

³ Konya Hospital, Department of Anesthesiology, Konya, Turkey

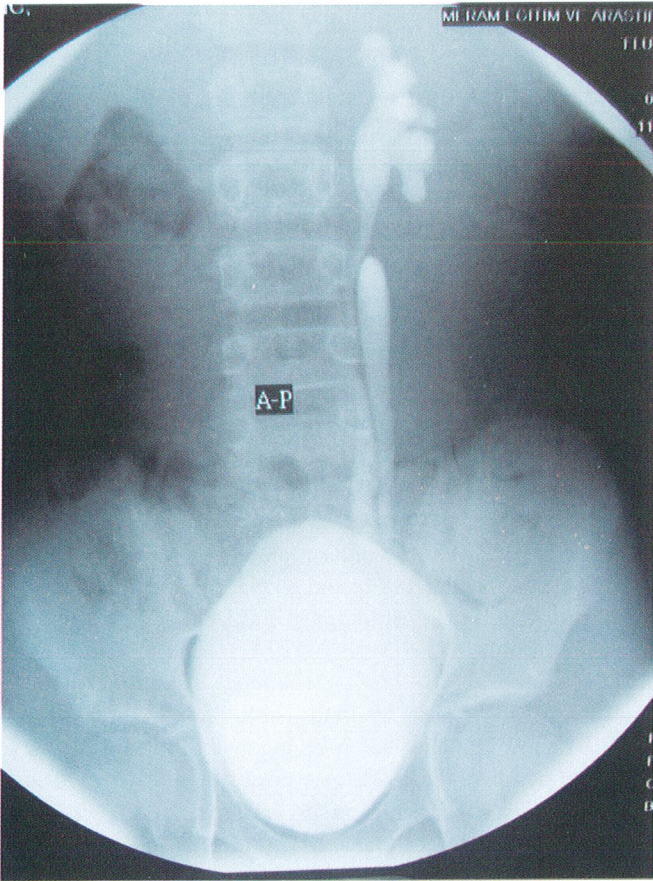


Figure 1: VCUG showing the refluxive ureteral units on the same side.

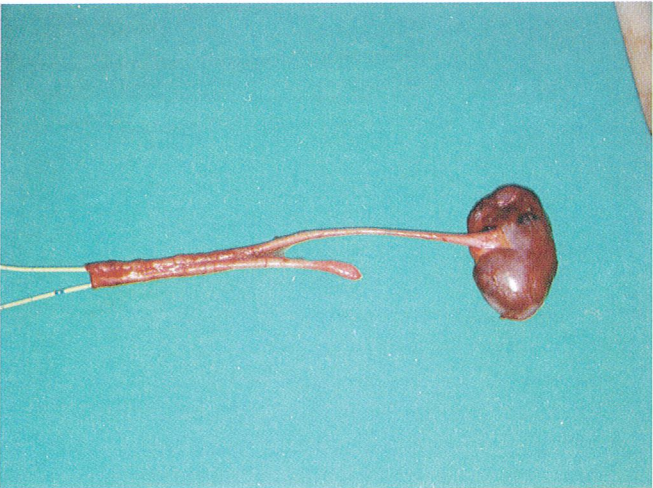

Figure 2: Gross appearance of the duplicated ureter one of them has blind end.

is the primordial portion of the permanent kidney¹. When a premature division of the ureteric bud occurs, and if one of the limbs fails to reach the metanephric tissues then a blind-ending branch will be formed⁶.

Although it is a congenital anomaly, blind-ending ureter in childhood is rare; probably it does not cause problems in early life. There are less than 10 reports related to blind-ending ure-

ter of childhood found in the English literature. Patients are mostly diagnosed in the 3rd or 4th decades, and sometimes can be diagnosed incidentally during transplantation^{5,7}. The most common symptom is loin pain. The reflux and poor drainage of the blind ending ureter might explain the mechanism of loin pain, recurrent urinary tract infections, and calculi formation. Moreover, hematuria, hydroureteronephrosis, and even transitional tumor formation in blind ureters have been reported in the literature⁴. Blind ending ureter associated reflux nephropathy as in the case reported above has not been reported before.

Diagnosis is usually possible by intravenous pyelography. Retrograde pyelography is also effective when the diagnosis is not clear with intravenous pyelography. Computerized tomography is also an important diagnostic tool in demonstration of this anomaly⁵. VCUG might also show a blind ureter if reflux exists and we think that VCUG should be additionally performed in patients with blind-ending ureter to demonstrate the associated vesicoureteral reflux.

Treatment of blind-ending ureter should be based on the complications. Medical treatment might be the first choice treatment in patients with simple urinary tract infections. Surgical modalities should be performed in complicated cases, as in the present case.

Correspondence Address: M. Mesut PIŞKİN

Selçuk University Meram Medical Faculty

Department of Urology

Konya, Türkiye

Pbx: 0332 223 61 16

E-mail: drmesutpiskina@yahoo.com

REFERENCES

- 1) Cooper CS, Synder HM. Ureteral Duplication, Ectopy, and ureterocele. In: Gearhart JP, Rink RC, Mouriquand PE, editors, Pediatric urology. Philadelphia: W.B. Saunders Company, 2001; 430-53.
- 2) Marshall FF, McLoughlin MG. Long blind-ending ureteral duplications. J Urol 1978; 120: 626-28.
- 3) Albers DD, Geyer JR, Barnes SD. Clinical significance of blind-ending branch of bifid ureter: report of 3 additional cases. J Urol 1971; 105: 634-637.
- 4) Kılıçarslan H, Ayan S, Gökçe G, et al. Cranial blind-ending branch of a bifid ureter Int Urol and Nephrol 2001; 32: 635-36.
- 5) Choi JY, Kim SH, Kim SH. Double-blind ureteral duplication: report of two cases. Eur Radiol 2002; 12: 136-9.
- 6) Eisenberg MJ, Weingarten M, Abdul-Quader M. Bifid blind ending ureters. J Urol 1986; 136: 90-91.
- 7) Hauser S, Fechner G, Gerhardt T, et al. First report of an unexpected blind-ending duplication of the ureter as a rare pitfall in kidney transplantation. Transpl Int 2008; 21: 696-7.