

Endoscopic Treatment of a Fistula, Which is Developed by Anastomotic Leakage with Fibrin Glue

Anastomoz Kaçağına Bağlı Oluşan Bir Fistül Vakamızın Endoskopik Olarak Fibrin Glue ile Onarılması

Kemal Peker¹, İsmail Demiryılmaz²

¹ Erzincan University, Faculty of Medicine, Department of General Surgery, Erzincan, Turkey

² İbni Sina Hospital, General Surgery Clinics, Kayseri, Turkey

ABSTRACT

Surgeons have been using sutures made up of different materials to reunite disrupted tissues, throughout centuries. However, these materials may have certain disadvantages like foreign body reaction, infection, scarring, need for removal and cost. Their application is time-consuming and needs skill and experience. Whereas tissue adhesives is one of alternative to conventional suturing and has some additional advantages. The use of fibrin glue, as in concentrated human fibrinogen in combination with thrombin for hemostasis and tissue adhesion has been an important advance in a variety of surgical applications. The purpose of this study is to share our experience about fibrin glue.

Key Words: Anastomotic leakage, tissue adhesives, endoscopy

Received: 02.11.2013

Accepted: 02.13.2017

ÖZET

Yüzyıllardır cerrahlar dokuları onarmak için farklı malzemelerden yapılmış sütürleri kullanmaktadırlar. Ancak, bu materyallerin yabancı cisim reaksiyonu ve enfeksiyon gibi bazı dezavantajları mevcuttur. Bunlarla birlikte, operasyon sahasında skar dokusu oluşturdıkları gibi maliyeti de artırmaktadırlar. Diğer bir yandan, bu yöntemlerle onarım beceri, tecrübe ve daha fazla zaman gerektirmektedir. Oysaki doku yapıştırıcıları konvansiyonel yöntemlere bir alternatif olup bazı avantajları da mevcuttur. Trombin ile kombine halde konsantre edilmiş insan fibrinojeni olarak fibrin yapıştırıcı kullanımı, hemostaz ve dokuların yapışmasında önemli avantajlar sağlamaktadır. Bu çalışmamızdaki amacımız, fibrin glue ile ilgili deneyimimizi paylaşmaktır.

Anahtar Sözcükler: Anastomoz kaçağı, doku yapıştırıcı, endoskopi

Geliş Tarihi: 11.02.2013

Kabul Tarihi: 13.02.2017

INTRODUCTION

Fibrin glue is a unique surgical hemostatic/adhesive material that is being utilized with increasing frequency in a variety of surgical situations. In practice, it is a two-component system in which a solution of concentrated fibrinogen and factor XIII are combined with a solution of thrombin and calcium in order to form a coagulum, simulating the final stage of the clotting cascade. Once the thrombin/calcium is combined with the fibrinogen/factor XIII, a fibrin clot forms in seconds, or somewhat slower if a more dilute form of thrombin is used(1,2). Here, we introduce a fistula patient who had been administered fibrin glue to repair his enterocutaneous fistula which is developed after an anastomotic leakage.

CASE REPORT

A 20 year-old male patient has undergone total proctocolectomy, ileal pouch anal-anastomosis (IPAA) and protective ileostomy operation for familial poliposis coli (FAP). On post operative 5. day, fecal drainage from drain catheters occurred, patient had leukocytosis on complete blood count with a body temperature of 39°C. On postoperative 13. day, patient's body temperature was normalized, with a leukocyte value in normal range and patient was discharged with a controlled fistula. On postoperative 20. day, patient has undergone a flexible rectoscopy and a dehiscence observed on the anastomotic line (Fig. 1)

Address for Correspondence / Yazışma Adresi: Kemal Peker, MD Erzincan University, Faculty of Medicine, Department of General Surgery, Erzincan, Turkey, E-mail: kpeker@erzincan.edu.tr

©Telif Hakkı 2017 Gazi Üniversitesi Tıp Fakültesi - Makale metnine <http://medicaljournal.gazi.edu.tr/> web adresinden ulaşılabilir.

©Copyright 2017 by Gazi University Medical Faculty - Available on-line at web site <http://medicaljournal.gazi.edu.tr/>

doi:<http://dx.doi.org/10.12996/gmj.2017.34>

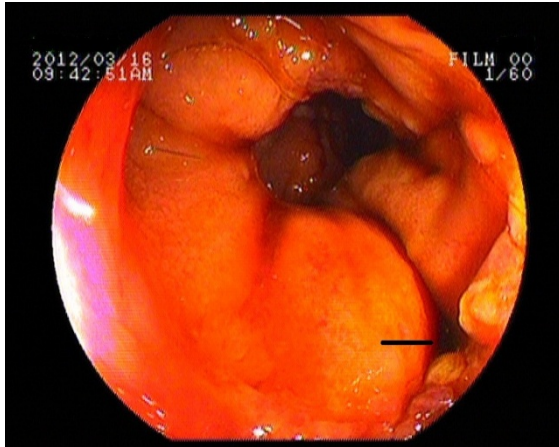


Figure 1. Anastomotic dehiscence is observed on endoscopic evaluation

Povidone-iodine solution injected through endoscope into the defect on anastomotic line and oozed from external fistula opening. 45 days later, rectoscopic re-evaluation of the patient revealed that defect on anastomotic line became larger (Fig. 2)

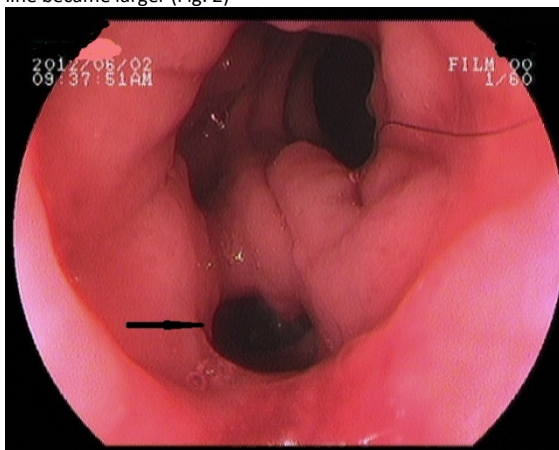


Figure 2. Endoscopic appearance of the anastomotic dehiscence demonstrating a larger opening.

On the second endoscopy, internal fistula aperture was found to be larger. Meanwhile granulation tissue on the fistula tract was debrided. 4 ml of fibrin glue was injected into the fistula line and the mucosal edges brought closer with endoscopic clips. On the 10. day of endoscopic intervention a control endoscopy was done. We observed that the inner opening of fistula was obliterated. (Fig.3)

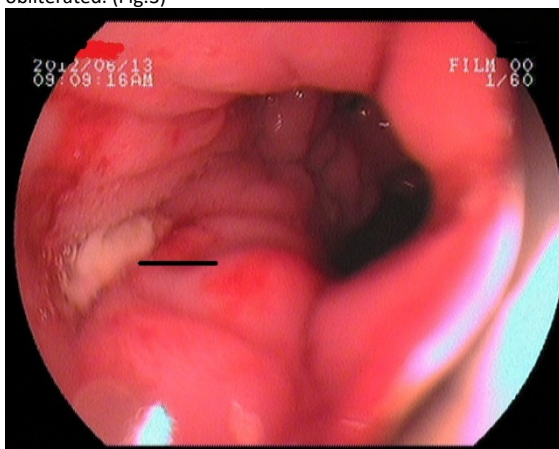


Figure 3. Endoscopic image of obliterated inner fistula opening following injection of fibrin glue

Ileostomy was closed on the same hospitalization. Patient was discharged with no postoperative complication. On 6. month follow-up no signs of recurrence was observed.

DISCUSSION

Familial adenomatous polyposis is an autosomal dominant disease characterized by the presence of numerous adenomatous polyps in colon. The polyps inevitably develop into cancer in 10 to 15 years after first their appearance, and to prevent cancer development, the only available treatment at present is total proctocolectomy(3,4). Restorative proctocolectomy with IPAA now has been accepted as the standard surgical procedure for FAP(5). At present, there are many treatment options suggested for treatment of postoperative lower enterotomospheric fistulas, but no standardized treatment can be systematized as a guideline(6). We wanted to share our experience in treatment of a fistula which is occurred due to a postoperative anastomotic leakage and treated with fibrin glue administration.

The principle behind the use of fibrin glue is adopted from wound healing. The first phase of wound healing is inflammation, which involves formation of thrombus through series of events in coagulation cascade. The final outcome is conversion of fibrinogen to fibrin. Fibrin glue augments the induction of entire process of wound healing, as whole of the coagulation cascade is bypassed and ready-made fibrin is immediately produced with its adhesive function, due to fibrin polymers(7).

As a result, fibrin glue injection is a reasonable treatment option for a low-output fistula which is in an endoscopically accessible location. Fibrin glue treatment could be also rendered cost-effective as it decreases the hospital stay times.

Conflict of interest

No conflict of interest was declared by the authors.

REFERENCES

1. Currie LJ, Sharpe JR, Martin R. The Use of Fibrin Glue in Skin Grafts and Tissue-Engineered Skin Replacements: A Review. *Plastic and Reconstructive Surgery* 2001;108:1713-26.
2. Aksoy H, Apikoğlu-Rabus Ş, Uras F, Savcı N, Alatlı FC, Erseven G et al. Evaluation of the Effect of Fibrin Glue Prepared from Single-Donor Plasma on Wound Healing in Rats. *Hacettepe University Journal of the Faculty of Pharmacy* 2009;29:83-93.
3. Bulow S. Familial polyposis coli. *Danish Med Bull* 1987;34:1-15.
4. Palanivelu C, Jani K, Sendhilkumar K, Parthasarathi R, Senthilnathan P, Maheshkumar G. Laparoscopic Restorative Total Proctocolectomy With Ileal Pouch Anal Anastomosis for Familial Adenomatous Polyposis. *JLS* 2008;12: 256-61.
5. Lee SH, Ahn BK, Chang H, Baek SU. Adenocarcinoma in Ileal Pouch after Proctocolectomy for Familial Adenomatous Polyposis: Report of A Case. *J Korean Med Sci* 2009; 24: 985-8.
6. Del Rio P, Dell'Abate P, Soliani P, Ziegler S, Arcuri M, Sianesi M. Endoscopic treatment of esophageal and colo-rectal fistulas with fibrin glue. *Acta Biomed* 2005; 76: 95-8.
7. Saxena S, Jain P, Shukla J. Preparation of two component Fibrin Glue and its clinical evaluation in skin grafts and flaps. *Indian J Plast Surg* 2003;36:14-7.