

## CASE REPORTS

# INTRAMEDULLARY HEMANGIOMA OF BONE: REPORT OF A CASE AND REVIEW OF THE LITERATURE

Aykın ŞİMŞEK, M.D.,

Metin ÖZALAY, M.D.,

Köksal BEŞLİ, M.D.,

Nalan AKYÜREK\*, M.D.,

Gülen AKYOL\*, M.D.

Gazi University, Faculty of Medicine, Departments of Orthopaedics and Traumatology and Pathology\*, Ankara

Gazi Medical Journal 2000; 11: 129-131

**SUMMARY:** Hemangiomas of bone are rare lesions comprising 1 % of all primary bone tumors that usually involve a vertebra or the skull. The long tubular bones and the ribs are the least commonly affected. A sixty-five-year old woman underwent surgery for a pathologic left femoral neck fracture. Immunohistochemical studies revealed a capillary intramedullary hemangioma. Four cases of proximal femur hemangiomas were described by Dahlin's Bone Tumors series. This report is, to our knowledge; the first describing a pathologic femoral neck fracture due to metaphyseal capillary intramedullary hemangioma.

**Key Words:** Intramedullary, Hemangioma, Femoral Neck.

## INTRODUCTION

Hemangiomas of bone are rare lesions comprising 1 % of all primary bone tumors. Hemangioma of bone is a benign tumor that usually involves a vertebra or the skull and is commonly found as an incidental asymptomatic lesion. The long tubular bones and the ribs are least commonly affected (1). Hemangiomas of the long tubular bone are mainly medullary. Periosteal and intracortical hemangiomas are extremely rare (1-6). Hemangioma of bone commonly occurs in the fifth decade, predominately in women. Most hemangiomas are solitary lesions but hemangiomas may affect two or more bones of a single extremity, sometimes also involving the overlying soft tissues and producing serious malformation and dysfunction (7,8).

## CASE REPORT

A sixty-five-year old woman was admitted to our hospital with left hip pain and difficulty in walking resulting from a fall. Four months previously she was operated on for a right femoral neck fracture at another institute. The pathology report of this operation was not known. In her physical examination, range of motion was limited and there was left hip pain. Routine laboratory data was within normal limits. Plain roentgenography revealed a displaced left femoral neck fracture (Fig. 1A). There was no soft tissue mass or periosteal reaction. Hemiprosthetic arthroplasty was performed (Fig. 1B) and the femoral head and neck were sent to the pathology department. On gross examination, macroscopic sections revealed no significant lesion. Microscopic sections demonstrated thin walled capillaries with lumens full of blood in the fibrous stroma of medullary bone spaces (Fig. 2A




Fig. 1A: Preoperative A-P view of left hip showing femoral neck fracture. B: Postoperative Pelvis A-P view.

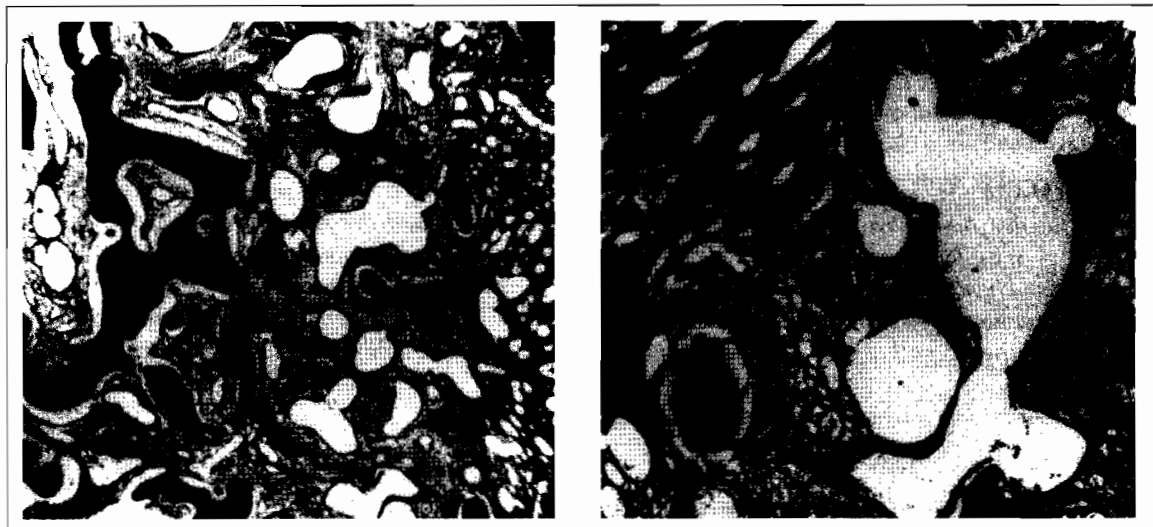


Fig. 2 A : Well-demarcated collections of normal blood vessels lined by delicate endothelium (Hematoxylin-eosin x200). B : Blood vessels are shown by reticulum dye (Reticulum x400).

and 2B). The endothelial cells covering the lumen of capillaries were small and uniform. In immunohistochemical studies, these cells were stained with factor eight. At the follow-up examination three years after the operation, the patient was free of pain with no incidence of local recurrence.

#### DISCUSSION

Hemangioma of bone is a rare lesion. Dahlin notes that these lesions comprised only 1.2 % of his total tumors (7). Biopsies are rarely done. Dorfman found that seventeen (71 percent) of twenty-four hemangiomas occurred in the bodies of the vertebra and in the skull (9).

Lesions in the spine have a coarse, vertical trabecular pattern with so-called honeycomb or corduroy appearance on radiographs. A computed tomographic scan displays a characteristic polka-dot pattern (5). Most hemangiomas are asymptomatic and found incidentally on radiographs. If there are symptoms, they are usually vague and patients complain of insidious onset of pain. Spinal cord compression or cauda equina syndrome has been reported in patients with vertebral lesions (8,10).

Hemangiomas of long tubular bone are mainly medullary but periosteal and cortical hemangiomas are rarely reported (4). Medullary

hemangiomas are commonly seen at the metaphyseal and diaphyseal region of long bones. Medullary hemangiomas may rarely be completely osteolytic. The radiographic appearance of the long bones characteristically shows a cystic or soap bubble appearance and the cortex is typically expanded. In most long-bone lesions however, the appearance is nonspecific (5, 8). Initially, the differential diagnosis included metastasis, chondrosarcoma, fibrosarcoma, malignant fibrous histiocytoma, primary lymphoma, infarct, soft tissue tumor, and plasmacytoma. MRI can define the extent and nature of the lesion and limit the differential diagnosis (11). In the differential diagnosis of intracortical hemangioma, osteoma and osteoid osteoma must be considered (5).

Histologically, hemangiomas consist of well-demarcated collections of normal blood vessels lined by delicate endothelium. When these vessels are narrow in caliber, they are termed capillary hemangiomas. If the vascular channels are dilated, they are termed cavernous hemangioma (4). Most hemangiomas of bone are basically cavernous, although sometimes a capillary component is present and may even be dominant (7). Hemangioendotheliomas are vascular tumors of intermediate malignant behavior, whereas angiosarcomas are strictly malignant (4,12).

The treatment of vertebral hemangiomas varies from observation of an obvious hemangioma to decompression in cases with spinal cord compression or cauda equina syndrome. Radiation may be required for lesions in inaccessible sites. The treatment of long bone lesions is usually observation or excision and bone grafting. Malignant transformation has not been described in solitary lesions (7,8).

Four cases of proximal femur hemangiomas were described by Dahlin's Bone Tumors series (7). In summary, this report is, to our knowledge; the first described femoral neck pathologic fracture due to metaphyseal hemangioma.

**Correspondence to :** Aykın ŞİMŞEK, M.D.  
Konutkent 2, B4 Blok B Giriş  
No 10  
Çayyolu  
06530 ANKARA - TÜRKİYE  
Phone : 312 - 214 10 80  
Fax : 312 - 241 44 83  
E-mail: ayk@med.gazi.edu.tr.

#### REFERENCES

1. Loxley SS, Thiemeyer JS, Ellsasser JC. Periosteal Hemangioma : A report of two cases. *Clin Orthop* 1972; 85: 151-154.
2. Devaney K, Vinh TN, Sweet DE. Surface-Based Hemangiomas of Bone. *Clin Orthop* 1994; 300: 233-240.
3. Kenan S, Bonar S, Jones C, Lewis MM. Subperiosteal Hemangioma : A case report and review of literature. *Clin Orthop* 1988; 232: 279-283.
4. Kenan S, Abdelwahab IF, Klein MJ, Lewis MM: Hemangiomas of the long tubular bone. *Clin Orthop* 1992; 280: 256-260.
5. Lopez-Barea F, Hardisson D, Rodriguez-Peralto JL, Sanchez-Herrera S: Intracortical Hemangioma of Bone. Report of two cases and review of the literature. *J Bone Joint Surg* 1998; 80-A: 1673-1678.
6. Seeff J, Blacksin MF, Lyons M, Benevenia J. A case report of intracortical hemangioma. *Clin Orthop* 1994; 302:235-238.
7. Unni KK. *Dahlin's Bone Tumors, General Aspects and Data on 11087 Cases*. Philadelphia: Lippincott-Raven Publishers, 1996: 307-316.
8. Weiner SD, Leeson MC. Hemangioma of the Tibia. *Orthopedics* 1990; 13:1397-1400.
9. Dorfman HD, Steiner GC, Jaffe HL. Vascular tumors of bone. *Hum Pathol* 1971; 2:349-376.
10. Lee S, Hadlow AT. Extraosseous extension of vertebral hemangioma, a rare cause of spinal cord compression. *Spine* 1999; 24:2111-2114.
11. Weiss KS, Sabogal J, Carter JR. Intramedullary hemangioma of the tibia and the value of magnetic resonance imaging in its detection. *Orthopedics* 1990; 13:89-90.
12. Van der List JJJ, Van Horn JR, Slooff TJJH, Cate LN. Malignant epitheloid hemangioendothelioma at the site of a hip prosthesis. *Acta Orthop Scand*, 1988;58: 326-330.