

## Segmental Clavicle Fracture in an Adolescent: A Rare Occurrence and Treatment Dilemma

Bir Adolesanda Segmental Klavikula Kırığı: Nadir Bir Durum ve Tedavi İkilemi

Atmananda Hegde, Prajwal P. Mane, Chethan B. Shetty, Seetharama Rao

Department of Orthopaedics, Kasturba Medical College, Mangalore, Manipal Academy of Higher Education, Manipal, India

### ABSTRACT

Clavicular fractures are some of the common injuries in orthopedic practice. These fractures mainly occur in the mid-shaft, followed by the lateral third. Generally, these fractures in paediatric and adolescent patients are treated conservatively with satisfactory outcomes. Segmental or bipolar fractures of the clavicle are rare, and only a few isolated cases have been reported in the literature. We report a case of segmental right clavicle fracture in an adolescent patient sustained following a fall on an outstretched hand. One fracture was in the midshaft of the clavicle and was minimally displaced, and another fracture was located in the lateral physis region with significant displacement. Lateral physeal injury was treated by open reduction, and k wire fixation and midshaft fracture was conservatively treated. At the end of 8 weeks, both the fractures had healed, and the patient had an excellent functional outcome.

**Key Words:** Bipolar clavicle fractures; segmental fractures; clavicular fractures; lateral end of the clavicle fractures

**Received:** 05.13.2021

**Accepted:** 10.19.2021

### ÖZET

Klavikula kırıkları ortopedik pratikte sık görülen yaralanmalardan bazılarıdır. Bu kırıklar esas olarak orta şaftta meydana gelir, bunu lateral üçte bir takip eder. Genellikle, pediatrik ve adolesan hastalardaki bu kırıklar, tatmin edici sonuçlarla konservatif olarak tedavi edilir. Klavikulanın segmental veya bipolar kırıkları nadirdir ve literatürde sadece birkaç izole vaka bildirilmiştir. Biz bir adolesan hastada uzanmış bir el üzerine düşme sonrası gelişen segmental sağ klavikula kırığı olgusunu sunuyoruz. Bir kırık klavikula orta şaftındaydı ve minimal olarak yer değiştirmişti ve başka bir kırık lateral fiz bölgesinde önemli yer değiştirme ile yer aldı. Lateral fizyal yaralanma açık redüksiyon ile tedavi edildi ve k tel tespiti ve orta şaft kırığı konservatif olarak tedavi edildi. 8 haftanın sonunda her iki kırık da iyileşmiş ve hasta mükemmel bir fonksiyonel sonuç elde etmiştir.

**Anahtar Sözcükler:** Bipolar klavikula kırıkları; segmental kırıklar; klavikula kırıkları; klavikula kırıklarının lateral ucu

**Geliş Tarihi:** 13.05.2021

**Kabul Tarihi:** 19.10.2021

**ORCID IDs:** A.H. 0000-0001-6893-4238, P.P.M. 0000-0002-6031-1607, C.B.S.0000-003-4459-6099, S.R.0000-0002-7760-5484

**Address for Correspondence / Yazışma Adresi:** Dr.Prajwal. P. Mane, Department of Orthopaedics, Kasturba Medical College, Mangalore, Manipal Academy of Higher Education, Manipal, India E-mail: pjlmane@gmail.com

©Telif Hakkı 2022 Gazi Üniversitesi Tıp Fakültesi - Makale metnine <http://medicaljournal.gazi.edu.tr/> web adresinden ulaşılabilir.

©Copyright 2022 by Gazi University Medical Faculty - Available on-line at web site <http://medicaljournal.gazi.edu.tr/>

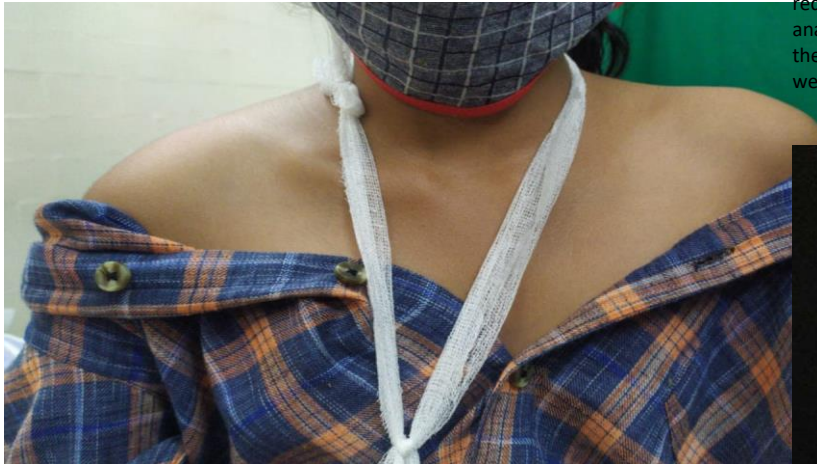doi:<http://dx.doi.org/10.12996/gmj.2022.18>

**INTRODUCTION**

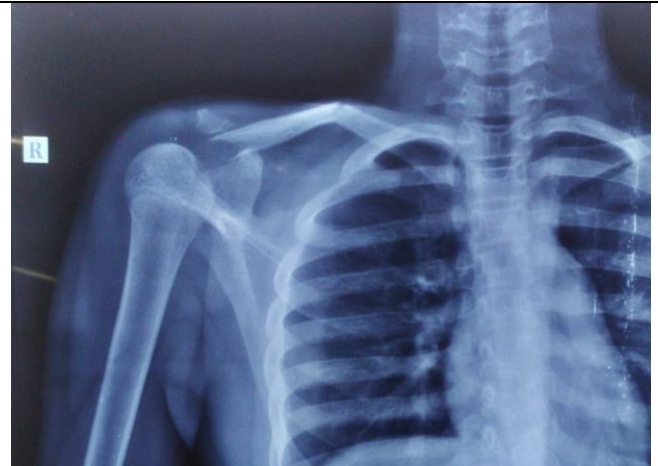The incidence of clavicle fracture in adolescents and adults has been reported to be 29-64 /100,000 persons annually (1). Midshaft clavicular fractures are the most common, ranging from 69% -82%, distal fractures comprise 21% to 28%, and proximal fractures occur between 2% and 3% (1). Segmental fractures in clavicle are very rare. There are isolated case reports of segmental and bipolar clavicle fractures (combined medial and lateral end clavicle fractures), most of them in adults (2). With meagre literature regarding these injuries, no consensus exists about managing these fractures, with some case reports advocating a non-operative (3) while others an operative approach (4). We report a segmental fracture of the clavicle in an adolescent treated by surgery for only the lateral end physeal fracture.

**CASE REPORT**

A 12-year-old girl presented with pain and swelling over right clavicle following fall on outstretched hand (Figure 1). There was diffuse tenderness over the whole extent of the clavicle with painful restriction of shoulder movements. There were no distal neurovascular deficits. Radiographs revealed minimally displaced fracture at midshaft and significantly displaced fracture at lateral physis region (Figure 2). She was initially treated by arm sling and analgesics.

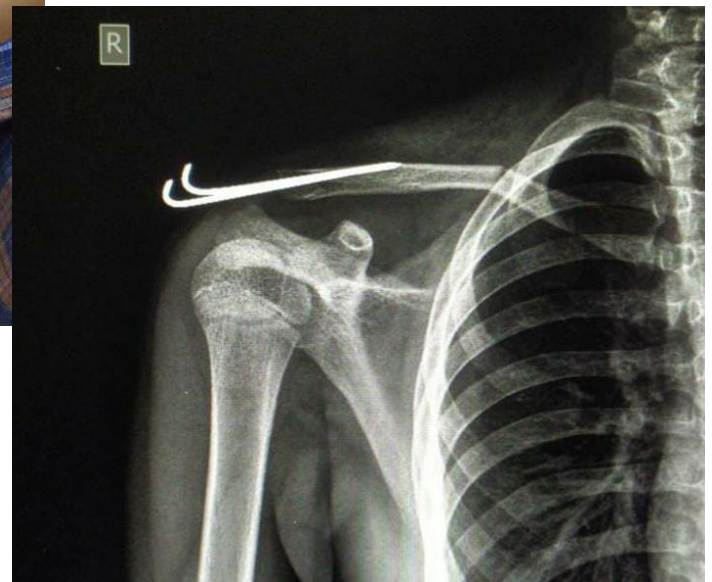

**Figure 1:** Clinical picture following injury showing swelling along the right clavicular region.

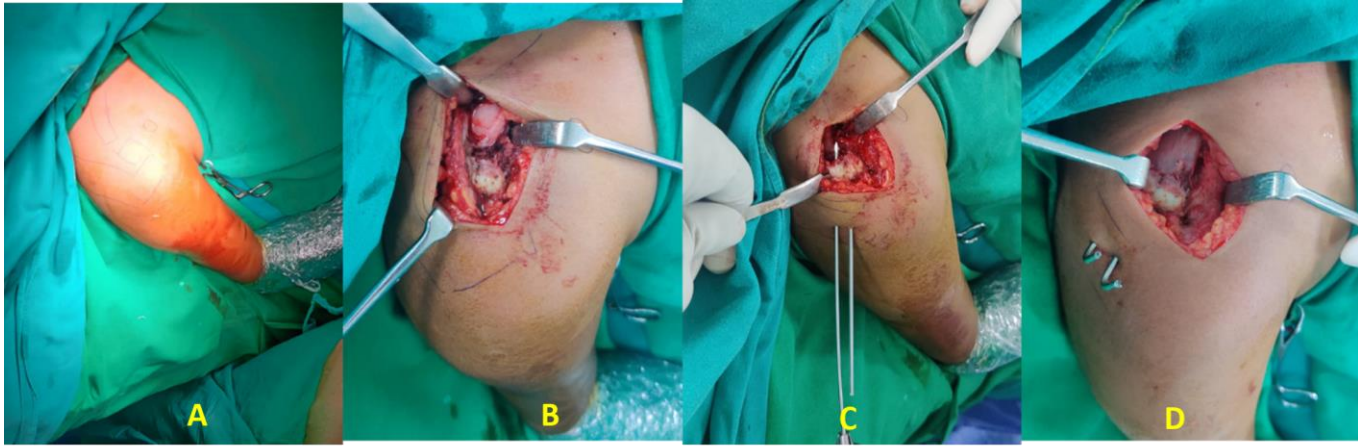


**Figure 2:** Post-injury radiograph showing segmental right clavicle fracture.

The treatment plan was explained to the parents of the patient, and their informed consent was taken. The plan was a surgical fixation of lateral physeal injury given gross displacement and conservative management of midshaft fracture because of minimal displacement. She was treated surgically by open reduction and k wire fixation of lateral physeal fracture under general anaesthesia (Figure 3, Figure 4). The torn periosteal sleeve was repaired around the lateral end of the clavicle. She was given arm pouch immobilization for four weeks, followed by shoulder and elbow joints' active mobilization.

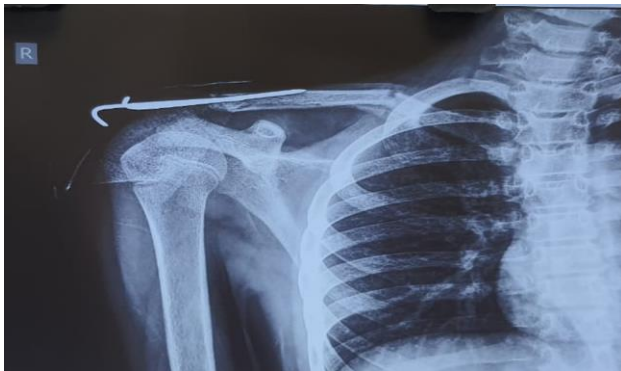

**Figure 3:** Post-operative radiographs showing well reduced right clavicle fractures with k wire fixation of the lateral end.

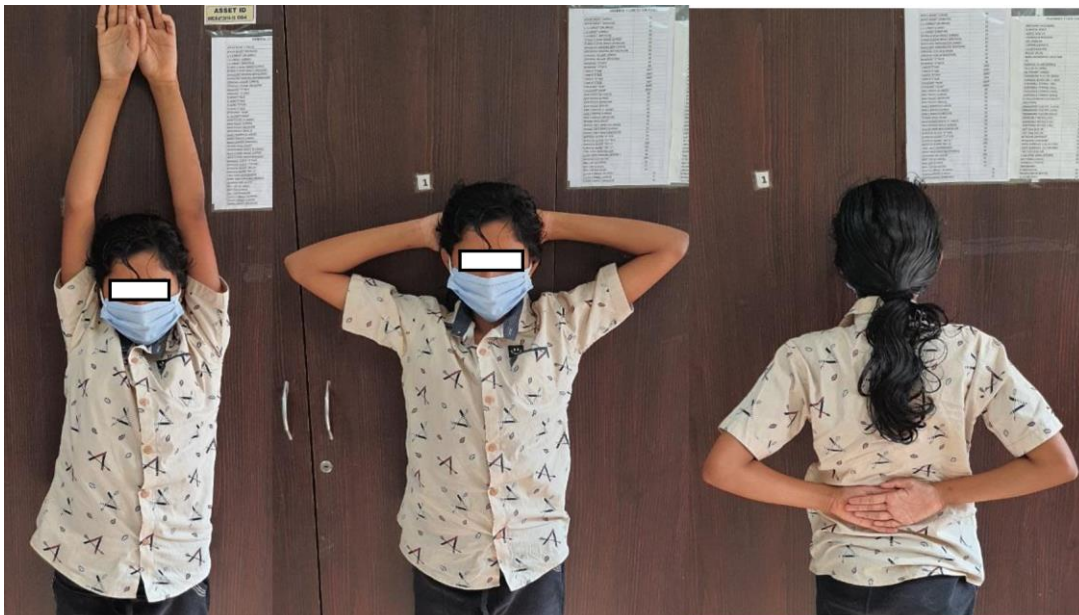


**Figure 4:** Intra-operative photographs. **A:** Patient in a beach chair position with landmarks marked; **B:** Gross displacement of fractured lateral ends noted; **C& D:** Fracture reduced and stabilized with two k wires.

Follow-up radiographs at six weeks revealed the fractures' consolidation, and hence k wires were removed (Figure 5). There were no complications. At the end of eight weeks, the patient had complete range of motion at shoulder and elbow joints and was able to return to preinjury activity levels (Figure 6).



**Figure 5:** Radiographs at six weeks of follow-up showing fracture consolidation and maintenance of good alignment of the right clavicle.



**Figure 6:** Clinical picture showing complete recovery of right shoulder and elbow movements.

**DISCUSSION**

Clavicle fractures account for 8 to 15% of all pediatric fractures (5). Isolated clavicle fractures are believed to result from a direct force onto the tip of the shoulder, most commonly the result of a simple fall or sports injury (6). The vast majority of these injuries can be treated nonoperatively with excellent results (7). The clavicle segmental and bipolar fractures are rare; only a few isolated cases have been reported in the literature (2). Most of them have been reported in adults. To the best of our knowledge, only one other case has been reported in an adolescent (8). Some have advocated surgical treatment of both fractures, reasoning that these are unstable injuries and prone to non-union and instability (1). Some of the reports advocate conservative treatment with excellent functional outcomes (2).

Injuries of the lateral end of the clavicle are rare, accounting for 10% of all pediatric clavicle fractures (1). They are commonly misinterpreted as acromioclavicular dislocation, although they are, in fact Salter-Harris type 2 fractures of lateral physis of the clavicle (8). What little material there is in the literature suggests that treatment should be determined by the degree of displacement of the metaphysis. Though minimally displaced fractures respond well to conservative treatment in terms of functional outcome, fractures with significant displacement can result in cosmetic deformity, which might persist into adulthood (8,9).

Mid-shaft fractures are generally treated non-operatively, although some authors argue that operative intervention improves functionality and reduces rates of non-union in displaced fractures (9). However, this needs to be weighed against the risk of surgical complications. In plate fixation of clavicle fractures, the vast majority of complications seem to be implant-related, with irritation or failure of the plate being consistently reported on in almost every study, on average ranging from 9 to 64% (10).

**CONCLUSION**

Even though clavicle fractures are common, the rare occurrence of segmental or bipolar injuries has to be kept in mind.

Generally, conservative treatment of midshaft clavicle fractures in paediatric patients produces an excellent functional outcome. However, unstable segmental/bipolar fractures and fractures involving the physis with displacement require surgical treatment. Lateral end clavicle fractures with significant displacement are better treated surgically to prevent cosmetic deformity.

**Conflict of interest**

No conflict of interest was declared by the authors.

**REFERENCES**

1. C. M. Robinson, "Fractures of the clavicle in the adult," *Journal of Bone and Joint Surgery B*, vol. 80, no. 3, pp. 476–484, 1998.
2. Sethi K, Newman SD, Bhattacharya R. An unusual case of bipolar segmental clavicle fracture. *Orthop Rev (Pavia)*. 2012;4(3):e26. doi:10.4081/or.2012.e26
3. L. A. Landin, "Fracture patterns in children. analysis of 8,682 fractures with special reference to incidence, etiology and secular changes in Swedish urban population," *Acta Orthopaedica Scandinavica*, vol. 54, supplement 202, pp. 1–109, 1983.
4. Stanley D, Trowbridge EA, Norris SH. The mechanism of clavicular fracture. A Clinical and biomechanical analysis. *J Bone Joint Surg Br* 1988;70:461-4.
5. D. Stanley and S. H. Norris, "Recovery following fractures of the clavicle treated conservatively," *Injury*, vol. 19, no. 3, pp. 162–164, 1988.
6. Daolagupu AK, Gogoi PJ, Mudiganty S. A rare case of segmental clavicle fracture in an adolescent. *Case Rep Orthop*. 2013;2013:248159. doi:10.1155/2013/248159.
7. Rockwood CA, Wilkin KE, Beaty JH. Rockwood fractures in children. Vol 3. Philadelphia:JB Lippincott, 1984.
8. Ogden J. Distal clavicular physeal injury. *Clin Orthop Relat Res* 1984;188:68–73.
9. Canadian Orthopaedic Trauma Society. Non-operative treatment compared with plate fixation of displaced midshaft clavicular fractures. A multicenter-randomized clinical trial. *J Bone Joint Surg Am* 2007; 89:1-10.
10. Wijdicks FJ, Van der Meijden OA, Millett PJ, Verleisdonk EJ, Houwert RM. Systematic review of the complications of plate fixation of clavicle fractures. *Arch Orthop Trauma Surg*. 2012;132(5):617-625.