

# NONINVASIVE POSITIVE PRESSURE VENTILATION AS A TREATMENT OF RESPIRATORY FAILURE DUE TO ARNOLD CHIARI TYPE I MALFORMATION

## ARNOLD CHIARI TİP I MALFORMASYONUNA BAĞLI SOLUNUM YETMEZLİĞİNİN TEDAVİSİNDE NONİNVAZİF POZİTİF BASINÇLI VENTİLASYON

Nurdan KÖKTÜRK, M.D., Salih KAYA\*, M.D., Gül GÜRSEL, M.D.,  
Ceyda Erel KİRİŞOĞLU, M.D., Memduh KAYMAZ\*, M.D.

Gazi University, Faculty of Medicine, Departments of Pulmonary Medicine and Neurosurgery\*,  
Ankara-Turkey

Gazi Medical Journal 2002; 13: 95-99

**SUMMARY:** Respiratory failure in Arnold Chiari Type I Malformation has only rarely been reported. In this case report, an 18-year-old male who had shown acute respiratory failure as a first sign of Arnold Chiari Malformation, was presented. The patient experienced a marked improvement in respiratory insufficiency with surgical decompression of the posterior fossa and noninvasive intermittent positive pressure support ventilation (NPPV). This report emphasizes; 1) Patients with respiratory failure not explained by pulmonary pathology should be evaluated for underlying neurological diseases. 2) In such cases, NPPV can be used as a life saving treatment modality and successfully applied for long-term respiratory support in Arnold Chiari Malformation.

**Key Words:** Arnold Chiari Malformations, Respiratory Failure, NPPV.

### INTRODUCTION

The Chiari I malformation (ACM) was first described by Chiari in 1891 as herniation of the cerebellar tonsils below the plane of the foramen magnum. Hydromyelia and syringomyelia of the cervical cord may be present and have been reported as poor prognostic factors (1). The most common symptoms are headache, weakness involving one or two limbs, diplopia, dysphagia, and unsteadiness. The most common signs are ataxia, hyperreflexia, motor weakness, lower cranial nerve paralysis, trophic changes, and Horner's Syndrome (2). Respiratory failure in ACM has been reported and usually requires invasive mechanical ventilation support, even

**ÖZET:** Arnold Chiari Tip I Malformasyonuna (ACM Tip I) bağlı solunum yetmezliği oldukça nadir gözlenir. Bu olgu sunusunda, ACM nun ilk bulgusu olarak akut solunum yetmezliği ile başvuran 18 yaşında bir erkek hasta sunulmuştur. Olgudaki solunum yetmezliği posterior fossanın cerrahi dekompresyonu ve noninvazif olarak uygulanan pozitif basınçlı ventilasyon (NPPV) ile belirgin olarak düzelmiştir. Bu raporda pulmoner patolojilerle açıklanamayan solunum yetmezliklerinin etiyolojisinde altta yatan bir nörolojik patolojinin olası varlığının mutlaka akla gelmesi gerektiği ve böyle olgularda NPPV'nun hayat kurtardığı ve uzun dönem solunum desteği için de iyi bir seçenek olduğu vurgulanmıştır.

**Anahtar Kelimeler:** Arnold Chiari Malformation Tip I, Solunum Yetmezliği, NPPV.

tracheostomy, in addition to decompression surgery (3, 4).

In this report, a patient who had been investigated for repeated intractable respiratory failure episodes was presented. He was ultimately diagnosed with ACM and syringomyelia and successfully treated with decompression of the posterior fossa and NPPV.

### CASE REPORT

An 18-year-old male was admitted to the emergency room (ER) for evaluation of loss of consciousness. The patient was noted to experience grand mal seizure and respiratory arrest following admittance to the ER. Chest

auscultation and X-Ray findings were unremarkable. The arterial blood gas analysis revealed hypercapnic and hypoxic respiratory acidosis (pH: 7.37, arterial carbon dioxide tension (PaCO<sub>2</sub>): 52.7 mmHg, arterial oxygen tension (PaO<sub>2</sub>): 52 mmHg). The patient underwent invasive mechanical ventilation through an endotracheal tube. Three attempts at extubation were made over the following 7 days, each of which resulted in hypercapnic respiratory failure. He was referred to the Respiratory Intensive Care Unit (RICU) for further evaluation of untractable respiratory failure.

Upon transfer to RICU the patient was extubated. Respirations: 10/min, frequent central apneas were present. Pulse: 120/min. Blood pressure: 120/80 mmHg. Low hair-line, short neck, micrognathia, right-sided ptosis, enophthalmus and facial asymmetry, elevated soft palate and hoarseness were noticed. Laryngoscopy revealed left vocal cord paralysis. Chest examination revealed diminished breath sounds bilaterally. Genitourinary system examination revealed bilateral gynecomastia and mildly atrophic testes. Neurological examination revealed paralysis of 9<sup>th</sup>, 10<sup>th</sup>, and 11<sup>th</sup> cranial nerves, horizontal nystagmus to the right, wasting and weakness of the shoulder girdle, right hemiparesis, brisk jerks, extensor plantar response on the right and ataxic gait.

In the history, the patient reported experiencing difficulties in walking for 10 days and headache, hypersomnolence and snoring for 6 months prior to admittance. No previous witnessed apneic episodes had been observed. He denied any respiratory symptoms.

Following admittance to the RICU, frequent central and obstructive apneas were noted. Unfortunately, we had no opportunity to obtain a polysomnography to make an exact diagnosis of the apneas. In the follow up period, even though ABG analysis had revealed marked hypercapnia and mild hypoxemia, he did not undergo intubations again (pH: 7.39, PaCO<sub>2</sub>: 63.5 mmHg, PaO<sub>2</sub>: 56.8 mmHg, SaO<sub>2</sub>: 89.6). Instead, pressure support ventilation was applied via a facemask (Pressure support (PS): 15 cmH<sub>2</sub>O, Positive End Expiratory Pressure (PEEP): 5 cmH<sub>2</sub>O without O<sub>2</sub> supplementation. He needed less frequent

applications each day. A six-hour noninvasive mechanical ventilation period was established for maintenance. The maintenance settings allowed ABG revealing PaCO<sub>2</sub>: 40 mmHg and PaO<sub>2</sub>: 80 mmHg approximately.

The following diagnostic procedures were obtained for the differential diagnosis: PFT: Forced vital capacity (FVC): 2.07 L (53 % of predicted), forced expiratory volume in one second (FEV1): 1.84 L (51 % of predicted), FEV1 /FVC: 89%, carbon monoxide diffusing capacity (DLCO): 80 % of predicted, maximal inspiratory pressure (PiMax): 24 cmH<sub>2</sub>O, maximal expiratory pressure (PeMax): 67 cmH<sub>2</sub>O. Echocardiography: normal. X-ray of the skull showed platybasia. Spinal X-ray showed thoracic scoliosis. Cranial and Cervical Magnetic Resonance Imaging (MRI) revealed syringomyelia, caudal displacement of the cerebellum through the foramen magnum and partially empty sella (Fig. 1). According to these analyses, the patient was diagnosed with ACM type I, Syringomyelia as a cause of neurological findings, respiratory insufficiency and apneic episodes. In order to evaluate the endocrinological findings, a standard pituitary function study and the serum level of free testosterone were obtained. All except testosterone 4.95 pg/ml, (Normal range: 8.69-54.69 pg/ml) were within the normal range. Because of the positive luteinizing hormone (LH) stimulation test, the diagnosis of secondary

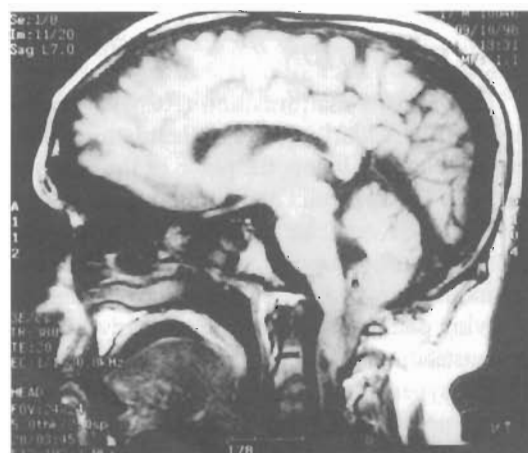


Fig. 1: Midsagittal sections of MRI demonstrates cerebellar tonsillar herniation and cervical syrinx formation

hypogonadism due to a partially empty sella was made. Cytogenetic analysis (46, XY) excluded the diagnosis of Klinefelter's Syndrome. The patient underwent posterior fossa craniectomy and C1-C3 total laminectomy for the treatment of ACM Type I (Fig. 2).

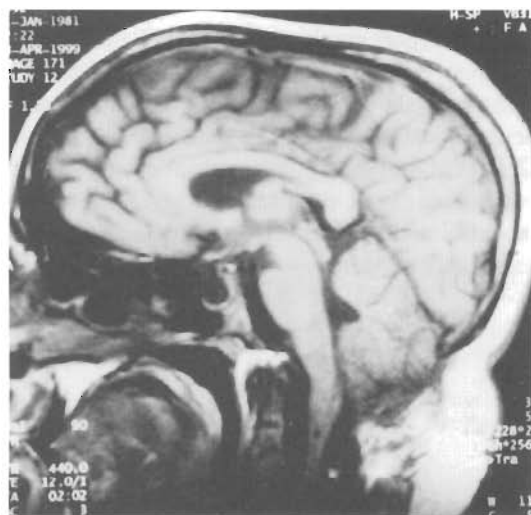


Fig. 2: Postoperative MRI demonstrates decompression of the posterior fossa, cerebellar tonsils and improvement of the cervical syrinx.

Immediately after the operation, the blood gas analysis showed mild hypercapnia and mild hypoxemia (pH: 7.39, PaCO<sub>2</sub>: 46.7 mmHg, PaO<sub>2</sub>: 56 mmHg). The patient was noted to have decreased frequency of apneic episodes but continue to require respiratory support. Three weeks after the operation, the patient was discharged with pressure controlled bilevel positive airway pressure home ventilator (BIPAP ST, Respironics; Murrysville, PA) (Settings: PS: 12 cmH<sub>2</sub>O, PEEP: 4 cmH<sub>2</sub>O). He has had no respiratory failure episodes since he was discharged. ABG has been steady at PaO<sub>2</sub>: ~60 mmHg, PaCO<sub>2</sub>: ~50 mmHg. PFT has improved. FVC: 3.3 L (78 % of predicted) FEV1 3.4 L (83 % of predicted); DLCO 84 % of predicted, PiMax: 50 cmH<sub>2</sub>O, PeMax: 44 cmH<sub>2</sub>O). He started walking and running without help, his hoarseness ceased and his social life became more active.

## DISCUSSION

Respiratory centers in the brainstem which

receive information on metabolic status from the peripheral chemoreceptors via afferent nerve fibres, and project efferent fibres to the motor nuclei innervating the respiratory muscles are mainly involved in the control of breathing (4). Nucleus tractus solitarius, the inspiratory and expiratory neurons located at several nuclei, the effector motor neurons to the diaphragm and intercostal muscles also have major roles in respiration (5). Herniated tonsils or a syrinx may damage these structures by either direct brainstem compression or stretching of the cranial nerves (5).

Cases with vocal cord or diaphragmatic paralysis due to dysfunction of cranial nerve IX or phrenic nerve commonly present with ACM and syringomyelia (3, 6-8). Those cases are commonly manifested by respiratory distress, obstructive apneas and recurrent aspirations (7-11). Sleep abnormalities in ACM and syringomyelia have also been implicated due to compression of the brainstem and ascending and descending pathways (12).

Our case experienced left vocal cord paralysis, hoarseness, snoring, and mixed type apnea. He has been noted to have no hoarseness and snoring after the operation and NPPV therapy. He also had evidence of dysfunction of the phrenic nerve, shown by the restrictive pattern of the PFT and low value of PiMax and PeMax. Repeated tests have shown improvement of those parameters 2 years after the operation under the NPPV therapy.

There have been several mechanisms which have been attributed to respiratory failure in ACM. For example, Bokinsky et al presented a case with respiratory failure associated with ACM and Syringomyelia that was attributed to compression of the medulla and the insensitivity of peripheral chemoreceptors resulting from lesions of the 9<sup>th</sup> cranial nerve (7, 13). In this case respiratory insufficiency was attributed to impaired hypoxic drive. In some other cases ventilatory insensitivity to CO<sub>2</sub> has been reported to be associated with ACM (6). Alvarez et al has described a case with alveolar hypoventilation and sleep apnea associated with syringomyelia. The patient experienced acute respiratory failure as a first sign of syringomyelia (4). Nogues et al has stressed the risk of sudden death during sleep

in syringomyelia (5).

In the present case, the respiratory failure is mainly attributed to the compression of medullar structures by the herniation of cerebellar tonsils. Additionally, cranial nerve nuclei and ascending and descending afferent pathways might be impaired by syringomyelia and medullary compression. This may contribute to the mechanism of alveolar hypoventilation (ABG samples have typically shown alveolar hypoventilation pattern) and central and obstructive apneas. Although we could not confirm the occurrence of the apneas by polysomnography, we had observed that both obstructive and central apneas frequently occurred. Furthermore, the patient had evidence of weakness of the shoulder girdle and respiratory muscles and clinical involvement of the 9<sup>th</sup>, 10<sup>th</sup>, and 11<sup>th</sup> cranial nerves. When we considered that the syrinx extended to the level of C3, it was postulated that the phrenic nerve had also been affected in our case.

Interestingly, this patient also had some findings of hypogonadism and partially empty sella syndrome. The association of ACM and endocrinopathies has rarely been reported. The relationship of ACM with acromegaly and hypopituitarism has been so far described as occasional cases (14-16). The pathogenesis of hypopituitarism with syringomyelia and ACM has been explained by the mechanisms of cerebrospinal trauma by a breech delivery and congenital anomaly (14). The present case experienced endocrinological abnormalities manifested by gynecomastia and mild testicular atrophy, partially empty sella and low serum levels of testosterone with positive LH stimulation test. We speculate that it might have been a congenital developmental dysfunction that occurred in the same period that ACM was developed.

Another interesting point of this case is that the patient had not been aware of his disease despite subtle clinical manifestations over a period of time. Ultimately, the disease was manifested as a life-threatening episode of respiratory failure as a first severe sign. Secondly, it is remarkable that noninvasive mechanical ventilation has been successfully applied, instead of invasive mechanical ventilation in acute and chronic respiratory failure. Since he continued to

require respiratory support and we were aware that so many cases had suddenly died during sleep after decompression surgery, we decided to continue to NPPV as a long term therapy. The possible mechanism of NPPV is simply supporting the respiratory muscles (17) and preventing apneas and sudden death during sleep.

This report emphasizes that; 1) Patients with respiratory failure not explained by pulmonary pathology should be evaluated for underlying neurological diseases. 2) In such cases of Arnold Chiari Malformation; noninvasive mechanical ventilation can be used as a life saving treatment modality and successfully applied for long-term respiratory support.

**Correspondence to:** Nurdan KÖKTÜRK, M.D.  
Kızıllırmak Sok. 16/10  
Kocatepe  
06640 ANKARA - TÜRKİYE  
Phone : 312 - 425 15 80  
Fax : 312 - 212 90 19  
e-mail: nurdank@yahoo.com

#### REFERENCES

1. Bindal AK, Dunsker SB, Tew JM. Chiari I Malformation: Classification and Management. *Neurosurgery* 1995; 37: 1069-1074.
2. Paul KS, Lye RH, Strang FA, Dutton J. Arnold Chiari Malformation. *J Neurosurgery* 1983; 58: 183-187.
3. Ruff ME, Oakes Wj, Samuel RF, Spock A. Sleep apnea and vocal cord paralysis, secondary to Type I Chiari Malformation. *Pediatrics* 1987; 80: 231-234.
4. Alvarez D, Requena I, Arias M, Valdes L, Pereiro I, De La Torre R. Acute respiratory failure as the first sign of Arnold Chiari Malformation associated with syringomyelia. *Eur Respir J* 1995; 8: 661-663.
5. Nogue's MA, Gene' R, Encabo H. Risk of sudden death during sleep in syringomyelia and syringobulbia. *Journal of Neurology, Neurosurgery, and Psychiatry* 1992; 55: 585-589.
6. Montserrat JM, Picado C, Agusti-Vidal A. Arnold Chiari Malformation and paralysis of the diaphragm. *Respiration* 1988; 53: 128-131.

7. Bullock R, Todd NV, Easton J, Hadley D. Isolated central respiratory failure due to syringomyelia and Arnold Chiari Malformation. *BMJ* 1988; 297; 1448-1449.
8. Allsopp GM, Karkanevatos A, Bickerton C. Abductor vocal cord palsy as a manifestation of type one Arnold Chiari Malformation. *The Journal of Laryngology and Otology* 2000; 114; 221-223.
9. Haponik EF, Givens D, Angelo J. Syringobulbia-myelia with obstructive sleep apnea, *Neurology* 1983; 33; 1046-1049.
10. Nathadwarawala K, Richards CA, Lawrie B, Thomas GO, Wiles CM. Recurrent aspiration due to Arnold- Chiari Type I Malformation. *BMJ* 1992; 304; 565-566.
11. Doherty MJ, Spence DPS, Young C, Calverley PMA. Obstructive sleep apnoea with Arnold- Chiari Malformation. *Thorax* 1995; 50; 690-691.
12. Botelho RV, Bittencourt LRA, Rotta JM, Tufik S. Polysomnographic respiratory findings in patients with Arnold- Chiari Type I Malformation and basilar invagination, with or without syringomyelia: preliminary report of a series of cases. *Neurosurg Rev* 2000; 23; 151-155.
13. Bokinsky GE, Hudson LD, Weil JV. Impaired peripheral chemosensitivity and acute respiratory failure in Arnold Chiari Malformation and Syringomyelia. *The New England Journal of Medicine* 1973; 3; 947-949.
14. Fujita K, Matsuo N, Mori O, Koda N, Mukai E, Okabe Y, Shikarawa N, Tamai S, Itaga Y, Hibi I. The association of hypopituitarism with small pituitary, invisible pituitary stalk. Type I Arnold Chiari Malformation, and syringomyelia in seven patients born in breech position: a further proof of birth injury theory on the pathogenesis of "idiopathic hypopituitarism". *Eur J Pediatr* 1992; 151; 266-270.
15. Agostinis C, Caverni L, Montini M, Pagani G, Bonaldi G. Spontaneous reduction of tonsillar herniation in acromegaly: A Case Report. *Surg Neurol* 2000; 53; 396-399.
16. Takakuwa S, Asai A, Igarashi N. A case of syringomyelia with Type I Arnold-Chiari Malformation (ACM): Growth hormone (GH) therapy and the size of syrinx on serial MR images. *Endocrine Journal* 1996; 43(suppl); S129-S130.
17. Seliger GM, Zackson H, Nichols L, Gold E, Nishimoto M. Neurological improvement following respiratory support in syringomyelia: Case report. *Paraplegia* 1990; 28; 526-528.