

INTESTINAL PERFORATION IN HIRSCHSPRUNG'S DISEASE: A REPORT OF THREE CASES

Nedim GÖZAYDIN, Mete KAYA, Mehmet Emin BOLEKEN, Turan KANMAZ, Selçuk YÜCESAN,

Hirschsprung's disease is a common cause of intestinal obstruction in the newborn period. An important complication of Hirschsprung's disease is perforation of the bowel associated with obstruction. Herein, we report three consecutive newborns with Hirschsprung's disease presenting with intestinal perforation, and discuss its pathogenesis.

Key Words: Hirschsprung's disease, intestinal perforation, appendix perforation, newborn

HIRSCHSPRUNG HASTALIĞINDA BAĞIRSAK PERFORASYONU: ÜÇ OLGUNUN SUNUMU

Hirschsprung hastalığı, yenidoğan döneminde bağırsak tıkanıklığının en önemli nedenlerinden biridir. Hirschsprung hastalığının önemli komplikasyonu tıkanıklık ile birlikte olan bağırsak perforasyonudur. Bu yazıda bağırsak perforasyonu ile bulgu veren Hirschsprung hastalığı olan üç olguyu sunmayı, bu durumun patogenezi tartışmayı amaçladık.

Anahtar Kelimeler: Hirschsprung hastalığı, bağırsak perforasyonu, apandiks perforasyonu, yenidoğan

Hirschsprung's disease (HD) is characterized by the absence of ganglion cells in the distal bowel beginning at the internal sphincter and extending proximally for varying distances (1). HD is a common cause of intestinal perforation in the neonatal period. A review of the literature indicates the rarity of perforation of the bowel in HD and the difficulty of treatment (3-5). In this case report, we present three consecutive newborns with intestinal perforation due to HD, and discuss the pathogenesis of this complication.

CASE 1

A 6-day-old girl was admitted with symptoms of intestinal obstruction, namely poor feeding, bilious vomiting and abdominal distention, lasting two days. She did not pass meconium for the first 2 days of life. She had symptoms of mechanical intestinal obstruction on physical examination, and a plain abdominal X-ray revealed intra-abdominal free air (Fig. 1). Following fluid resuscitation and the initiation of broad spectrum antibiotics, she underwent a laparotomy with the diagnosis of intestinal perforation.

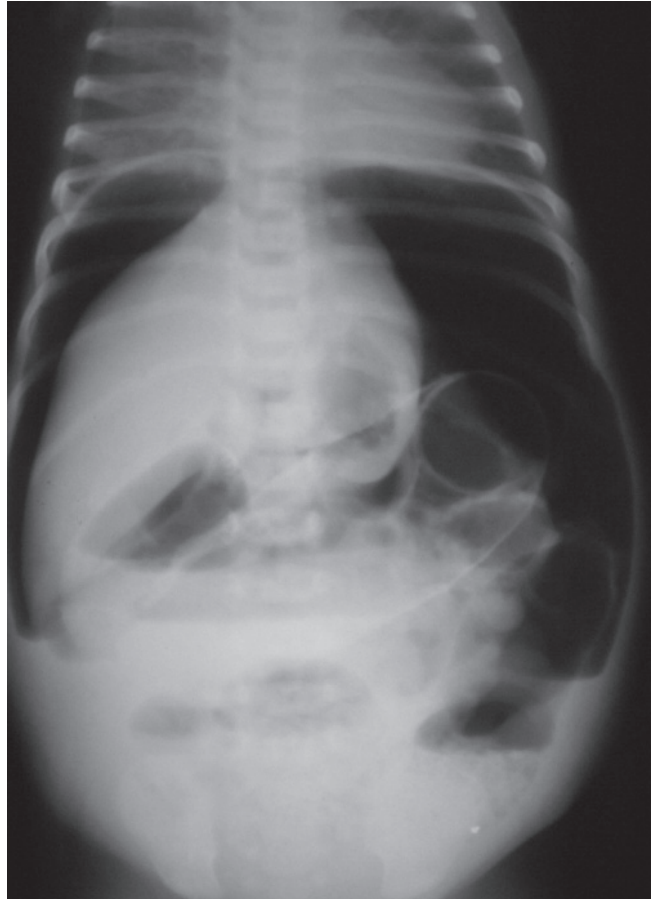


Fig. 1: A plane radiograph of the newborn reveals intra-abdominal free air and multiple air-fluid levels.

During the laparotomy ascending colon perforation was detected. No transition segment was observed. Loop colostomy was performed at the site of the perforation. Multiple biopsies were obtained from different parts of the colon. A specimen from the ascending colon showed ganglion cells and the sigmoid colon showed no ganglion cells. Nine months after the initial presentation, the patient, who was diagnosed with HD, underwent laparotomy accompanied with frozen biopsies, and the transition segment was found at the proximal sigmoid colon. The Soave-Boley procedure was performed for definitive surgery. The postoperative period was uneventful. The colostomy was closed two months later. She remained well during the one-year follow-up.

CASE 2

A girl was born at full term. On the 30th day of life she presented with bilious vomiting, poor feeding, and lethargy lasting one week. She had had a distended and tender abdomen for 2 days, and meconium was passed on the 3rd day of life. An abdominal X-ray revealed free air under the diaphragms and air-fluid levels. During the laparotomy, appendiceal perforation was detected at the base of the appendix. No dilatation was observed in bowel segments proximal or distal to the perforation site. An appendectomy and ileostomy were performed. Multiple biopsies were taken from different parts of the intestine. The pathology specimen of the appendix and

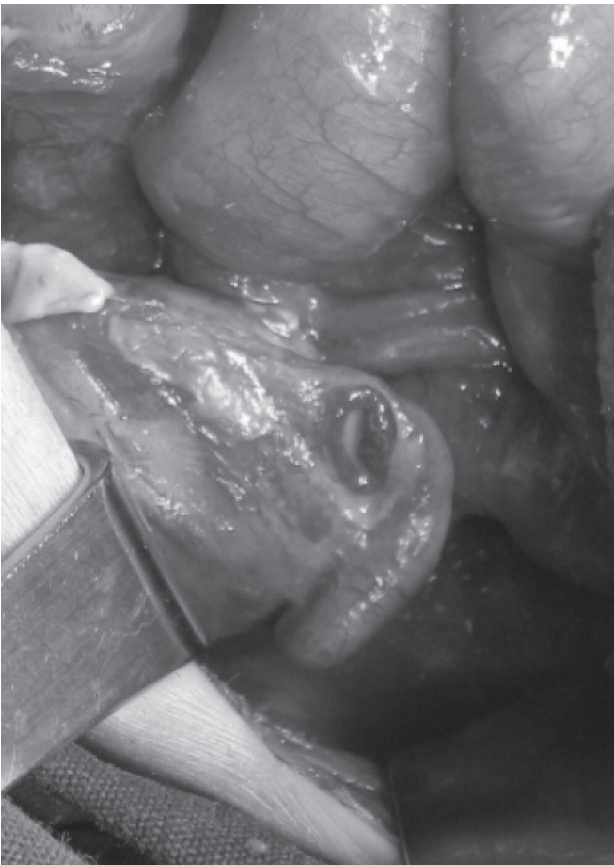


Fig. 2: An intra-abdominal photograph shows perforation of the appendix base.

ileum showed ganglion cells, and the sigmoid colon showed no ganglion cells. She stayed in hospital for 2 weeks postoperatively because of wound infection. She was discharged, and was well during the 2-month follow-up. She is waiting for a definitive operation.

CASE 3

An 8-day-old male newborn presented with abdominal distention and bilious vomiting lasting one day. Upon examination, he had poor crying, low activity, failed sucking and depressed neonatal reflexes. The most obvious finding was abdominal distention. The bowel sounds were hypoactive. The passage of meconium was delayed for 2 days. A plain abdominal radiograph showed intra-abdominal free air. Following adequate fluid replacement and the initiation of broad spectrum antibiotics, she underwent a laparotomy. During surgery, perforations in the descending colon and at the base of appendix were detected (Fig. 2). Mild dilatation was determined in the transverse colon. Primary repair of the descending colon, appendectomy and ileostomy were performed. Pathology specimens were taken from bowel segments. A biopsy from the ileum showed ganglion cells, but the appendix and sigmoid colon showed no ganglion cells. She recovered without complications and was discharged in good health. She is waiting for definitive surgery.

DISCUSSION

An important complication of HD, which occurs in 4% of patients, is bowel perforation, especially in the neonatal period. However, perforation is a rare initial diagnosis in HD (2). Since, to date, no prenatal diagnosis of HD has been possible until a pathological examination of the bowel biopsy after birth, and clinical symptoms are confounding variables in the diagnosis of HD in the neonatal period, an early diagnosis may not be possible (3,6). As in our cases, initial symptoms and laparotomy findings of newborns with HD indicate an intestinal obstruction and perforation; therefore it requires further investigation to exclude HD in these patients.

Although the pathogenesis of intestinal perforation in HD is still unknown, most studies have proposed that inflammation may play a major role in its development in bowel obstruction base (2). Intestinal obstruction and enterocolitis result from an inflammatory process of the mucosa of the colon or small intestine in HD. As the disease progresses, the lumen of the intestine becomes filled with fibrinous exudates and is at increased risk for perforation. Perforations most commonly occur in the proximal colon (68%), the appendix (17%), or the distal small bowel (6%); additionally, bowel perforations may occur in both the aganglionic and ganglionic portion of the bowel in HD. It was reported that this complication is most commonly associated (62%) with total aganglionosis (3,8). On the other hand, while the perforation site in patients with a short or intermediate length HD has been detected proximal to or at the site of transition, in 84% of infants with total

colonic aganglionosis it was found in the aganglionic bowel segment (3). In the present case reports, perforations were detected proximal to the aganglionic segment in cases one and two, which involved intermediate length HD; however, in the third case, with total colonic aganglionosis, perforations were found in the aganglionic segment.

In our study, two of the perforation sites were detected in the appendix. Although it is reported that appendix perforation in newborns may be related to HD, the relationship between HD and appendix perforation is not clear (2-7). Sarioglu et al. found that only 0.66% of patients with HD were admitted with appendiceal perforation (2). Arliss et al. (4) applied Laplace's law to those cases with appendiceal perforation together with HD to explain the site of perforation without inflammation, and proved that it should be at the base of the appendix. If Laplace's law and the possibility of a thinner anatomic area at the base of the appendix are combined, the perforation site at the base of appendix can be explained. Both of the appendiceal perforations in this study were at the base of the appendix. Nevertheless, the proposed mechanisms for appendiceal perforation remain speculative.

The mortality associated with HD seems to be higher among patients admitted with appendiceal and colonic perforations. The clinical courses of cases reported in the literature have been mostly lethal (2,7). Although the treatments of two of our patients have not been completed, all of them are still alive and healthy. We thought that our success rate was based on an early diagnosis and developed neonatal intensive care units.

In conclusion, intestinal perforation is a rare presenting mode of HD, and it is seen especially in long segment HD. The mechanism of perforation is still unknown. Therefore, unexplained perforations of the colon, appendix, or small bowel are an indication for investigations to exclude HD.

Correspondence Address

Mete KAYA

Harran University School of Medicine

Department of Pediatric Surgery 63100 - Sanliurfa, TURKEY

Phone: 414 341 00 82

Fax: 414 315 11 81

E-mail: kayamete@yahoo.com

KAYNAKLAR

1. Lall A, Gupta DK, Bajpai M. Neonatal Hirschsprung's disease. Indian J Pediatr 2000; 67: 583-588.
2. Sarioglu A, Tanyel FC, Buyukpamukcu N, Hicsonmez A. Appendiceal perforation: a potentially lethal initial mode of presentation of Hirschsprung's disease. J Pediatr Surg 1997; 32: 123-124.
3. Newman B, Nussbaum A, Kirkpatrick JA Jr. Bowel perforation in Hirschsprung's disease. AJR Am J Roentgenol 1987; 148: 1195-1197.
4. Arliss J, Holgersen LO. Neonatal appendiceal perforation and Hirschsprung's disease. J Pediatr Surg 1990; 25: 694-695.
5. Teitebaum DH, Coran AG, Weitzman JJ, Ziegler MM, Kane T. Hirschsprung's Disease and Related Neuromuscular Disorders of the Intestine. In: O'Neill JA, Rowe MI, Grosfeld JL, Fonkalsrud EW, Coran AG (eds): Pediatric surgery. 5th ed. Missouri: Mosby-Year Book Inc; 1998. p. 1381-1418.
6. Newman B, Nussbaum A, Kirkpatrick JA Jr, Colodny A. Appendiceal perforation, pneumoperitoneum, and Hirschsprung's disease. J Pediatr Surg 1988; 23: 854-856.
7. Managoli S, Chaturvedi P, Vilhekar KY, Gupta D, Ghosh S. Perforated acute appendicitis in a term neonate. Indian J Pediatr 2004; 71: 357-358.
8. Das Narla L, Hingsbergen EA. Case 22: total colonic aganglionosis-long-segment Hirschsprung disease. Radiology 2000; 215: 391-394.