

Immune Thrombocytopenia Treated with Intravenous Erythromycin

İntravenöz Eritromisin ile Tedavi Edilen İmmün Trombositopeni

Masashi Ohe¹, Ken Furuya¹, Houman Goudarzi²

¹Department of Internal Medicine, JCHO Hokkaido Hospital, Sapporo, Japan

²Department of Respiratory Medicine, Faculty of Medicine and Graduate School of Medicine, Hokkaido University, Sapporo, Japan

ABSTRACT

Macrolides (MACs) such as clarithromycin (CAM) and erythromycin (EM) have immunomodulatory effects as well as anti-bacterial activity. In consideration of immunomodulatory effects, we report a patient with primary immune thrombocytopenia (ITP) treated with corticosteroids (CSs) combined with MACs. An 84-year-old woman with ITP was admitted to our hospital for further examination of reduced platelet counts. After admission, the patient was diagnosed with exacerbated primary ITP. The patient was successfully treated with intravenous immunoglobulin. However, the patient was unsuccessfully treated with CSs (i.e., prednisolone (PSL) and methyl PSL) combined with CAM. Eltrombopag (ELT), a thrombopoietin-receptor agonist, was successfully added. However, the patient suffered from aspiration pneumonia, making it impossible to administer oral drugs (i.e., PSL, CAM, and ELT). Alternatively, she was successfully treated with intravenous PSL combined with intravenous EM. This case shows that the efficacy of intravenous EM treatment may be higher than that of oral CAM treatment.

Keywords: Immune thrombocytopenia, clarithromycin, erythromycin, prednisolone, bioavailability

Received: 06.01.2020

Accepted: 07.03.2021

ÖZET

Klaritromisin (CAM) ve eritromisin (EM) gibi makrolidler (MAC'ler), anti-bakteriyel aktivitenin yanı sıra immünomodülatör etkilere sahiptir. İmmünomodülatör etkileri göz önünde bulundurularak, MAC'lerle kombine kortikosteroidler (CS'ler) ile tedavi edilen primer immün trombositopenisi (ITP) olan bir hastayı sunuyoruz. 84 yaşında ITP'li kadın hasta, trombosit sayısında azalma olup olmadığı ileri tetkik için hastanemize başvurdu. Başvurudan sonra hastaya alevlenmiş primer ITP teşhisi kondu. Hasta intravenöz immünoglobulin ile başarılı bir şekilde tedavi edildi. Ancak hasta, CAM ile kombine edilmiş CS'ler (yani prednizolon (PSL) ve metil PSL) ile başarısız bir şekilde tedavi edildi. Bir trombopoietin-reseptör agonisti olan Eltrombopag (ELT) başarıyla eklendi. Bununla birlikte, hasta aspirasyon pnömonisinden muzdarıptı, bu da oral ilaçların (yani, PSL, CAM ve ELT) uygulanmasını imkansız hale getirdi. Alternatif olarak, intravenöz EM ile kombine intravenöz PSL ile başarılı bir şekilde tedavi edildi. Bu durum intravenöz EM tedavisinin etkinliğinin oral TAT tedavisine göre daha yüksek olabileceğini göstermektedir.

Anahtar Sözcükler: İmmün trombositopeni, klaritromisin, eritromisin, prednizolon, biyoyararlanım

Geliş Tarihi: 01.06.2020

Kabul Tarihi: 03.07.2021

ORCID IDs: M.O. 0000-0002-6684-6688, K.F. 0000-0003-3373-4337, H.G. 0000-0003-1145-8917

Address for Correspondence / Yazışma Adresi: Masashi Ohe, MD, Department of Internal Medicine, JCHO Hokkaido Hospital, Sapporo, Japan E-mail: oekts1218@sweet.ocn.ne.jp

©Telif Hakkı 2021 Gazi Üniversitesi Tıp Fakültesi - Makale metnine <http://medicaljournal.gazi.edu.tr/> web adresinden ulaşılabilir.

©Copyright 2021 by Gazi University Medical Faculty - Available on-line at web site <http://medicaljournal.gazi.edu.tr/>

doi:<http://dx.doi.org/10.12996/gmj.2021.129>

INTRODUCTION

Macrolides (MACs) such as clarithromycin (CAM) and erythromycin (EM) have not only anti-bacterial activity but also immunomodulatory effects, and anti-inflammatory effects. In connection with its immunomodulatory effects, we have previously reported several cases of immune thrombocytopenia (ITP) successfully treated with CAM or EM (1–4). Here, we report a case of primary ITP treated with corticosteroids (CSs) (i.e., prednisolone (PSL) and methyl PSL) combined with CAM, and subsequently intravenous PSL combined with intravenous EM.

CASE REPORT

An 84-year-old woman with ITP accompanied by osteoporosis, and Alzheimer's disease was referred and admitted to our hospital for further examination of reduced platelet counts ($0.7 \times 10^4 / \mu\text{L}$) on PSL (5 mg/day). After admission, the patient complained of genital bleeding. Physical examination revealed subcutaneous bleeding on bilateral upper and lower extremities. Her laboratory results included the following: white blood cell counts, $7,370 / \mu\text{L}$ (basophils, 0.1%; eosinophils, 0.4%; neutrophils, 69.1%; lymphocytes, 22.3%; monocytes, 7.1%); hemoglobin, 9.7 g/dL; platelet counts, $0.6 \times 10^4 / \mu\text{L}$; C-reactive protein, 0.48 mg/dL; immunoglobulin (Ig) G, 942 mg/dL; IgM, 111 mg/dL; IgA, 121mg/dL; fasting blood sugar, 116 mg/dL; and hemoglobin A1c, 6.1%. Neither antinuclear antibody nor rheumatoid factor was detected. She was negative for *Helicobacter pylori* (HP) stool antigen using the enzyme-linked immunosorbent assay and for HP IgG antibodies. A bone marrow aspiration smear revealed normal bone marrow with a nucleated cell count of $8.9 \times 10^4 / \mu\text{L}$ and a megakaryocyte count of $132 / \mu\text{L}$ without dysplasia or hemophagocytosis (Figure 1). No abnormal findings suggestive of infection were found in the systemic survey, including the chest roentgenogram and urinalysis. Based on these findings, the patient was diagnosed with exacerbated primary ITP. The clinical course is shown in Figure 2. On the first day of admission, she received platelet transfusion. On the second day, she was treated with intravenous immunoglobulin (IVIG) (15 g/day for 5 days). Five days after the IVIG treatment, the platelet counts increased to $25.5 \times 10^4 / \mu\text{L}$. Because the patient suffered from osteoporosis that is exacerbated by the use of PSL, the PSL dosage was only increased from 5 to 10 mg/day after the IVIG treatment. Simultaneously, we prescribed CAM (400 mg/day) based on its immunomodulatory effects to increase platelet counts (1–4) and steroid-sparing effects via its influence on CSs metabolism (5). Thereafter, she was discharged. About a month after her discharge, she was readmitted for reduced platelet counts ($1.1 \times 10^4 / \mu\text{L}$) on PSL (10 mg/day) combined with CAM (400 mg/day). She received immediately platelet transfusion. She was then treated with intravenous methyl PSL (250 mg/day) for three days, and subsequently PSL (20 mg/day). Although the platelet counts increased to $16.4 \times 10^4 / \mu\text{L}$ a week after the methyl PSL treatment, it decreased again to $1.8 \times 10^4 / \mu\text{L}$. Eltrombopag (ELT) (12.5 mg/day), a thrombopoietin-receptor agonist, was added. Because the platelet counts did not increase, she received platelet transfusion. Thereafter, she was again treated with intravenous methyl PSL (250 mg/day) for three days, and subsequently PSL (30 mg/day). Simultaneously, the CAM dosage was increased to 800 mg/day. However, this time, the platelet counts did not increase, and remained at a level of around $1.0 \times 10^4 / \mu\text{L}$; therefore, she received platelet transfusion. The ELT dosage was increased to 25 mg/day, and the PSL dosage was reduced to 20 mg/day. One week after the ELT (25 mg/day) treatment, the platelet counts increased to $2.6 \times 10^4 / \mu\text{L}$. During the clinical course, she had a gradual dysphagia and then was diagnosed with aspiration pneumonia. Therefore, above-mentioned oral drugs (i.e., PSL, CAM, and ELT) were discontinued. Alternatively, she was given intravenous PSL (10 mg, twice daily), and ceftriaxone (CTRX) (1 g, twice daily) for aspiration pneumonia. Contrary to our expectations, the platelet counts temporarily increased to $3.2 \times 10^4 / \mu\text{L}$. As the pneumonia grew better, the platelet counts decreased to $1.5 \times 10^4 / \mu\text{L}$. As an alternative to CTRX, intravenous EM (0.5 g, twice daily) was started, expecting its immunomodulatory effects as well as its anti-bacterial activity. Three days after the intravenous EM treatment, the platelet counts increased to $2.4 \times 10^4 / \mu\text{L}$. Even though the pneumonia improved, the intravenous EM treatment was continued. As a result, the platelet counts increased to $10.3 \times 10^4 / \mu\text{L}$ about three weeks after the intravenous EM treatment.

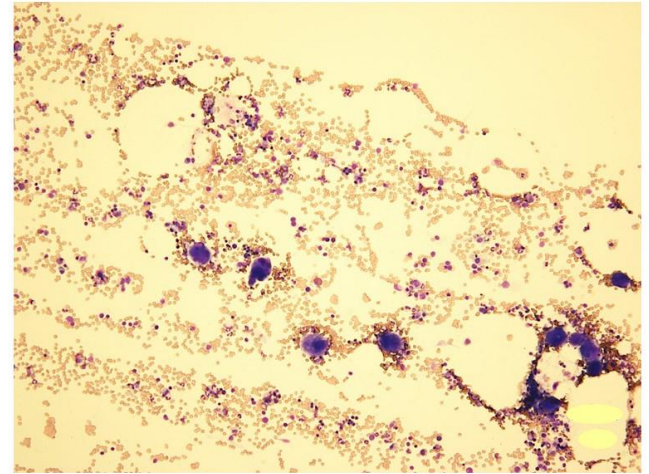


Figure 1. A bone marrow aspiration smear reveals normal bone marrow (May-Giemsa stain, $\times 100$).

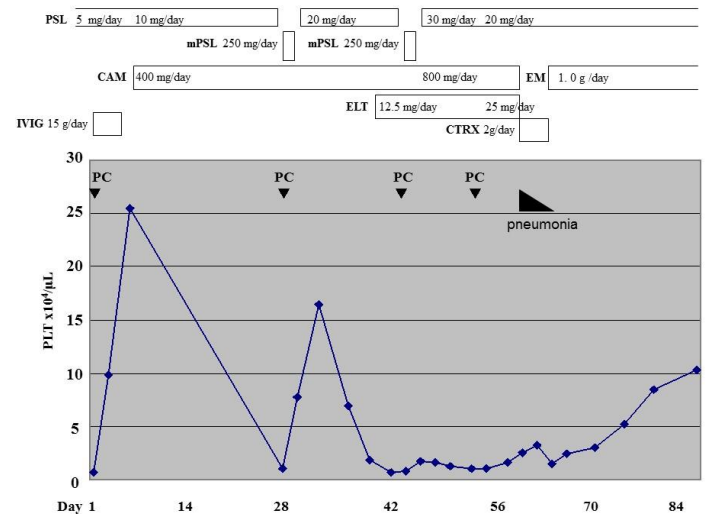


Figure 2. The laboratory data and prescribed drugs on clinical days.

IVIG: intravenous immunoglobulin, PSL: prednisolone, mPSL: methyl prednisolone, CAM: clarithromycin, EM: erythromycin, ELT: eltrombopag. CTRX: ceftriaxone, PC: platelet concentrates

DISCUSSION

Primary ITP is an acquired immune disorder characterized by an isolated thrombocytopenia due to pathogenic anti-platelet autoantibodies, T lymphocyte-mediated platelet destruction, and impaired megakaryocyte function. On the contrary, secondary ITP is triggered by inherited or acquired predisposing diseases such as chronic infections, including HP and human immunodeficiency virus, or autoimmune diseases such as systemic lupus erythematosus or rheumatoid arthritis (6). Recent studies have suggested that HP-positive ITP patients can be successfully treated by eradication of the pathogen (proton pump inhibitor, amoxicillin, and CAM) (7, 8). On the contrary, first-line treatments for primary ITP include CSs. Severe bleeding requires treatment with IVIG. We have previously reported several cases of primary ITP showing increased platelet counts following MACs treatment (1–4). In these cases, we speculated that the ITP improved by the immunomodulatory effects of the MACs. In fact, EM and its derivatives inhibit T lymphocyte proliferation and

induce T lymphocyte apoptosis (9). By contrast, EM had shown to potentiate the function of regulatory T lymphocytes in a rat model (10).

In the previous report, we experienced a case of primary ITP unsuccessfully treated with CAM, but successfully followed by EM (2). In the present case, CSs combined with CAM treatment was ineffective. After suffering from aspiration pneumonia, the patient was treated with intravenous PSL and CTRX. Contrary to our expectations, the platelet counts increased, which is believed to be due to an infection-related reactive thrombocytosis (11). In fact, as the pneumonia grew better, the platelet counts decreased. Thereafter, intravenous EM was started and continued, resulting in increased platelet counts. Based on these findings, the efficacy of intravenous EM treatment is higher than that of oral CAM treatment.

After the oral administration, CAM undergoes a rapid first-pass metabolism in the liver, resulting in a bioavailability level of ~50% (12). On the contrary, intravenous EM results in a bioavailability level of 100%; therefore, this treatment is thought to be more efficient.

EM was the first macrolide to be developed. New macrolides such as CAM and azithromycin have since been developed to supersede EM. CAM is a semisynthetic macrolide antibiotic, chemically identified as 6-O-methylerythromycin A (13). Only a slight structural difference exists between CAM and EM.

Based on these facts, the elevated bioavailability of intravenous EM and/or above-mentioned slight structural difference may be advantageous to intravenous EM treatment for providing immunomodulatory effects, as compared with oral CAM treatment.

More extensive research is required to validate our finding before intravenous EM treatment can be adopted on a wider basis.

Conflict of interest

No conflict of interest was declared by the authors.

REFERENCES

1. Ohe M, Kohno M. Three cases of idiopathic thrombocytopenic purpura showing an increase in the platelet count following clarithromycin treatment. *Rinsho Ketsueki*. 2003; 44:1044-6.

2. Ohe M, Hashino S. Successful treatment with erythromycin for idiopathic thrombocytopenic purpura. *Korean J Hematol*. 2011; 46:139-42.

3. Ohe M, Hashino S. Successful treatment of primary immune thrombocytopenia in aged patients using clarithromycin. *J Formos Med Assoc*. 2014; 113:197- 8.

4. Ohe M, Shida H, Horita T, Furuya K, Hashino S. Successful treatment of primary immune thrombocytopenia accompanied by diabetes mellitus treated using clarithromycin followed by prednisolone. *Drug Discov Ther*. 2018; 12:101-3.

5. Rubin BK, Henke MO. Immunomodulatory activity and effectiveness of macrolides in chronic airway disease. *Chest* 2004; 125(Suppl 2):S70-85.

6. Zufferey A, Kapur R, Semple JW. Pathogenesis and Therapeutic Mechanisms in Immune Thrombocytopenia (ITP). *J. Clin. Med*. 2017, 6, 16; doi:10.3390/jcm6020016.

7. Gasbarrini A, Franceschi F, Tartaglione R, Landolfi R, Pola P, Gasbarrini G. Regression of autoimmunethrombocytopenia after eradication of *Helicobacter pylori*. *Lancet*. 1998; 352:878.

8. Hashino S, Mori A, Suzuki S, Izumiyama K, Kahata K, Yonezumi M, et al. Platelet recovery in patients with idiopathic thrombocytopenic purpura after eradication of *Helicobacter pylori*. *Int J Hematol*. 2003; 77:188-91.

9. Wu L, Zhang W, Tian L, Tian L, Bao K, Li P, et al. Immunomodulatory effects of erythromycin and its derivatives on human T-lymphocyte in vitro. *Immunopharmacol Immunotoxicol*. 2007; 29:587-96.

10. Bai J, Qiu SL, Zhong XN, Huang QP, He ZY, Zhang JQ, et al. Erythromycin enhances CD4+Foxp3+ regulatory T-cell responses in a rat model of smoke-induced lung inflammation. *Mediators Inflamm*. 2012;2012:410232. doi: 10.1155/2012/410232.

11. Schattner A, Kadi J, Dubin I. Reactive Thrombocytosis in Acute Infectious Diseases: Prevalence, Characteristics and Timing. *Eur J Intern Med*. 2019; 63:42-45. doi: 10.1016/j.ejim.2019.02.010.

12. Chu SY, Deaton R, Cavanaugh J. Absolute bioavailability of clarithromycin after oral administration in humans. *Antimicrob Agents Chemother*. 1992; 36:1147-50.

13. Iwasaki H, Sugiura Y, Adachi T, Morimoto S, Watanabe Y. Structure of 6-O-methylerythromycin A (clarithromycin). *Acta Cryst* 1993; C49:1227-30.