

Digital Breast Tomosynthesis-Guided Wire Localization: Assessment of Feasibility and Effectiveness for Breast Lesions Manifested with Calcifications

Dijital Meme Tomosentez Kılavuzluğunda Tel İşaretleme: Kalsifikasyon ile Bulgu Veren Meme Lezyonlarında Uygulanabilirlik ve Etkinliğin Değerlendirilmesi

Halit Nahit Şendur, Serap Gültekin, Emetullah Cindil, Mahi Nur Cerit, Zeynep Sezgi Erdal

Gazi University Faculty of Medicine, Department of Radiology, Ankara, Turkey

ABSTRACT

Objective: To evaluate the feasibility and effectiveness of digital breast tomosynthesis (DBT) guided wire localization for breast lesions manifested with calcifications.

Methods: Between December 2017 and August 2019, a total of 36 patients who had suspicious calcifications and underwent surgery after DBT-guided wire localization were enrolled to the study. Characteristics and extension of calcifications, approaching direction, depths of the targeted calcifications, distance from tip of wire to the targeted calcifications, number of exposures, total radiation doses, complication rates for all cases, and reoperation rates of malignant cases were noted. Mean, maximum and minimum values were used as descriptive statistics of the data. Mann-Whitney U test was used to compare differences between subgroups.

Results: The mean age of the patients was 50.81 ± 9.12 (33-68 years) Of 36 patients, histopathologic assessment verified calcifications of 14 (38.9%) lesions as benign, and 22 (61.1%) lesions as malignant. All suspicious calcifications (100%) were excised adequately. The mean extension of the calcifications were 19.61 ± 17.37 mm (3 - 67 mm). There was a statistically significant difference in the extension of calcifications between benign and malignant subgroups ($P = 0.014$). The mean of radiation doses for the procedures was 8.65 ± 2.77 mGy ($3.51 - 14.14$ mGy). Reoperation rate was 40.9% for malignant patients.

Conclusion: Our study revealed that DBT-guided wire localization is a feasible technique for surgical excision of lesions manifested with calcifications. However, the relatively high reoperation rates for malignant cases require future studies with comparison to other techniques.

Key Words: Digital breast tomosynthesis, wire localization, breast calcifications

Received: 05.16.2020

Accepted: 10.26.2020

ÖZET

Amaç: Kalsifikasyon ile bulgu veren meme lezyonlarında dijital meme tomosentez (DMT) kılavuzluğunda tel işaretleme uygulananabilirliğini ve etkinliğini değerlendirmek amaçlanmaktadır.

Yöntem: Aralık 2017 ve Ağustos 2019 tarihlerarasında şüpheli kalsifikasyon nedeni ile DMT kılavuzluğunda tel ile işaretleme işlemi yapılarak opere edilen toplam 36 hasta çalışmaya dahil edildi. Tüm olgularda kalsifikasyonların özellikleri ve uzanımları, yaklaşım yönü, kalsifikasyonların derinliği, tel ucu ile kalsifikasyonlar arasındaki mesafe, görüntüleme sayısı, toplam radyasyon dozu, komplikasyon oranı ve malign olgularda operasyon tekrar oranları not edildi. Ortalama, minimum, maksimum değerler tanımlayıcı istatistik olarak kullanıldı. Gruplar arası farklılıklar Mann-Whitney U testi ile değerlendirildi.

Bulgular: Hastalar ortalama 50.81 ± 9.12 (33-68 yaş) yaşındaydı. Histopatolojik değerlendirme sonucunda 36 hastanın 14'ü (%38.9) benign 36'sı (%61.1) malign tanı aldı. Tüm şüpheli kalsifikasyonlar (%100) uygun olarak eksize edildi. Kalsifikasyonların ortalama uzanımı 19.61 ± 17.37 mm (3 - 67 mm) olarak ölçüldü. Benign ve malign kalsifikasyonların uzanımları arasında istatistiksel olarak anlamlı fark vardı ($P = 0.014$). İşlemlerdeki ortalama radyasyon dozu 8.65 ± 2.77 mGy ($3.51 - 14.14$ mGy) olarak hesaplandı. Malign hastalarda operasyon tekrar oranı %40.9 olarak belirlendi.

Sonuç: Çalışmamızda elde ettiğimiz bulgulara kalsifikasyon ile bulgu veren meme lezyonların cerrahi eksizyonu için DMT kılavuzluğunda tel ile işaretleme uygulanabilir bir teknik olduğunu göstermiştir. Ancak malign olgularda göreceli olarak yüksek operasyon tekrar oranı diğer teknikler ile karşılaştırmalı çalışmalar gerektirmektedir.

Anahtar Sözcükler: Dijital meme tomosentez, tel ile işaretleme, meme kalsifikasyonları

Geliş Tarihi: 16.05.2020

Kabul Tarihi: 26.10.2020

ORCID IDs: H.N.Ş. 0000-0003-1690-2538, S.G. 0000-0001-6349-3998, E.C. 0000-0002-9345-1577, M.N.C. 0000-0003-2878-6052, Z.S.E. 0000-0002-5063-0591

Address for Correspondence / Yazışma Adresi: Halit Nahit Şendur, MD Gazi University Faculty of Medicine Department of Radiology Mevlana Bulvarı No:29 06560 Yenimahalle, Ankara, Turkey E-mail: hsendur@gmail.com

©Telif Hakkı 2021 Gazi Üniversitesi Tıp Fakültesi - Makale metnine <http://medicaljournal.gazi.edu.tr/> web adresinden ulaşılabilir.

©Copyright 2021 by Gazi University Medical Faculty - Available on-line at web site <http://medicaljournal.gazi.edu.tr/>

doi:<http://dx.doi.org/10.12996/gmj.2021.12>

INTRODUCTION

Digital breast tomosynthesis (DBT) is an imaging technique that consists of several projection views and it is widely used in breast imaging centers around the world. The main benefit of this technique is the elimination of the masking effect caused by overlying normal breast parenchyma which may lead to delay in the diagnosis of breast cancer (1,2). It is evidenced that the utilization of DBT in clinical practice improves the recall and cancer detection rates (3-5). With the widespread use of DBT, there have been needs to use it for interventional procedures in some cases, especially for the lesions that are better depicted at DBT images (6).

Breast cancers may manifest with a variety of findings at mammography examinations. Venkatesan et al. (7) reported that calcifications are the second most common finding detected on mammography examinations of breast cancer patients, and 29% of breast cancer cases are represented with signs of calcifications. Moreover, according to the American College of Radiology Breast Imaging Reporting and Data System (BI-RADS) lexicon (8), other than typically benign calcifications, all morphologic subtypes of calcifications are categorized in BI-RADS 4 which indicates a sufficient probability of malignancy. Therefore, mammographically visualized suspicious calcifications warrant tissue sampling and histologic evaluation.

Vacuum-assisted breast (VAB) biopsy is one of the effective techniques to sample suspicious breast calcifications (9,10). However, several conditions like consensual preferences of the patient and the surgeon, the intolerance of the patients to VAB biopsy and unavailability of the VAB technique may require proceeding to surgery. Furthermore, histopathology of the biopsied calcifications subsequently may necessitate surgical excisions. Thus, preoperative needle localization (wire or radioactive seed) of calcifications may become inevitable. Several studies demonstrated that DBT-guided preoperative needle localization is an accurate and feasible technique to precisely remove nonpalpable breast lesions (11,12). However, despite the wide acceptance of DBT benefits, the data in the literature for the utilization of DBT in preoperative needle localization is limited. To prove the efficacy of the DBT-guided preoperative needle localization, studies designed for certain types of lesions are necessary. To the best of our knowledge, no prior study dedicated to performing DBT-guided wire localization technique for suspicious calcifications exists in the literature. Therefore, in the current study, we aimed to present our single center experience in DBT-guided preoperative wire localization for suspicious calcifications, and to evaluate the effectiveness of the technique.

MATERIALS and METHODS

This retrospective study was approved by the Ethics Committee of our university and the requirement of written informed consent was waived. Between December 2017 and August 2019, 38 consecutive patients who had preoperative DBT-guided needle localization due to mammographically detected suspicious calcifications at our institutional breast imaging center were enrolled to study. Two patients were excluded from the study because of inability to retrieve their images acquired during the procedure from picture archiving and communication system (PACS). Thus, the final study cohort consisted of 36 patients. All suspicious calcifications were nonpalpable on physical examinations. Because health insurance systems do not cover VAB biopsies in our country, these patients did not have biopsies and directly proceeded to surgery. However, all patients had a targeted ultrasound examination prior to the decision of surgery for a chance of ultrasound-guided biopsy. All targeted ultrasound examinations were negative.

Two radiologists with 7 and 15 years of experiences in interventional breast procedures, respectively, performed all procedures using a single DBT unit (Selenia Dimensions, Hologic, Danbury, CT, USA) on upright position. All procedures were performed with a standard protocol on the day of surgery. If there was no specific preference of the surgeons for operation planning, the closest distance from skin to the calcifications was used to decide the approaching direction. An alphanumeric grid was used to obtain a scout image, and then a tomosynthesis image was acquired to determine the depth of the targeted calcifications for all patients before starting to perform needle localization. Wire was used to perform all DBT-guided needle localization procedures. After appropriate positioning, while the breast remains in compression the introducer needle was removed and the wire was deployed. Control images were acquired to document the final position of the wire. Depending on the surgeons' preferences, two wires were placed for bracketing the calcifications in preprocedurally determined cases.

Distribution, morphology, and extension of calcifications, approaching direction, depths of the targeted calcifications on compressed status of the breast, distance from tip of wire to the targeted calcifications, number of exposures, total radiation doses, and if occurred, complications were noted. In two-wires placed patients the means of depths of the targeted calcifications and absolute distances from tips of wires to the targeted calcifications were noted for analyses. The success of the procedures was assessed depending on adequate removal of the targeted calcifications on specimen mammography which was acquired before finishing the operations of all patients. The adequacy of the excision was determined according to the perception of the performing radiologist while assessing the specimen mammography in comparison to preoperative mammograms (Figure 1). Furthermore, for malignant cases, reoperation rates were noted.

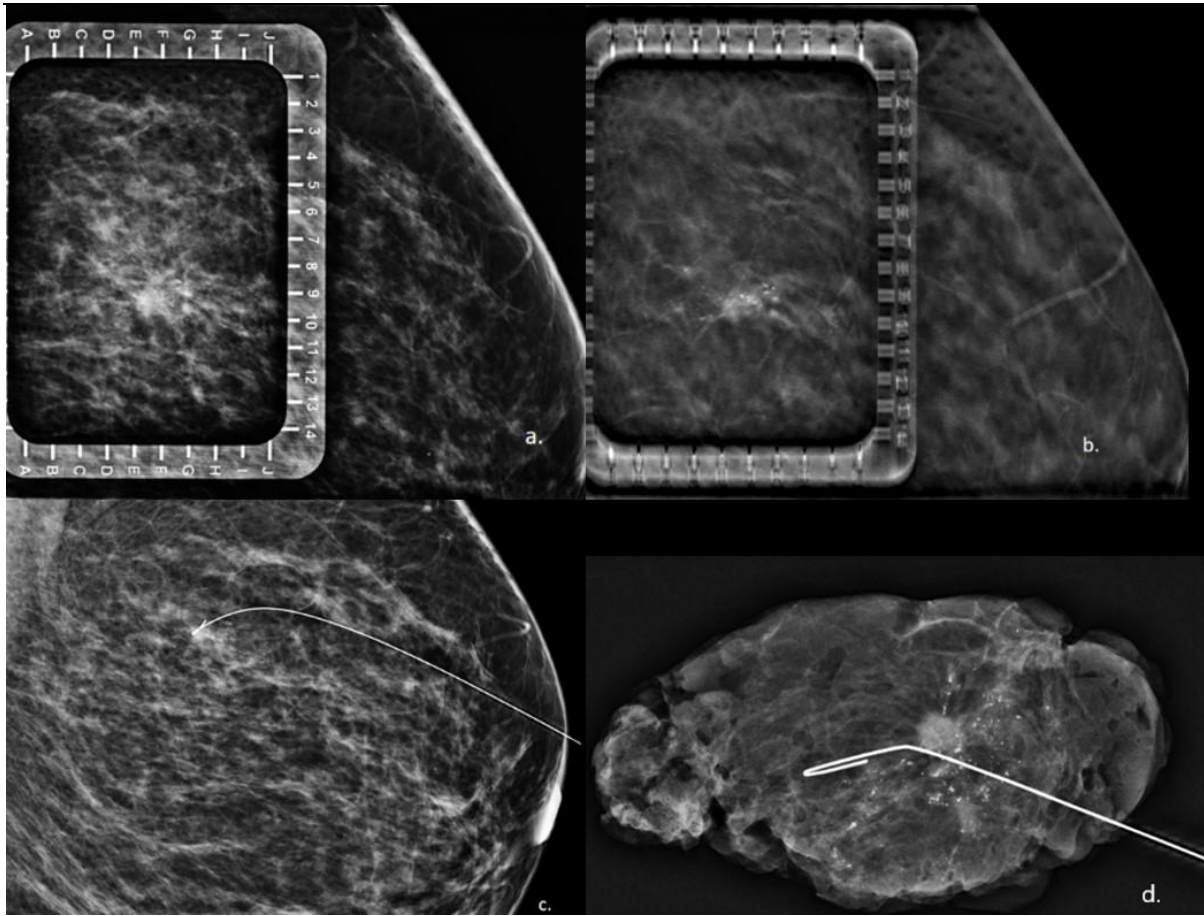


Figure 1. 61 years old woman with left breast suspicious calcifications underwent digital breast tomosynthesis (DBT) guided wire localization procedure. **a**, Mediolateral (ML) scout image with an alphanumeric grid demonstrates suspicious calcifications. **b**, DBT image acquired to determine the depth of the calcifications. **c**, Control image is acquired to check the position of the wire. **d**, Specimen mammography documented the adequate excision of suspicious calcifications. Histopathologic assesment revealed invasive ductal carcinoma.

The statistical analyses were performed using SPSS 22.0 Software (IBM Corp, Armonk, NY, USA). Mean, standard deviation, median, maximum and minimum values were used as descriptive statistics of the data. The normality of the data distribution was assessed using the Kolmogorov-Smirnov test. Mann-Whitney U test was used to compare differences between subgroups.

RESULTS

A total of 36 patients whose mammography examinations revealed suspicious calcifications underwent surgery after the DBT-guided wire localization procedure. All suspicious calcifications (100%) were excised adequately and verified with specimen mammography. The mean age of the patients was 50.81 ± 9.12 (33-68 years). Of these 36 patients, histopathologic assessment verified calcifications of 14 lesions as benign (8 fibrocystic changes and 6 adenosis/sclerosing adenosis), and 22 lesions as malignant (16 ductal carcinoma in situ, 5 invasive ductal carcinoma, 1 invasive lobular carcinoma). Two wires were placed to bracket the calcifications of 6 patients (all were subsequently diagnosed as malignant) depending on the surgical plan. The characteristics of included calcifications and approaching directions were presented on the Table 1.

Table 1 Characteristics of included calcifications of patients and number of approaching directions

Variables	n (36)
Biological behaviour	
<i>Benign</i>	14 (38.9%)
<i>Malignant</i>	22 (61.1%)
Morphology	
<i>Amorphous</i>	23 (63.9%)
<i>Coarse heterogenous</i>	6 (16.7%)
<i>Fine pleomorphic</i>	7 (19.4%)
Distribution	
<i>Regional</i>	2 (5.5%)
<i>Grouped</i>	27 (75%)
<i>Linear</i>	1 (2.7%)
<i>Segmental</i>	6 (16.7%)
Approaching Direction	
<i>Lateromedial</i>	13 (36.1%)
<i>Mediolateral</i>	10 (27.8%)
<i>Craniocaudal</i>	13 (36.1%)

The mean extension of the calcifications was 19.61 ± 17.37 mm (3 - 67 mm). There was a statistically significant difference in the extension of calcifications between benign and malignant subgroups ($P = 0.014$). The mean number of exposures was 5.44 ± 0.9 (4 - 8 exposures). The mean of radiation doses for the procedures was 8.65 ± 2.77 mGy (3.51 - 14.14 mGy). No statistically significant differences were found in the depth of the calcifications, distance from tip of the wire to targeted calcifications, the number of exposures and radiation doses between benign and malignant subgroups. Table 2 summarizes the quantitative data of the study. Only 4 (11.1%) patients had vasovagal response as complication during the procedures.

Table 2: Mean, minimum and maximum values of the quantitative data

Variable	Overall (n=36) (min-max)	Benign (n=14) (min-max)	Malignant (n=22) (min-max)
Extension of calcifications (mm)	19.61±17.37 (3-67)	11.07±9.24 (3-37)	25.05±19.24 (3-67)
Depth of calcifications (mm)	28.14±7.32 (15-41)	30.21±6.75 (16-40)	26.82±7.53 (15-41)
Distance from tip of wire to calcifications (mm)	7.22±4.82 (1-20)	8.93±6.54 (1-20)	6.14±3.01 (1-15)
Number of exposures	5.44±0.9 (4-8)	5.57±0.75 (5-7)	5.36±1 (4-8)
Radiation doses (mGy)	8.65±2.77 (3.51-14.14)	9.19±2.25 (5.31-12.48)	8.3±3.06 (3.51-14.14)

According to histopathologic assessments [close (<2 mm) or positive margin] nine (40.9%) of malignant patients underwent additional operations (1 segmental mastectomy, 8 mastectomies). For malignant patients, no statistically significant difference was found in characteristics or measurements of the calcifications between reoperated patients and the patients who did not require an additional operation.

DISCUSSION

The increasing utilization of DBT in breast imaging centers necessitates DBT-guided interventions more frequently. The main advantage of this technique is eliminating the requirement of triangulation and providing immediate depth information for lesions. The current study revealed that, DBT-guided wire localization can be used successfully to surgically remove breast lesions manifested with calcifications, and this provides an additional advantage of the DBT technique. We think that, in the future, as the evidences accumulate for the success of DBT-guided interventions, the DBT technique will play a more crucial role in patient management, and thereby, the findings of this study may have an important implication for patient care. It has been reported that the clinical performance of the DBT-guided VAB biopsy technique is superior to prone stereotactic VAB biopsy technique, and the latter one requires a longer time and more number of exposures during the procedure (13). Moreover, prone tables have a weight limit and occupy a large space at facilities, and these are no longer problems with the utilization DBT systems for breast interventions. Therefore, with the contribution of the current study findings to prior studies (11-14), the success of DBT-guided interventions may decrease the requirement of prone stereotactic biopsy systems at breast imaging centers. This may reduce the costs of breast imaging centers and provide an opportunity to use health investments more efficiently.

Freer et al. (11) performed DBT-guided needle localization for lesions manifested with architectural distortions that were visible on DBT images only. In their study they included 17 (47%) malignant and 19 (53%) benign lesions. They reported that 97% of lesions were accurately excised on the first attempt of the DBT-guided needle localization technique. Choudhery et al. (12) presented their initial experiences with tomosynthesis-guided needle localization of breast and axillary lesions, and they reported that all lesions (100%) were successfully removed at surgery. They only included 5 (13%) lesions with groups of microcalcifications and used wire or radioactive seed depending on the referring surgeon's preference. Despite the differences in lesion types and variabilities in

localization materials, both of the aforementioned studies concluded that performing needle localization under DBT guidance is a feasible technique for breast lesions. In our study, performing radiologists interpreted the excision of calcifications as adequate for all patients (100%) on specimen mammography images. Therefore, our findings suggest that DBT-guided needle localization can be considered as a feasible technique for surgical excision of suspicious calcifications.

Dryden et al. (15) compared the radioactive seed localization technique with wire localization technique based on imaging factors that influence margin status. In that study, authors performed 405 wire localization procedures, and reported that reoperation rate was 20% with wire localization technique. 35% of lesions in their study cohort were associated with calcifications (calcifications or mass with calcifications), and they reported that presence of calcifications significantly influences margin status, thereby, increases the reoperation rates. In the current study, the reoperation rate was 40.9%. Although several studies (16-17) reported a higher close or positive margin status percentages with wire localization technique, the achieved 40.9% percentage was considered as relatively high. The high reoperation rate in this study is likely due to the inclusion of lesions only manifested with calcifications. However, studies that compare the radioactive seed localization technique, which may yield more successful results, with wire localization technique in DBT guidance with regard to the surgical outcomes for calcifications will enable us to better understand the effectivity of the technique. Moreover, it has been reported that the radioactive seed localization technique may also enable the surgeon to tailor excision procedure better than the wire localization technique (18). Therefore, surgical experiences may also influence the reoperation rates. As the current study did not evaluate the experiences of surgeons with wire localization technique, future studies which consider the experience levels of surgeons with this technique will also be beneficial.

Choudhery et al. (12) reported that the mean number of exposures was 4.4, and the mean radiation dose was 6.38 mGy for tomosynthesis guided needle localization procedure in their study. In the current study, the mean number of exposures was 5.44, and the mean radiation dose was 8.65 mGy for the DBT-guided needle localization technique. The differences in the number of exposures and radiation doses between two studies may be considered within acceptable ranges. As we included only lesions manifested with calcifications, the procedure can be completed more reasonably with various type of lesions which describes the study cohort of Choudhery et al. Moreover, possible differences in breast characteristics of included patients like density and thickness, which influence radiation doses, may also have an impact on these results.

Depending on our own experiences, one technical note worths mentioning. If the extension of calcifications is too small ($\leq 7-8$ mm), on the tomosynthesis image which is acquired to check the position before the wire is deployed, artifacts around the introducer needle may prevent to visualize targeted calcifications confidentially. To overcome this obstacle, a definite determination of the depth of the calcifications or targeting a close area at the same depth of the calcifications will be helpful. If the latter one is chosen, a well established communication with the surgeon is mandatory.

The current study has several limitations. The first one is a relatively small number of included patients. Future studies with a larger number of patients will be more beneficial to understand the effectivity of the DBT-guided wire localization for lesions manifested with calcifications. The second limitation is that all procedures were performed with only one DBT unit. It is known that the z-dimension resolutions and angular ranges used for acquisitions vary among DBT units from different vendors. Different technical features of DBT units have the potential to influence success rates of DBT-guided interventions. Therefore, multicenter studies that include DBT units from different vendors will be valuable. The other limitation which should be mentioned is the experience level of radiologists (7 and 15 years of experiences in interventional breast procedures, respectively) who performed the procedures. This study does not provide information about the feasibility of the DBT-guided wire localization for calcifications with less experienced radiologists. The high experience of the radiologists may also influenced the success rates of the procedures. Therefore, evaluation of success rates of the radiologists with different levels of experiences for this technique will also contribute to the literature.

CONCLUSION

Our study revealed that DBT-guided wire localization is a feasible technique for surgical excision of lesions manifested with calcifications. However, to better understand the effectiveness of the technique, the relatively high reoperation rates in malignant cases require future studies with comparison to other techniques.

Conflict of interest

No conflict of interest was declared by the authors.

REFERENCES

1. Roth RG, Maidment AD, Weinstein SP, Roth SO, Conant EF. Digital breast tomosynthesis: lessons learned from early clinical implementation. *Radiographics* 2014;34(4):E89–E102.
2. Hooley RJ, Durand MA, Philpotts LE. Advances in digital breast tomosynthesis. *AJR Am J Roentgenol.* 2017;208(2):256–266.
3. Rose SL, Tidwell AL, Bujnoch LJ, Kushwaha AC, Nordmann AS, Sexton R Jr. Implementation of breast tomosynthesis in a routine screening practice: an observational study. *AJR Am J Roentgenol* 2013;200:1401–1408.
4. Skaane P, Bandos AI, Gullien R, et al. Comparison of digital mammography alone and digital mammography plus tomosynthesis in a population-based screening program. *Radiology* 2013;267:47–56.
5. Friedewald SM, Rafferty EA, Rose SL, et al. Breast cancer screening using tomosynthesis in combination with digital mammography. *JAMA* 2014;311:2499–2507.
6. Horvat JV, Keating DM, Rodrigues-Duarte H, Morris EA, Mango VL. Calcifications at Digital Breast Tomosynthesis: Imaging Features and Biopsy Techniques. *RadioGraphics.* 2019;39:307-318.
7. Venkatesan A, Philip C, Kerlikowske K, Sickles EA, Smith-Bindman R. Positive predictive value of specific mammographic findings according to reader and patient variables. *Radiology* 2009;250:648–57.
8. Sickles E, D’Orsi C, Bassett LW, et al. *ACR BI-RADS Atlas Breast Imaging Reporting and Data System.* Reston, Va: American College of Radiology, 2013.
9. Kettritz U, Rotter K, Schreer I, et al. Stereotactic vacuum-assisted breast biopsy in 2874 patients: a multicenter study. *Cancer* 2004; 100(2):245–251.
10. Yu YH, Liang C, Yuan XZ. Diagnostic value of vacuum-assisted breast biopsy for breast carcinoma: a meta-analysis and systematic review. *Breast Cancer Res Treat* 2010; 120(2):469–479.
11. Freer PE, Niell B, Rafferty EA. Preoperative tomosynthesis-guided needle localization of mammographically and sonographically occult breast lesions. *Radiology* 2015; 275:377–383.
12. Choudhery S, Simmons C, Harper L, Lee CU. Tomosynthesis-guided needle localization of breast and axillary lesions: Our initial experiences. *AJR Am J Roentgenol.* 2019;212(4):943-946.
13. Bahl M, Maunglay M, D’Alessandro HA, Lehman CD. Comparison of upright digital breast tomosynthesis-guided versus prone stereotactic vacuum-assisted breast biopsy. *Radiology* 2019;290:298-304.
14. Schradang S, Distelmaier M, Dirrichs T, et al. Digital breast tomosynthesis-guided vacuum-assisted breast biopsy: initial experiences and comparison with prone stereotactic vacuum-assisted biopsy. *Radiology* 2015; 274:654–662.
15. Dryden MJ, Dogan BE, Fox P, et al. Imaging factors that influence surgical margins after preoperative 125i radioactive seed localization of breast lesions: comparison with wire localization. *AJR Am J Roentgenol.* 2016;206(5):1112-1118.
16. Gray RJ, Salud C, Nguyen K, et al. Randomized prospective evaluation of a novel technique for biopsy or lumpectomy of nonpalpable breast lesions: radioactive seed versus wire localization. *Ann Surg Oncol* 2001; 8:711–715.
17. Nadeem R, Chagla LS, Harris O, et al. Occult breast lesions: a comparison between radioguided occult lesion localisation (ROLL) vs. wire-guided lumpectomy (WGL). *Breast* 2005; 14:283–285.
18. Jakub JW, Gray RJ, Degnim AC, Boughey JC, Gardner M, Cox CE. Current status of radioactive seed for localization of non palpable breast lesions. *Am J Surg* 2010; 199:522–528.