

## Advanced Triple Negative Breast Cancer in Pregnancy

### Gebelikte Gelişmiş Üçlü Negatif Meme Kanseri

Tze Huat Chong<sup>1</sup>, Gunaseelan G. Durairaj<sup>1</sup>, Firdaus Hayati<sup>2</sup>, Nornazirah Azizan<sup>3</sup>, Fatimah Ahmedy<sup>4</sup>, Nor Faezan Abdul Rashid<sup>5</sup>

<sup>1</sup>Department of Surgery, Serdang Hospital, Ministry of Health Malaysia, Serdang, Selangor, Malaysia

<sup>2</sup>Department of Surgery, Faculty of Medicine and Health Sciences, Universiti Malaysia Sabah, Kota Kinabalu, Sabah, Malaysia

<sup>3</sup>Department of Pathobiology and Medical Diagnostics, Faculty of Medicine and Health Sciences, Universiti Malaysia Sabah, Kota Kinabalu, Sabah, Malaysia

<sup>4</sup>Department of Medical Education, Faculty of Medicine and Health Sciences, Universiti Malaysia Sabah, Kota Kinabalu, Sabah, Malaysia

<sup>5</sup>Department of Surgery, Faculty of Medicine, Universiti Teknologi MARA, Sungai Buloh, Selangor, Malaysia

#### ABSTRACT

Breast cancer is one of the most common prevalent malignancies in pregnancy. The management is challenging as it involves both maternal and fetal well-being. A 41-year-old lady was diagnosed with triple negative breast cancer in the second trimester pregnancy. Neoadjuvant chemotherapy was decided as she opted for a continuation of pregnancy and refusal for mastectomy. After completing the second cycle of chemotherapy, she developed preterm premature rupture of membrane and had fetal malposition requiring an emergency caesarean section. Computed tomography staging revealed an advanced disease, hence needing palliative treatment and support. The difficulties in managing this case arise in choosing the best treatment to preserve both maternal and fetal wellbeing.

**Key Words:** Neoadjuvant Treatment, Pregnant Woman, Triple Negative Breast Cancer

**Received:** 02.21.2020

**Accepted:** 07.30.2020

#### ÖZET

Meme kanseri, gebelikte en sık görülen malignitelerden biridir. Yönetim, hem maternal hem de fetal iyilik halini içerdiği için zordur. 41 yaşındaki bir kadına, ikinci trimester gebelikte üçlü negatif meme kanseri teşhisi kondu. Neoadjuvan kemoterapiye, gebeliğin devam etmesi ve mastektomiye reddetmesi kararı verildi. Kemoterapinin ikinci döngüsünü tamamladıktan sonra, erken membran rüptürü geliştirdi ve acil sezaryen gerektiren fetal malpozisyon gelişti. Bilgisayarlı tomografi evrelemesi ilerlemiş bir hastalığı ortaya çıkardı ve bu nedenle palyatif tedavi ve desteğe ihtiyaç duyuldu. Bu vakayı yönetmedeki zorluklar, hem annenin hem de fetüsün sağlığını korumak için en iyi tedaviyi seçmede ortaya çıkar.

**Anahtar Sözcükler:** Neoadjuvan Tedavi, Hamile Kadın, Üçlü Negatif Meme Kanseri

**Geliş Tarihi:** 21.02.2020

**Kabul Tarihi:** 30.07.2020

**ORCID IDs:** T.H.C. 0000-0002-3401-6380, G.G.D. 0000-0002-8082-9462, F.H. 0000-0002-3757-9744, N.A. 0000-0002-5831-3734, F.A. 0000-0002-5811-4188, N.F.A.R. 0000-0002-6491-8094

**Address for Correspondence / Yazışma Adresi:** Firdaus Hayati, MD, Dr.GenSurg. Department of Surgery, Faculty of Medicine and Health Sciences, Universiti Malaysia Sabah, Kota Kinabalu, Sabah, Malaysia E-mail:firdaushayati@gmail.com

©Telif Hakkı 2020 Gazi Üniversitesi Tıp Fakültesi - Makale metnine <http://medicaljournal.gazi.edu.tr/> web adresinden ulaşılabilir.

©Copyright 2020 by Gazi University Medical Faculty - Available on-line at web site <http://medicaljournal.gazi.edu.tr/>

doi:<http://dx.doi.org/10.12996/gmj.2020.153>

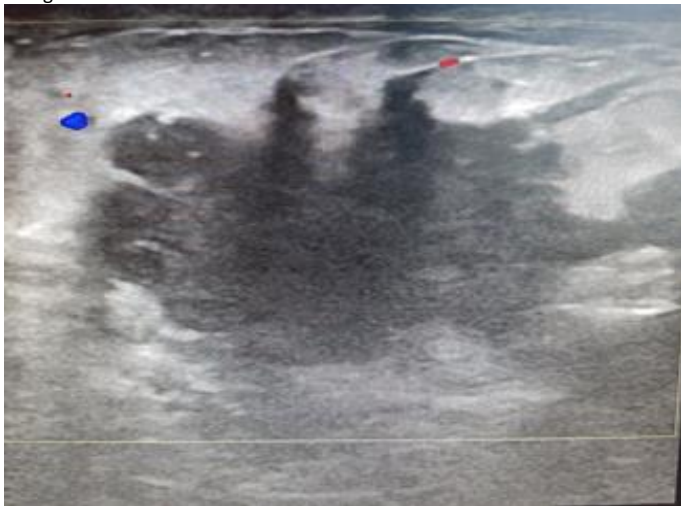
**INTRODUCTION**

Breast cancer is one of the most common prevalent malignancies in pregnancy (1,2). Worldwide, it is estimated that the incidence of breast cancer in pregnancy is about 1 in 3000 (3). Cancer is often associated with a poor prognosis due to delay in diagnosis and treatment. Features including breast hypertrophy and nipple discharge that mimic the physiological changes in pregnancy contributed to diagnostic delay for delivering appropriate anti-cancer treatments. The concern on fetal health will add up to the diagnostic and treatment dilemma. When dealing with this malignancy, there are many considerations that need to be fulfilled as both patient and physician will face a difficult situation. The difficulties arise on how to preserve both maternal and fetal wellbeing without imparting harm secondary to the therapeutic agents and treatment modalities commonly delivered in managing breast cancer.

The principle of breast cancer management in pregnancy primarily follows a similar algorithm in non-pregnancy. However, the pathways differ for each trimester and are influenced by the advancement of the disease (2). Maternal period of a trimester is a paramount factor as each trimester offers different modes of management and affects differently on fetal growth. Herein, we discuss a case of a middle-aged mother with advanced breast cancer diagnosed during the second trimester, who wished to avoid surgical mastectomy while continuing with the pregnancy.

**CASE REPORT**

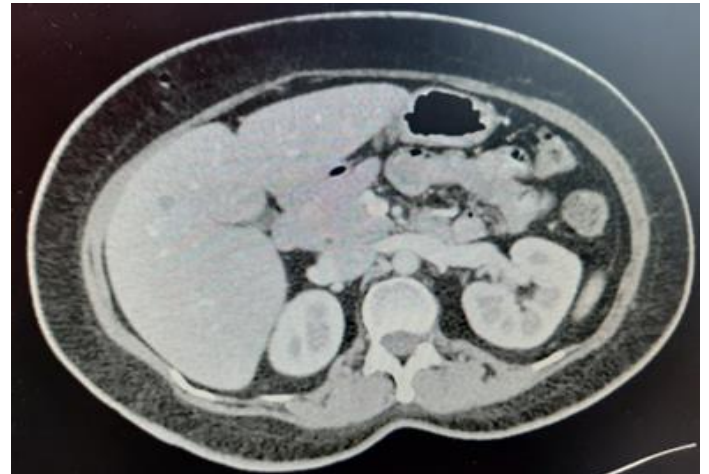
A 41-year-old woman, gravida 8 and para 5, was incidentally noted to have a painless left breast lump at 21 weeks of gestation during her regular antenatal follow-up. She has a strong family history whereby her mother was diagnosed with breast cancer at the age of 60's. On examination, there was a hard, irregular mass over the left breast measuring 5 x 4 cm in diameter. The mass was non-tender and mobile with normal overlying skin. There was no palpable ipsilateral axillary lymphadenopathy. Ultrasonographic evaluation of the left breast mass was highly suspicious of malignancy (Figure 1). Histopathological findings from subsequent trucut biopsy were consistent with breast invasive ductal carcinoma with negative estrogen receptor (ER), progesterone receptor (PR) and HER-2 receptor. Hence, the impression of triple negative breast cancer in pregnancy was given.



**Figure 1:** Ultrasonic evidence of breast lump with malignancy feature.

At this point, the pregnancy has reached the second trimester (24<sup>th</sup> week of gestation) and the decision for continuing the pregnancy was made. She was counselled for neoadjuvant chemotherapy, followed by elective Caesarean section at the 36<sup>th</sup> week of gestation and left mastectomy with axillary clearance in the same surgical setting. However, the mother refused both mastectomy and caesarean section. She was then referred to the oncological department for neoadjuvant chemotherapy and received a total of 2 cycles of chemotherapy (FEC regime) prior to the delivery. Throughout the whole journey, she was motivated with good family support.

Emergency caesarean section was performed at the 36<sup>th</sup> week of gestation due to preterm premature rupture of membrane and fetal malposition. At that time she was 4 weeks post completing the second cycle of chemotherapy at her 32-week period of gestation. Post-delivery, the computed tomography (CT) scan (Figure 2) showed locoregional metastasis to left axillary lymph node with distant metastasis to the liver and bone. Due to the advanced stage of cancer, mastectomy is no longer considered as part of the management and palliative chemotherapy is prescribed as the best mode of treatment.



**Figure 2:** CT scan showed segment IVA liver metastasis.

**DISCUSSION**

There are a lot of debatable policies in the mode of treatment for breast cancer in pregnancy (3). In the past, termination of pregnancy was recommended due to the belief that hormonal changes during pregnancy would promote and enhance the propagation of breast cancer cells (1,4). However, this hypothesis was challenged with emerging literature from several studies that have shown insufficient evidence in reducing the tumour recurrence or prolonging the survival rate when termination of pregnancy was adopted (3). Nevertheless, expectant mothers that need to undergo curative treatment but potentially harmful to the mother or fetus for breast cancer with poor prognosis, for instance, receptor negative tumour or distant metastasis, may benefit from termination of pregnancy counseling. However, it is recommended that the option is reserved for cases with poor prognosis diagnosed during the first trimester (2). Hence, termination of pregnancy is not an option for our case as she was in her second trimester stage of pregnancy.

It is well understood that chemotherapy drug clearance is affected as a result of physiological changes in pregnancy altering the maternal hepatic metabolism, plasma protein binding and renal blood flow. Hence, it is difficult to determine the appropriate optimum dosage for prescribing the chemotherapy agent, especially in advancing pregnancy. This may increase the risk for overdosing leading to maternal toxicity or underdosing causing subtherapeutic index and treatment failure. Chemotherapy works as an anti-cancer agent by disrupting the nucleic acid synthesis and microtubule function. During the first trimester, fetuses undergo a rapid rate of cell division for organogenesis and therefore, mostly susceptible to chemotherapy toxicity at this stage of pregnancy. As a result, chemotherapy is contraindicated during the first trimester of pregnancy and has been associated with an increased risk of spontaneous abortion (5,6). Established studies have looked into the safety of chemotherapy for treating breast cancer in pregnancy and demonstrated that the rate of congenital malformation ranged between 3-5% (7-9).

It is now accepted as a consensus that chemotherapy is offered for breast cancer in advancing pregnancy, i.e. second and third trimester while mastectomy is only considered for localized tumour (2). On that note however, additional caution has to be emphasized near the time of delivery. There are innumerable cases of myelosuppression occurring in both the mother and the baby due to immunosuppression secondary to the chemotherapy agent resulting in significant sepsis and haemorrhage (10).

As a consequence, it is recommended that chemotherapy should be withheld for at least 3 weeks prior to the expected date of delivery for optimizing maternal blood parameter. In our case, the emergency delivery was not likely related to the myelosuppression issue, although further exploration is required to investigate the possible linkage between chemotherapy and premature rupture of membrane.

As for hormonal therapy and targeted therapy, these are commonly prescribed for receptor responsive breast tumours but both are contraindicated in pregnancy despite the presence of these receptors (11-13). Studies have shown that both therapies are associated with multiple adverse fetal outcomes. For example, Mir has reported that trastuzumab is associated with anhydromnios, whereas Cullins et al have described Goldenhar's syndrome, characterized by hemifacial microsomia, microtia, and periauricular skin tags with the use of tamoxifen (13,14). Unfortunately, the case presented here was negative for all receptors and would not be an ideal candidate to receive these types of therapies post-delivery.

For this particular case, the advancing breast cancer with distant metastasis deemed chemotherapy to be the best treatment as surgical intervention is no longer considered to be an option after the delivery. Following the completion of the chemotherapy, findings from the CT scan would indicate the success of the chemotherapy. On the other hand, CT scan imaging after completion of chemotherapy is only reserved for breast cancer in pregnancy if the investigation would yield findings that would change the management (2). Otherwise, this would be performed at post-delivery stage. Instead, a holistic approach with multidisciplinary care and multimodal interventions is proven benefits for expecting mothers diagnosed with breast cancer. The key players include surgeon, obstetrician, oncologist, pathologist, paediatrician and psychologist aiming for patient-centered care. Counseling is crucial and has to be initiated from the point of diagnosis onwards.

## CONCLUSION

Any breast pathology needs to be managed according to triple assessment and standard treatments including a pregnant lady. Among pregnant ladies, each and every management should be carefully considered in order to minimize the negative impact on both mother and fetus while providing the most optimal anti-cancer therapeutic effect.

## Conflict of interest

No conflict of interest was declared by the authors.

## Acknowledgement

We would like to thank the Director General of Health Malaysia for his permission to publish this article as case report.

## REFERENCES

1. Cardonick E, Dougherty R, Grana G, et al. Breast Cancer During Pregnancy. *The Cancer Journal*. 2010;16:76-82.
2. Amant F, Loibl S, Neven P, et al. Breast cancer in pregnancy. *The Lancet*. 2012;379:570-579.
3. Ring AE, Smith IE, Ellis PA. Breast cancer and pregnancy. *Annals of Oncology*. 2005;16:1855-1860.
4. Clark RM, Chua T. Breast cancer and pregnancy: the ultimate challenge. *Clin Oncol (R Coll Radiol)*. 1989;1:11-18.
5. Jennifer K, Litton RL. Breast Cancer and Pregnancy: Current Concepts in Diagnosis and Treatment. *The Oncologist Express*. 2010;15:1238-1247.
6. Sukumvanich P. Review of current treatment options for pregnancy-associated breast cancer. *Clin Obstet Gynecol*, 2011;54:164-172.
7. Hahn KM, Johnson PH, Gordon N, et al. Treatment of pregnant breast cancer patients and outcomes of children exposed to chemotherapy in utero. *Cancer*. 2006;107:1219-1226.
8. Peccatori FA, Azim HA Jr, Scarfone G, et al. Weekly epirubicin in the treatment of gestational breast cancer (GBC). *Breast Cancer Res Treat*. 2009;115:591-594.
9. Azim HA Jr, Peccatori FA, Scarfone G, et al. Anthracyclines for gestational breast cancer: Course and outcome of pregnancy. *Ann Oncol*. 2008;19:1511-1512.
10. Giacalone PL, Laffargue F, Bénos P. Chemotherapy for breast carcinoma during pregnancy: A France national survey. *Cancer*. 1999;86:2266-2272.
11. Braems G, Denys H, De Wever O, et al. Use of tamoxifen before and during pregnancy. *Oncologist*, 2011;16(11):1547-1551.
12. Watson WJ. Herceptin (trastuzumab) therapy during pregnancy: association with reversible anhydramnios. *Obstet Gynecol*. 2005;105:642-643.
13. Mir O, Berveiller P, Ropert S, et al. Emerging therapeutic options for breast cancer chemotherapy during pregnancy. *Ann Oncol*. 2008;19(4):607-613.
14. Cullins SL, Pridjian G, Sutherland CM. Goldenhar's syndrome associated with tamoxifen given to the mother during gestation. *JAMA*. 1994;207:1905-1906.