

## Orofacial Abscess due to *Candida dubliniensis*: An Extensive Infection Caused by A Rare Yeast

*Candida dubliniensis*'e bağlı Orofasiyal Apse: Nadir Bir Mayanın Neden Olduğu Yaygın Bir Enfeksiyon

Chuan Hun Ding<sup>1</sup>, Asrul Abdul Wahab<sup>1</sup>, Toh Leong Tan<sup>2</sup>, Salamah Faisal Ummu<sup>3</sup>

<sup>1</sup>Department of Medical Microbiology & Immunology, Faculty of Medicine, Universiti Kebangsaan Malaysia, Kuala Lumpur, Malaysia

<sup>2</sup>Department of Emergency Medicine, Faculty of Medicine, Universiti Kebangsaan Malaysia, Kuala Lumpur, Malaysia

<sup>3</sup>Faculty of Medicine & Defence Health, Universiti Pertahanan Nasional Malaysia, Kuala Lumpur, Malaysia

### ABSTRACT

*Candida dubliniensis* is a pathogenic yeast which is rarely encountered in clinical practice. An 83-year-old HIV-negative woman with numerous medical comorbidities presented with a dental abscess which was preceded by a long-standing toothache. The right side of her face was swollen from the preauricular to the malar and submandibular regions. A computed tomography scan revealed a masseteric abscess with air pockets extending to the right temporalis muscle. She underwent two separate incision and drainage procedures, performed one week apart. A yeast which formed branched pseudohyphae with thick-walled triplet terminal chlamyospores was cultured from her pus specimen. The yeast was identified biochemically as *C. dubliniensis*. However, before any antifungal agent could be administered, the patient succumbed to her illness.

**Key Words:** *Candida dubliniensis*, fluconazole, orofacial abscess, terminal chlamyospores

Received: 02.19.2020

Accepted: 10.20.2020

### ÖZET

*Candida dubliniensis*, klinik pratikte nadiren karşılaşılan patojenik bir mayadır. Çok sayıda tıbbi komorbiditesi olan 83 yaşındaki HIV negatif bir kadın, öncesinde uzun süredir devam eden bir diş ağrısı olan bir diş absesi ile başvurdu. Yüzünün sağ tarafı kulak önünden malar ve submandibuler bölgelere doğru şişmişti. Bilgisayarlı tomografi taraması, sağ temporal kasına uzanan hava cepleri olan masseterik apse ortaya çıkardı. Bir hafta arayla iki ayrı kesi ve drenaj prosedürü uygulandı. Kalın duvarlı üçlü terminal klamidosporeler ile dallı psödohifalar oluşturan bir maya, irin örneğinden kültürlendi. Maya biyokimyasal olarak *C. dubliniensis* olarak tanımlandı. Bununla birlikte, herhangi bir antifungal ajan uygulanmadan, hasta kaybedilmiştir.

**Anahtar Sözcükler:** *Candida dubliniensis*, flukonazol, orofasiyal apse, terminal klamidosporeler

Geliş Tarihi: 19.02.2020

Kabul Tarihi: 20.10.2020

**ORCID IDs:** C.H.D. 0000-0001-6040-219X, A.A.W. 0000-0001-8283-6028, T.L.T. 0000-0002-6771-0141, S.F.U. 0000-0003-4383-6986

**Address for Correspondence / Yazışma Adresi:** Ding Chuan Hun, MD Department of Medical Microbiology & Immunology, Preclinical Building, Faculty of Medicine, Universiti Kebangsaan Malaysia, 56000 Cheras, Kuala Lumpur, Malaysia. **E-mail:** dingch@ppukm.ukm.edu.my

©Telif Hakkı 2021 Gazi Üniversitesi Tıp Fakültesi - Makale metnine <http://medicaljournal.gazi.edu.tr/> web adresinden ulaşılabilir.

©Copyright 2021 by Gazi University Medical Faculty - Available on-line at web site <http://medicaljournal.gazi.edu.tr/>

doi:<http://dx.doi.org/10.12996/gmj.2021.24>

## INTRODUCTION

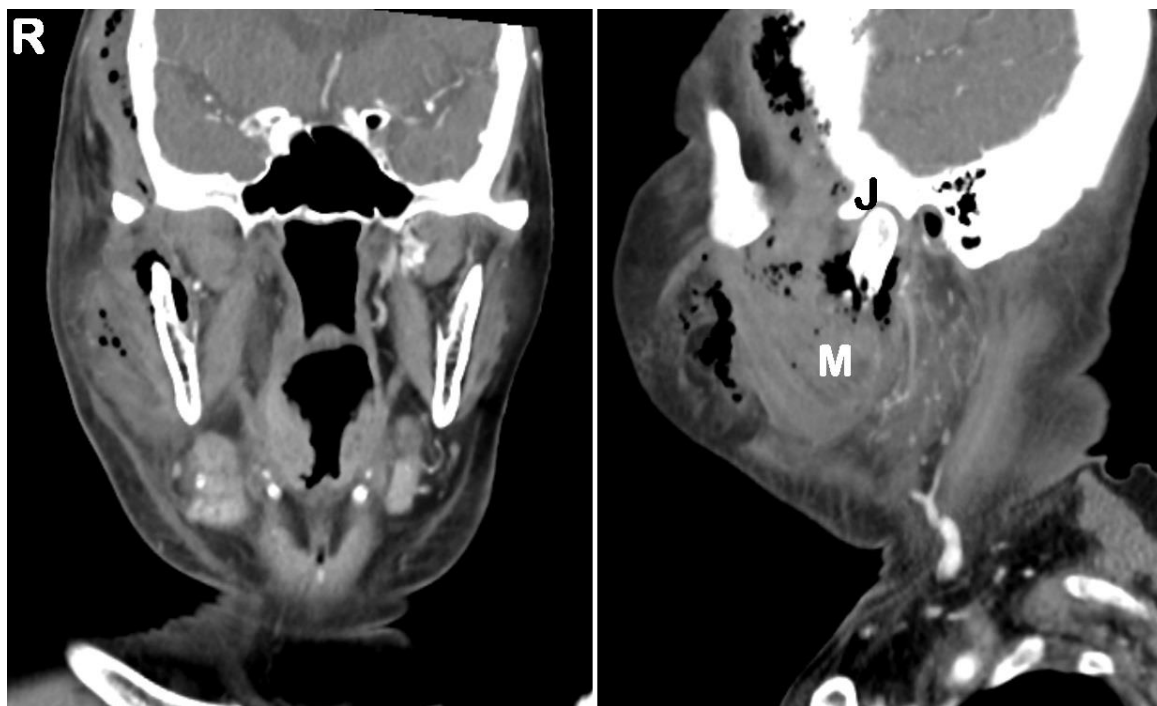
*Candida dubliniensis* was first reported in 1995, when it was isolated from the oral cavities of Irish HIV-positive individuals (1). Although it is classified as a non-*albicans* *Candida* (NAC) species, it shares similar traits with *Candida albicans* (2). However, compared to *C. albicans*, the prevalence of *C. dubliniensis* is very low, with studies reporting isolation rates of >60% for the former, but <3% for the latter (3). The designation of any yeast as a NAC is not merely of academic interest, because NACs such as *Candida krusei* and *Candida auris* are notorious for being fluconazole-resistant (4,5). *C. dubliniensis* in particular has caused concern with its inducible fluconazole resistance (3). Although the gamut of infections caused by *C. dubliniensis* is wide, most are limited to the oral cavity and systemic infections (e.g. candidemia) are rare (2). We report a case of a dental abscess caused by *C. dubliniensis* which progressed to become an extensive orofacial abscess that ultimately led to the demise of the patient.

## CASE REPORT

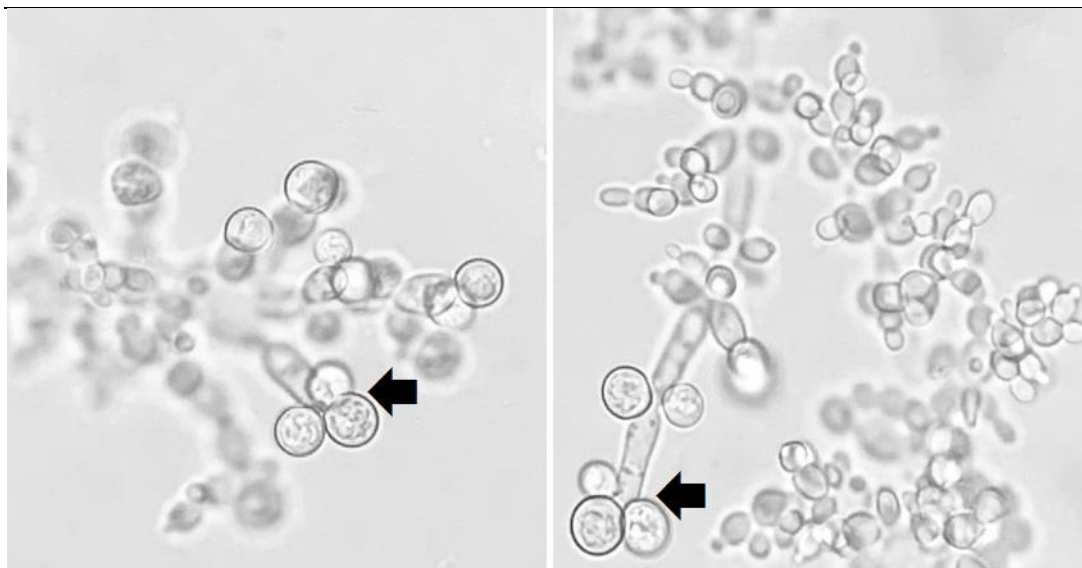An 83-year-old HIV-negative Chinese woman with multiple medical comorbidities (e.g. poorly controlled diabetes mellitus, chronic renal impairment and congestive heart failure) presented to the emergency department of UKM Medical Centre with a two-day history of right facial pain and swelling.

She had been having a right-sided toothache for the past three months which became complicated by a dental abscess. On examination, her body temperature was 37.6 °C, indicating a low-grade fever. The right side of her face was visibly swollen, tender and erythematous. The swelling was firm and fluctuant, and extended from the preauricular to the malar and submandibular regions. Crepitus was also palpable on the right temporal region. A computed tomography scan revealed a right masseteric abscess with air pockets extending to the right temporalis muscle (Figure 1).

She then underwent incision and drainage (I&D) of the right masticator and buccal space abscesses together with tooth extraction. IV amoxicillin-clavulanate 1.5 g q8h was commenced empirically. However, a week post I&D the patient's swelling was still apparent. Thus, a second I&D was attempted and 20 ml of pus was drained from the temporal space. This time, a yeast was cultured from the pus specimen. The yeast formed branched pseudohyphae with dense verticils of blastoconidia and thick-walled triplet terminal chlamydospores (Figure 2) after 24-48 h of cornmeal agar culture at 30 °C, suggesting *C. dubliniensis*. Biochemical identification using the VITEK 2 YST card (bioMérieux, France) confirmed the yeast's identity as *C. dubliniensis* with a 93% probability (bionumber: 6003544061301370). Antifungal susceptibility testing was then performed using the broth microdilution kit Sensititre YeastOne YO10 (Thermo Scientific, USA) and the antifungal minimal inhibitory concentration (MIC) values are presented in Table 1. However, before any antifungal could be administered, the patient succumbed to her illness. Up to the time of her demise, her blood cultures were persistently negative for bacterial and fungal organisms.



**Figure 1** : Coronal (right image) and sagittal (left image) views of the computed tomography scan showing a right masseteric abscess with air pockets extending to the right temporalis muscle. The right temporomandibular joint (J) and masseter muscle (M) are labeled in the sagittal view.



**Figure 2 :** Microscopic appearance of *C. dubliniensis* after 24-48 h of culture on cornmeal agar (x400 magnification). The black arrows point to thick-walled triplet terminal chlamydospores.

**Table 1.** Antifungal MIC values for *C. dubliniensis*

Antifungal agent	MIC value ( $\mu\text{g/ml}$ )
Amphotericin B	0.25
Fluconazole	0.25
Itraconazole	0.06
Voriconazole	0.03
Posaconazole	0.03
Micafungin	0.06
Anidulafungin	0.12
Caspofungin	0.12
5-flucytosine	0.25

MIC, minimal inhibitory concentration

## DISCUSSION

It is believed that *C. dubliniensis* is considerably less virulent than the more commonly isolated *C. albicans* (2,6). Although both are among the few *Candida* species endowed with the ability to form true hyphae (an important virulence determinant) in vitro, the ability of the former to do so in vivo appears to be impaired (2). Moreover, the former is more susceptible to the fungicidal activity of human leukocytes than the latter (6). Consistent with the published literature, our patient's candidiasis was also localized to the oral and facial regions, as evidenced by her persistently negative blood cultures. Thus, our patient's demise was likely to have occurred due to the deleterious combination of the infection itself with her advanced age and various medical co-morbidities. A history of retroviral infection need not necessarily be present for the infection to set in, as our patient was HIV-negative.

An early clue to the presence of *C. dubliniensis* can be sought from cornmeal cultures, in which the yeast forms pairs or triplets of chlamydospores terminally at the end of short branched pseudohyphae (1). In contrast, the phenotypically similar *C. albicans* forms single terminal chlamydospores. Apart from cornmeal agar morphology, growth at 42 °C can also assist in distinguishing *C. albicans* from *C. dubliniensis*, with only the former having the ability to grow at elevated temperatures (7).

For our yeast isolate, we did not attempt to culture it at 42°C because we had already confirmed its identity through biochemical testing (i.e. VITEK 2 identification).

The timely detection of any pathogen aids patient management by permitting targeted antimicrobial therapy to be commenced early. The antimycotic susceptibility profile of *C. dubliniensis* is generally favourable, with susceptibility rates between 76-100%, depending on the antifungal agent (8). Specifically, fluconazole susceptibility is as high as 86% (8). Consistent with what has been reported, our own *C. dubliniensis* isolate had low antifungal MIC values, inferring that it had no drug resistance issues. Thus, if *C. dubliniensis* can be presumptively identified early, fluconazole therapy can also be started early (i.e. before formal antifungal susceptibility results are ready). However, the patient should preferably be "fluconazole-naïve", because of inducible fluconazole resistance in *C. dubliniensis* (3).

## CONCLUSION

Cornmeal cultures should be undertaken in all candidiasis cases, particularly if the infection originates from or involves the oral cavity. The presence of triplet terminal chlamydospores presumptively identifies *C. dubliniensis*. Definitive identification should then be achieved through a commercially available biochemical yeast identification kit or platform. Any of the commonly prescribed antifungal agents may be employed for treatment, including fluconazole, provided the patient has not been previously exposed to this drug.

## Conflict of interest

No conflict of interest was declared by the authors.

## REFERENCES

- Sullivan DJ, Westerneng TJ, Haynes KA, Bennett DE, Coleman DC. *Candida dubliniensis* sp. nov.: phenotypic and molecular characterization of a novel species associated with oral candidiasis in HIV-infected individuals. *Microbiology* 1995; 141: 1507-21.
- Sullivan DJ, Moran GP, Pinjon E, Al-Mosaid A, Stokes C, Vaughan C, et al. Comparison of the epidemiology, drug resistance mechanisms, and virulence of *Candida dubliniensis* and *Candida albicans*. *FEMS Yeast Res* 2004; 4: 369-76.
- Yang CW, Barkham TM, Chan FY, Wang Y. Prevalence of *Candida* species, including *Candida dubliniensis*, in Singapore. *J Clin Microbiol* 2003; 41: 472-4.
- Ding CH, Situ SF, Steven A, Razak MFA. The pitfall of utilizing a commercial biochemical yeast identification kit to detect *Candida auris*. *Ann Clin Lab Sci* 2019; 49: 546-9.
- Ding CH, Zaki Z. Mixed non-albicans *Candida* fungemia: an uncommon but easily overlooked clinical entity. *Asian J Pharm Clin Res* 2018; 11, 8-10.
- Vilela MM, Kamei K, Sano A, Tanaka R, Uno J, Takahashi I, et al. Pathogenicity and virulence of *Candida dubliniensis*: comparison with *C. albicans*. *Med Mycol* 2002; 40: 249-57.
- Ells R, Kock JL, Pohl CH. *Candida albicans* or *Candida dubliniensis*? *Mycoses* 2011; 54: 1-16.
- Quindós G, Carrillo-Muñoz AJ, Arévalo MP, Salgado J, Alonso-Vargas R, Rodrigo JM, et al. In vitro susceptibility of *Candida dubliniensis* to current and new antifungal agents. *Chemotherapy* 2000; 46: 395-401.