

Pyogenic Granuloma of Ventral Surface of Tongue – A Rare Presentation

Dilin Ventral Yüzeyinin Piyojenik Granülomu - Nadir Bir Sunum

Vshakri Ehdam, Ramiza Ramza Ramli

Department of Otorhinolaryngology, Head & Neck Surgery, School of Medical Sciences, Universiti Sains Malaysia Health Campus, 16150 Kota Bharu, Kelantan, Malaysia

ABSTRACT

Oral pyogenic granuloma is a common benign lesion of oral cavity. It is a type of reactive hyperplasia of oral cavity apart from peripheral ossifying fibroma, peripheral giant cell granuloma and fibrous hyperplasia. Various etiopathogenesis have been proposed like infection, trauma and hormone. The presentation may varies depending on site of lesion, etiology factors and patient's activities. The common presentation is usually related to repeated trauma and chronic irritation to oral cavity subsites particularly to gingiva, lip, tongue and buccal mucosa. We present a case of pyogenic granuloma of ventral surface of tongue in young male adult football player with unusual presentation. Excision is still the treatment of choice in most of the centers, although other alternatives like cryosurgery and laser have been reported.

Key Words: Pyogenic granuloma, tongue, presentation.

Received: 01.28.2020

Accepted: 03.14.2020

ÖZET

Oral piyojenik granülom, ağız boşluğunun sık görülen iyi huylu bir lezyondur. Periferik kemikleşme fibroma, periferik dev hücreli granülom ve lifli hiperplazi dışında bir ağız boşluğu reaktif hiperplazisidir. Enfeksiyon, travma ve hormon gibi çeşitli etyopatogenezler önerilmiştir. Sunum lezyon yerine, etyoloji faktörlerine ve hastanın aktivitelere bağlı olarak değişebilir. Ortak sunum genellikle tekrarlanan travma ve ağız boşluğu alt bölgelerindeki kronik tahrişle, özellikle dişeti, dudak, dil ve bukkal mukoza ile ilgilidir. Genç erkek yetişkin futbolcunun alışılmadık bir sunumla dilin ventral yüzeyinin piyojenik granülom olgusunu sunuyoruz. Kriyocerrahi ve lazer gibi diğer alternatifler bildirilmiş olmasına rağmen, eksizyon hala merkezlerin çoğunda tedavi seçeneğidir.

Anahtar Sözcükler: Piyojenik granülom, dil, sunum.

Geliş Tarihi: 28.01.2020

Kabul Tarihi: 14.03.2020

ORCID IDs: V.E. 0000-0003-4802-2260, R.R.R. 0000-0001-8196-321X

Address for Correspondence / Yazışma Adresi: Vshakri Ehdam, Department of Otorhinolaryngology, Head & Neck Surgery, School of Medical Sciences, Universiti Sains Malaysia Health Campus, 16150 Kota Bharu, Kelantan, Malaysia, E-mail: kridamrong@gmail.com

©Telif Hakkı 2020 Gazi Üniversitesi Tıp Fakültesi - Makale metnine <http://medicaljournal.gazi.edu.tr/> web adresinden ulaşılabilir.

©Copyright 2020 by Gazi University Medical Faculty - Available on-line at web site <http://medicaljournal.gazi.edu.tr/>

doi:<http://dx.doi.org/10.12996/gmj.2020.107>

INTRODUCTION

Pyogenic granuloma is a benign non-neoplastic vascular proliferation of the skin and oral cavity (1). Oral pyogenic granuloma is a common type of reactive localized hyperplasia of the oral cavity (2-5). In the oral cavity, the most common site of this lesion to occur is gingival followed by lips, tongue, buccal mucosa, and hard plate, mucobuccal fold, and frenum¹. Various etiologic factors have been proposed for its formation such as chronic irritation related with exfoliation of deciduous teeth, trauma due to toothbrush, drugs, hormones, gingivitis, eruption of permanent teeth, faulty filling, food impaction and complete periodontitis (5).

The term pyogenic granuloma is now believed to be misnomer as the lesion is not related to infection (5). It is supported by the absent of pus and true granulation tissue. It is more common in female than male, possibly due to vascular effect of female hormone and pregnancy. It can occur in all age groups but predominantly in the second and fifth decade of life¹. Patient usually presented with local mass, discomfort, bleeding and underlying history of recurrent trauma or chronic irritation which usually due to a sharp tooth or a bad technique of tooth brushing.

Macroscopically it can appear smooth or lobulated exophytic lesion, usually small and erythematous and either pedunculated or sessile base. Microscopically, the epithelium is parakeratotic or non-keratinized stratified squamous epithelium overlying connective tissue stroma with high vascular proliferation. The main treatment of choice is excision. Recurrent rate is around 15.8% after excision (7).

CASE REPORT

Seventeen years old gentleman with no known medical illness and non-smoker presented with painless mass over the ventral surface of tongue for two months duration. He is football player and had history of trauma to the tongue during playing football two weeks prior to development of the lesion. It was start with formation of ulcer which later on became a mass. He was tackled by opponent during the match however unable to recall the exact mechanism of injury. The mass was gradually increasing in size and caused discomfort. Otherwise there were no history of fever, bleeding, dysphagia, odynophagia, shortness of breath, loss of appetite and loss of weight. There were no histories of betel nut chewing, consuming alcohol, expose to radiation or high-risk behaviour.

Upon examination noted exophytic mass at the ventral surface of tongue, measuring 1cmx1cm, smooth surface, well circumscribed and pedunculated base (Figure 1). There were no bleeding and discharge from the mass as well as it was non tender on palpation. Oral hygiene was good and no sharp tooth seen. Other ear, nose and throat examinations were unremarkable. In view of the benign looking lesion, patient was subjected for excision under local anaesthesia. The mass was successful excised using Colorado diathermy. Patient was review again in clinic one week after excision, noted raw area with minimal slough formation (Figure 2). Histopathology examination of the mass was confirmed pyogenic granuloma.

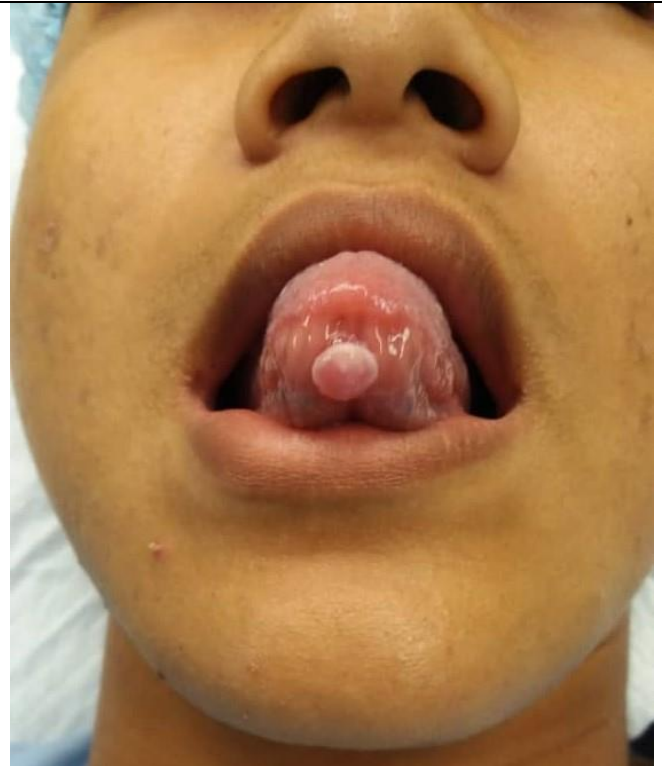

Figure 1. Exophytic mass at the ventral surface of tongue, smooth surface and well circumscribed.

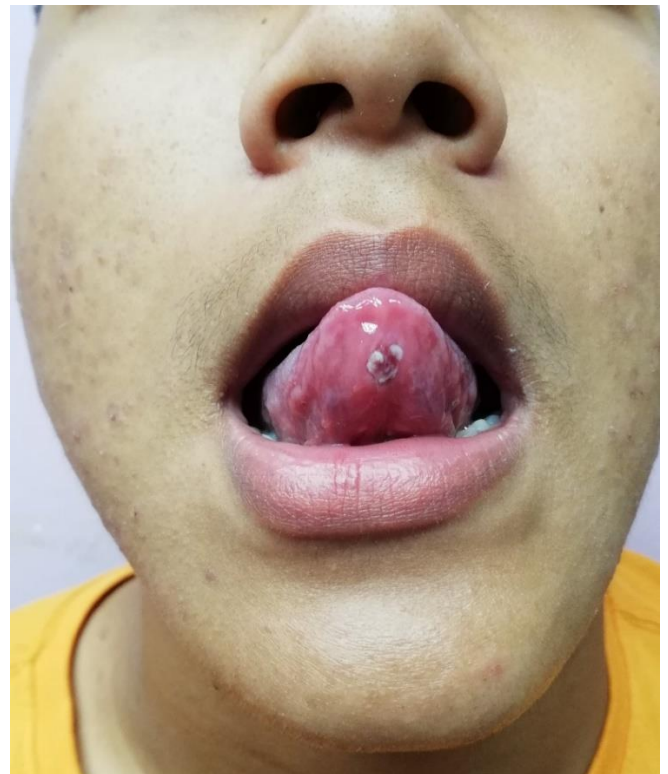


Figure 2. One week after excision noted raw area with minimal slough.

DISCUSSION

Pyogenic granuloma is also known as granuloma pediculatum benignum, pregnancy tumor, vascular epulis, Crocker and Hartzell's disease and lobular capillary hemangioma (1, 3). It is called pregnancy tumor as more than 5% of intraoral pyogenic granuloma occur in pregnancy due to increase in progesterone and estrogen level (7). Gingiva is a target organ for these hormones, explaining why oral pyogenic granuloma most commonly occurs at this region (2). The other factors for gingival predilection are due to calculus formation and foreign material within gingival crevice (5).

Trauma is usually the cause of extragingival oral pyogenic granuloma (8). It is believed to arise as a result of some minor trauma to the tissues that provide a pathway for invasion of nonspecific types of microorganisms. The tissues respond in a characteristic manner to these organisms of low virulence by the overzealous proliferation of a vascular type of connective tissue (9). It is also found that inflammation in oral pyogenic granuloma show slight destruction of fixed tissue cells, however stimulus to proliferation of vascular endothelium persists and exerts its influence over a long period of time. Trauma itself also has been suggested to cause release of various endogenous substances including angiogenic factors.

There is no reported case or study show sport or specifically playing football as a risk factor for oral pyogenic granuloma. Contact sport probably a very rare cause as oral cavity is well protected area from external injury. In addition, ventral surface of tongue is more protected compare to dorsum surface.

In our case, after excluding other possible cause, we conclude that injury during playing football is the most probably cause of oral pyogenic granuloma. This is consistent with history from the patient which claimed that the lesion starts with ulcer formation soon after injury during playing football and subsequently forming a mass of the granuloma at the same site. Patient was unable to recall the exact mechanism of injury. It was likely as consequences of self-tongue biting at the time he has been tackled by the opponent and unlikely from direct trauma from external source. Although tongue biting was involving both surfaces of tongue, however only ventral surface was effected in our patient. This may be explained by the different in layer of lining of dorsal versus ventral surface of tongue. Dorsal surface is lined by keratinizing squamous epithelium which is more withstand to injury compare to non-keratinizing squamous epithelium at ventral surface.

By applying the postulated theory of trauma as a cause of oral pyogenic granuloma, minor trauma to the ventral surface of tongue in our patient may provide a route for nonspecific types of microorganisms to invade and result in excessive tissue response and exuberant proliferation of vascular type of connective tissue. Furthermore, angiogenic factors are released as consequences of trauma itself. This is probably different mechanism from the more common presentation as the result of recurrent trauma or chronic irritation.

Differential diagnosis of this lesion can be other types of reactive localized hyperplastic lesions of oral cavity such as peripheral ossifying fibroma, peripheral giant cell granuloma and fibrous hyperplasia, mucocele, hemangioma, lymphangioma, conventional granulation tissue, malignancy, Kaposi's sarcoma, angiosarcoma and non-Hodgkin's lymphoma⁵. In our case, presentations of the patient as well as characteristics of the mass were more suggestive of benign lesion. However, in the case of elderly and present of risk factors like smoking and betel nut chewing, we should keep in mind the possibility of tongue carcinoma. There are two histological types of pyogenic granuloma, lobular capillary hemangioma and non-lobular capillary hemangioma (5). They have different pathogenic factors and pathway of evolution.

Excision is still the treatment of choice in most of the centers including our hospital. However there are reported new alternative approaches in order to reduce risks of bleeding, scarring and recurrence rate such as cryosurgery, Nd:YAG laser, flash lamp pulse dye laser, injection of ethanol or corticosteroid and sodium tetradecyl sulfate sclerotherapy. Recurrences are usually result from incomplete excision, present of etiology factors and re-injury of that area. Although the exact mechanism and relation of injury during playing football with the formation oral pyogenic granuloma is unclear, our patient may present again with recurrence as his etiology factor still present. He was given appointment in three months to review any recurrence of lesion.

CONCLUSION

Oral pyogenic granuloma is not an uncommon cause of soft tissue lesions of oral cavity however its presentations are varies depending on sex, age, site and size of the lesion as well as activity of the patients. Although it is benign, recurrence can occur if the causative factors still present. It is important to know risk factors for each particular patient. Histopathology examination is important for diagnosis and rule out other lesion with similar appearance.

Conflict of interest

No conflict of interest was declared by the authors.

REFERENCES

- 1.Sharma S, Chandra S, Gupta S, Srivastava S. Heterogeneous conceptualization of etiopathogenesis: Oral pyogenic granuloma. *Natl J Maxillofac Surg.* 2019;10:3–7.
- 2.Soyele OO, Ladeji AM, Adebiji KE, et al. Pattern of distribution of reactive localised hyperplasia of the oral cavity in patients at a tertiary health institution in Nigeria. *Afr Health Sci.* 2019;19:1687–94.
- 3.Dutra KL, Longo L, Grando LJ, Rivero ER. Incidence of reactive hyperplastic lesions in the oral cavity: a 10-year retrospective study in Santa Catarina, Brazil. *Braz J Otorhinolaryngol.* 2018. <https://doi.org/10.1016/j.bjorl.2018.03.006>.
- 4.Babu B, Hallikeri K. Reactive lesions of oral cavity: A retrospective study of 659 cases. *J Indian Soc Periodontol.* 2017;21:258–263.
- 5.Jafarzadeh H, Sanatkhani M, Mohtasham N, authors. Oral pyogenic granuloma: A review. *J Oral Sci.* 2006; 48:167–75.
- 6.Bhaskar SN, Jacoway JR, authors. Pyogenic granuloma – Clinical features, incidence, histology, and result of treatment: Report of 242 cases. *J Oral Surg.* 1966; 24:391–8.
- 7.Neychev DZ, Cholokova RB, Sbirkova TI, Kisselov SN, Bachurska SY, Atanasov DT. Pyogenic granulomas in the oral cavity: a series of cases. *J of IMAB.* 2019;25:2337-2342.
- 8.Krishnapillai R, Punnoose K, Angadi PV, Koneru A. Oral pyogenic granuloma—a review of 215 cases in a South Indian Teaching Hospital, Karnataka, over a period of 20 years. *Oral Maxillofac Surg.* 2012; 16:305–9.
- 9.Kamal R, Dahiya P, Puri A. Oral pyogenic granuloma: various concepts of etiopathogenesis. *J Oral Maxillofac Pathol.* 2012;16:79–82.