

Cigarette Smoking: The Only Risk Factor of a Case with Chronic Mesenteric Ischemia

Kronik Mezenterik İskemi'de Tek Risk Faktörü: Sigara

Cemile Özşürekci¹, Hatice Çalışkan¹, Gözde Şengül Ayçiçek¹, Rana Tuna Doğrul¹, Cafer Balcı¹, Fatih Sümer¹, Barbaros Çil²
Burcu Balam Yavuz¹, Mustafa Cankurtaran¹, Meltem Gülhan Halil¹

¹ Hacettepe University Medical Faculty, Internal Medicine Department, Division of Geriatrics, Ankara, Turkey

² Hacettepe University Medical Faculty, Radiology Department, Ankara, Turkey

ABSTRACT

Chronic mesenteric ischemia (CMI) is a rare condition and it could be misdiagnosed because lack of specific signs. Patients with chronic mesenteric ischemia (CMI) typically present with a history of the chronic intermittent abdominal pain, fear of eating and weight loss. The etiology of chronic mesenteric ischemia is multifactorial which includes atherosclerosis risk factors such as diabetes, hypertension, hyperlipidemia, smoking and obesity. Herein, we present a case whose only risk factor was smoking and presented with subacute abdominal pain. A 74-year-old woman was admitted to outpatient clinic with continuous abdominal pain, vomiting and diarrhea for 2 weeks. She had no other symptoms and chronic diseases. She is an active smoker for 58 pacs/year. Her physical examination revealed that diffuse abdominal pain without peritoneal signs. Laboratory results demonstrated an inflammatory condition however, abdominal ultrasound and endoscopic examination were in normal limits. Contrast enhanced abdominal CT revealed acute exacerbation of CMI. The patients treated with endovascular stent implantation and all symptoms were resolved. Chronic mesenteric ischemia could be seen with atypical presentations, solely due to smoking without multiple risk factors in older patients. Therefore, it should be remembered that the diseases may be encountered in atypical presentations in older patients. Moreover, smoking habits should be questioned and patients should be reminded about smoking cessation.

Key Words: Chronic Mesenteric Ischemia, Smoking, Older, Atypical presentation

Received: 12.06.2018

Accepted: 09.19.2019

ÖZET

Kronik mezenterik iskemi, nadir görülen ve akla getirilmediği takdirde tanı konulmasının zor olduğu bir hastalıktır. Kronik aralıklı karın ağrısı, yemek yemeden kaçınma ve kilo kaybı ile prezente olabilir. Kronik mezenterik iskemisinin etiolojisinde ateroskleroz neden olduğu bilinen diyabet, hipertansiyon, hiperlipidemi, sigara içme ve obezite gibi çoklu sebeplerin varlığı yer alır. Burada tek risk faktörü sigara içme olan ve subakut karın ağrısı ile başvuran bir vaka sunmaktayız. Yetmiş dört yaşında kadın hasta son 2 haftadır sürekli olan karın ağrısı, kusma ve ishal şikayetleri ile başvurdu. Başka herhangi bir semptom ve kronik hastalığı olmayan hastanın 58 paket/yıl olmak üzere aktif sigara içiciliği mevcuttu. Fizik muayenesinde batında yaygın hassasiyet olup defans bulgusuna rastlanmadı. Laboratuvar sonuçlarında inflamatuvar parametreleri yüksek olup, tüm batin ultrasonografisi ve 3 hafta önce yapılmış endoskopisi mevcut durumu için tanı koydurucu değildi. Yapılan kontrastlı batin tomografisi sonrasında hastada çölyak trunkus, inferior ve superior mezenterik arterlerde stenoz saptandı. Hastaya kronik mezenterik iskemisinin akut alevlenmesi tanısı konuldu. Vasküler girişimsel yöntem ile çölyak artere stentleme yapıldıktan sonra hastanın takibinde tüm şikayetleri geriledi. Kronik mezenterik iskemi, yaşlı bireylerde çoklu risk faktörü olmaksızın yalnızca sigara içmeye bağlı ortaya çıkabilir. Ayrıca yaşlı bireyler beklenenden farklı semptomlar ile farklı klinik tablolarda karşımıza çıkabilir. Bu nedenle yaşlı hastalarda, hastalıkların atipik prezentasyonda karşımıza gelebileceği unutulmamalıdır. Yaşlı hastalarda da sigara içimi sorgulanmalı ve hastalara sigara bırakma konusunda gerekli hatırlatmalarda bulunulmalıdır.

Anahtar Sözcükler: Kronik mezenterik iskemi, Sigara, Yaşlı hasta, Atipik Prezentasyon

Geliş Tarihi: 06.12.2018

Kabul Tarihi: 19.09.2019

ORCID IDs: C.Ö. 0000-0002-2373-183X, H.Ç. 0000-0001-9750-3840, G.Ş.A. 0000-0003-0528-8851, R.T.D. 0000-0001-9470-5113, C.B. 0000-0002-1478-1106, B.Ç. 0000-0003-1079-0088, B.B.Y. 0000-0002-4430-6146, M.C. 0000-0002-8213-7515, M.H. 0000-0001-7597-8140

Address for Correspondence / Yazışma Adresi: Cemile Özşürekci, MD Hacettepe University Medical Faculty Hospital Internal Medicine Department, Division of Geriatrics, Sıhhiye, Ankara, Turkey E-mail: cemile_gulbas@yahoo.com

©Telif Hakkı 2020 Gazi Üniversitesi Tıp Fakültesi - Makale metnine <http://medicaljournal.gazi.edu.tr/> web adresinden ulaşılabilir.

©Copyright 2020 by Gazi University Medical Faculty - Available on-line at web site <http://medicaljournal.gazi.edu.tr/>

doi:<http://dx.doi.org/10.12996/gmj.2020.14>

INTRODUCTION

Chronic mesenteric ischemia (CMI) is a rare condition and defined by stenosis or occlusions of the celiac artery, superior or inferior mesenteric artery. The disease usually manifests in patients above 60 years of age and females are more likely to be affected than males. Symptomatic CMI only accounts for less than 5 % of intestinal ischemic events. It is typically revealed by intermittent abdominal pain and abdominal bruits which is aggravated with food intake with preserved appetite. The diagnosis of CMI is sometimes difficult because of a lack of specific signs or due to its sometime quiet presentation (1). Severe malnutrition can be important clinical sign that raise the suspicion of CMI. The condition is frequently diagnosed only at an advanced stage. An imaging study can confirm the presence of a stenosis or occlusion involving the mesenteric vessels. Usually patients had abundant mesenteric collateral circulation, while gradual and progressive stenosis of one or more major mesenteric vessels (2-3).

There are multiple etiologies however, the most common cause is atherosclerosis. Common risk factors for atherosclerosis such as diabetes mellitus, hypertension, hyperlipidemia, cigarette smoking, obesity, insulin resistance are also etiologic risk factors for CMI. Patients often have atherosclerotic disease history, such as peripheral vascular disease, coronary artery disease, and/or cerebrovascular disease. We want to present a new case of CMI with no etiologic risk factor except smoking.

CASE REPORT

A 74-year-old woman was admitted to outpatient clinic with continuous abdominal pain, vomiting and diarrhea for 2 weeks. She had no other symptoms and chronic diseases. She is an active smoker for 58 pacs/year. Her physical examination revealed that diffuse abdominal pain without peritoneal signs, melena or hematochezia. Blood analysis showed Hb 14,9 g/dL, hematocrit 48.2%, white blood cell count 25600/mm³, absolute neutrophil count (ANC) 20000/mm³, platelets 394000/mm³, and C-reactive protein 7,49 mg/dL (0 to 0.8). In biochemical analysis, liver function tests, renal function tests and electrolytes were within normal limits, amylase were 90 U/l (25 to 100). Abdominal ultrasound imaging showed that no pathological sign. Endoscopic examination was performed 3 weeks before her admission and revealed chronic gastritis. Contrast enhanced computerized tomography showed proximal 1 cm segment of celiac truncus and inferior mesenteric artery had severe stenosis, proximal 4 cm segment of superior mesenteric artery totally occluded and perfused by collaterals, right renal artery and bilateral iliac arteries has severe stenosis and perfused by collaterals (Figure 1). She was diagnosed with acute exacerbation of CMI and hospitalized. The patient underwent visceral angiography with placement of stents in the celiac artery and seen collateral perfusions sufficient for mesenteric arteries. She was evaluated for hypertension diabetes mellitus, hyperlipidemia and no other risk factors were showed. After the stent implantation, she was free from abdominal pain and discharged from hospital.

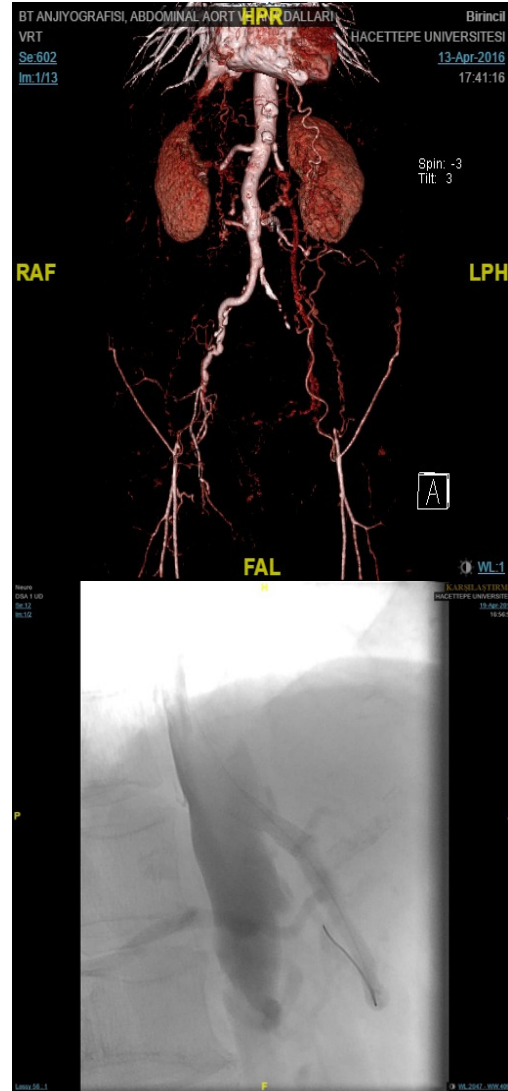


Figure 1.

CONCLUSIONS

Chronic mesenteric ischemia is a rare, but potentially life-threatening condition. Establishing a successful diagnosis is dependent upon suspicion and knowledge of mesenteric ischemia. Also atypical presentations like continuous acute abdominal pain must alert the doctors for mesenteric ischemic events. This case represents us that atypical presentation of illnesses and peripheral atherosclerosis in the statue of low risk factors could be seen in elderly. Atherosclerosis is increasing in prevalence with age and common in geriatric population. Although there are many risk factors for atherosclerosis formation, current cigarette smoking is enough for common atherosclerosis in elderly (4). Smoking cessation in all age groups is very important.

Conflict of interest

No conflict of interest was declared by the authors.

REFERENCES

- 1.Hohenwarter EJ. Chronic mesenteric ischemia: diagnosis and treatment. *Semin Interv Radiol.* 2009;26:345–51.
- 2.Allen RC, Martin GH, Rees CR. Mesenteric Angioplasty in the treatment of Chronic Intestinal ischemia. *J Vasc Surg.* 1996;24:415–23.
3. Mikkelson WP. Intestinal Angina: Its surgical significance. *Am J Surg.* 1957;94:262–9.
4. Herrington W, Lacey B, Sherliker P, Armitage J, Lewington S. Epidemiology of Atherosclerosis and the Potential to Reduce the Global Burden of Atherothrombotic Disease. *Circ Res.* 2016 Feb 19;118:535-46.