

## The Effect of Mitomycin C on the number of Keratocytes on the Posterior Wall of the Stroma of Cornea after Photorefractive Keratectomy

Fotorefraktif Keratektomi Sonrası Mitomisin C'nin Kornea Stromasının Arka Duvarındaki Keratosit Sayısı Üzerine Etkisi

Hanieh Ahmadi<sup>1</sup>, Majid Reza Sheikh Rezaei<sup>1</sup>, Mohammad Naeim AminiFard<sup>2</sup>, Hamed Jafarpour<sup>3</sup>

<sup>1</sup> Department of Ophthalmology, Bu-Ali Sina Hospital Research Center, Mazandaran University of Medical Sciences, Sari, Iran

<sup>2</sup> Department of Ophthalmology, Zahedan university of Medical Sciences, Zahedan, Iran

<sup>3</sup> Medical Student, Student Research Committee, Mazandaran University of Medical Sciences, Sari, Iran

### ABSTRACT

**Introduction:** We have decided to investigate its effect on a number of keratocytes on the posterior wall of the stroma of cornea, in which stromal removal depth has little effect on.

**Methods:** This is a cohort clinical trial. All patients with the required criteria for entering the study after filling the consent, they were first examined by the Confoscan III system and then the number of keratocytes on the posterior wall of the stroma of cornea was measured. At the end of the treatment, patients were followed up (end of month 3) with posterior keratocytes cells' count.

**Results:** In this study, out of 13 patients (26 eyes) referring to the clinic, 8 (51.5%) were male and 5 (38.5%) were female. The mean refractive index before surgery was  $-3.6 \pm 0.8$  diopters. Also, the mean number of keratocytes on the posterior wall of the stroma of cornea after surgery was  $714.7 \pm 12.9$ , with the lowest of 697.5 and the highest of 726.3. There was no statistically significant difference between the number of keratocytes before and after surgery ( $P = 0.838$ ).

**Conclusion:** The use of 0.02% mitomycin, topically, during keratorefractive surgery does not affect the number of keratocytes on the posterior wall of the stroma of cornea.

**Key Words:** Photorefractive Keratectomy, mitomycin C, keratocyte

**Received:** 06.07.2018

**Accepted:** 07.17.2018

### ÖZET

**Amaç:** Stromal çıkma derinliğinin çok az etkisi olduğu korneanın stroma posterior duvarındaki keratositler üzerindeki etkisini araştırmaya karar verdik.

**Yöntem:** Bu bir kohort klinik çalışmasıdır. Onamı doldurduktan sonra çalışmaya girmek için gerekli kriterleri olan tüm hastalar, önce Confoscan III sistemi ile muayene edildi ve daha sonra korneanın stromasının arka duvarındaki keratosit sayısı ölçüldü. Tedavinin sonunda, hastalar arka keratosit hücrelerinin sayımıyla (3 ayın sonunda) takip edildi.

**Bulgular:** Bu çalışmada kliniğe başvuran 13 hastanın 26'sı (8 gözü), 8'i (% 51,5) erkek, 5'i (% 38,5) kadındı. Ameliyat öncesi ortalama kırılma indisi  $-3.6 \pm 0.8$  diyopterde. Ayrıca, ameliyat sonrası kornea stroma posterior duvarındaki ortalama keratosit sayısı  $714.7 \pm 12.9$  idi, en düşük 697.5 ve en yüksek 726.3 idi. Cerrahi öncesi ve sonrası keratosit sayısı arasında istatistiksel olarak anlamlı bir fark yoktu ( $P = 0,838$ ).

**Sonuç:** Topikal olarak, keratorefraktif cerrahi sırasında% 0.02 mitomisin kullanımı, korneanın stroma duvarının arka duvarındaki keratosit sayısını etkilemez.

**Anahtar Sözcükler:** Photorefractive Keratectomy, mitomycin C, keratocyte

**Geliş Tarihi:** 07.06.2018

**Kabul Tarihi:** 17.07.2018

**ORCID ID:** H.A. 0000-0002-1981-2549, M.R.S.R 0000-0002-1105-7294, H.J. 0000-0003-0652-2363

**Address for Correspondence / Yazışma Adresi:** Hamed Jafarpour, Medical Student, Student Research Committee, Faculty of Medicine, Mazandaran University of Medical Sciences, Sari, Iran. E-mail: hamed.jafarpour7@gmail.com

©Telif Hakkı 2020 Gazi Üniversitesi Tıp Fakültesi - Makale metnine <http://medicaljournal.gazi.edu.tr/> web adresinden ulaşılabilir.

©Copyright 2020 by Gazi University Medical Faculty - Available on-line at web site <http://medicaljournal.gazi.edu.tr/>

doi:<http://dx.doi.org/10.12996/gmj.2020.01>

## INTRODUCTION

Photorefractive keratectomy is a popular refractive surgery that has been shown to be effective and safe for refractive errors of the eye (1). The argon fluoride laser excimer with a wavelength of 193 nm reduces the refractive errors through the exfoliation of the anterior stroma of cornea and changing the curve of the anterior surface of the cornea. The absorption rate of 193 nm in the cornea is extremely high. The carbon-carbon and nitrogen-carbon bindings form a large part of the cornea collagen peptides. A photon with a wavelength of 193 nm has a remarkable ability to break down the bonds directly (2). Laser excimer radiation divides the cornea collagen peptides into smaller portions, and with each laser pulse, a clear amount of corneal tissue is removed from its surface. In photorefractive keratectomy, after removing the epithelium, the tissue is exfoliated to change the corneal refractive efficiency. The natural structure of the extracellular matrix is changed after PRK. Along with the change in cell numbers and form, a variable amount of disorganized extracellular matrix and myofibroblast is created, with the final result of reduced transparency of the tissue by creating corneal sub epithelial opacity, which is clinically significant in some patients (2). Many studies have shown that reduction of corneal opacity occurrence after photorefractive keratectomy with mitomycin C is possible alongside surgery (3). Mitomycin C is an anti-tumor alkalinizing drug that was first isolated in 1956 from *Streptomyces caespitosus* (4). MMC has its own effect by interfering with DNA replication, thereby preventing protein production and inhibition of mitoses. It works in all the cells, regardless of the stage of division of the cells, but it has the most anti-proliferation effect on the cells that are rich in mitosis. It has different uses in ophthalmology (4). Since the early 1960s, MMC has been used to prevent recurrences after the Pterygia surgery, as well as to increase the success of filtration practice and as an alternative to conjunctival epithelial neoplasia. MMC is also used as an effective pharmacokinetic method for regulating the restorative response, reducing fibrosis, and improving the result of keratorefractive surgery (5). Prophylactic use of 0.02% mitomycin C solution decreases corneal opacity, improves uncorrected vision (UCVA), thereby improving visual outcome after corneal refraction (6). Despite these results, researchers have shown remarkable toxic effects of MMC and there are concerns about the side effects of this drug. Mitomycin c has the ability to destroy all three major corneal cell types including epithelial cells (differentiated epithelium and limbal zone), stromal (keratocytes) and endothelial (7, 8). Since PRK is one of the most common refractive corneal surgeries at Zahedan Eye Center, and in all of these patients, topical mitomycin C is used to prevent corneal opacity, we have decided to investigate its effect on number of keratocytes on the posterior wall of the stroma of cornea, in which stromal removal depth has little effect on.

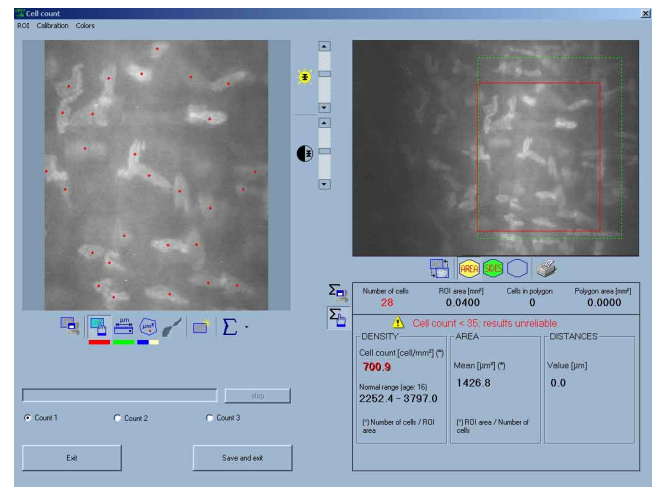
## METHODS

This is a cohort clinical trial study. Patients referred to Al-Zahra Ophthalmology Clinic were nominated for a photorefractive keratectomy and had myopia with -2 to -5 D. Sampling was done easily among patients referring to Al-Zahra Ophthalmology Hospital

Inclusion Criteria: patients undergoing photorefractive keratectomy

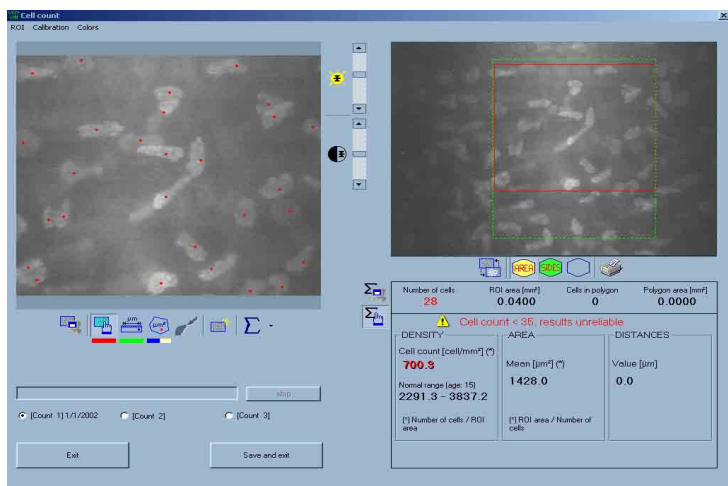
Exclusion criteria: prohibition of refractive surgery such as dry eye, blepharitis, corneal ulcer, corneal hump, dystrophy with corneal degeneration, cataracts, glaucoma, retinal diseases, and those with less than 350 microns have a remaining thickness of corneal stroma.

All patients with the required criteria for entering the study were examined and configured by the Confoscan III device (Nidek company) after filling out the consent form. The information obtained was recorded on the disk (Figure 1).



**Figure1.** Number of posterior Stromal keratocytes before the surgery.

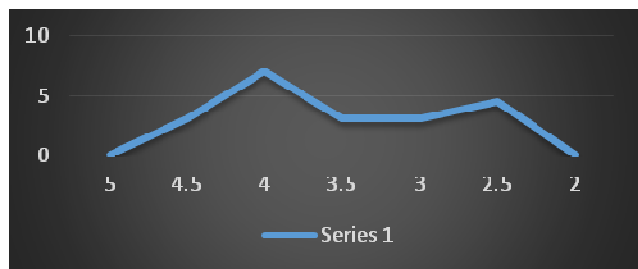
Clinical data for patients, including uncorrected vision measurements and best visibility corrected by spectacles (UCVA, BSCVA) by the Snellen table, refractive manifest errors and cycloplegic, anterior segmental examination with a slit lamp, open pupil examination of the retina, pressure measurement of the eyes and pentacles were done and recorded on special forms. At the end of the follow-up of the patients (end of month 3), recounting the number of posterior keratocyte cells was performed and registered by the Confoscan III machine (Fig. 2). To carry out the keratocyte count on each level, keratocytes were manually taken from the center of the cornea of the patients. A complete layer of endothelium to epithelium was obtained at each time, and it was represented as a curve by a z-scan, and the distance of 50 microns, posterior to the membrane was considered as the posterior layer of the stroma. Subsequently, by Navis program that was installed on the device by default, the cells were manually counted in an area of 0.4 mm<sup>2</sup> (ORI) with a wavelength of 193 nm, 40 Hz constant pulse repetition and a 96-millijoule ray exposure. A 5.0% tetracaine hydrochloride topical drop was used for corneal anesthesia, 10% betadine as antiseptic for skin around the eye and eyelid for 3 minutes and 20 cc of normal saline solution for washing. 8 mm epithelium of the center of the cornea was removed using alcohol in 20 seconds and photoablation was performed by the software. After preparing mitomycin C, vials of 2 mg with 10 cc distilled water were then diluted, then 0.02% mitomycin-impregnated sponge after complete drying on the cornea stroma after laser harvest was kept for 20 Seconds. After that, it was washed with a BSS solution and a replaced by a contact lens. After surgery, patients were treated with 0.5% chloramphenicol drop for 6 weeks every hour, as well as betamethasone drop 0.1% to complete corneal epithelization every 6 hours. After complete repair of corneal epithelium (between days 3 and 5), the contact lens was removed and follow-up examinations were performed on days 1,3,7 and months 1,3,6 after the surgery. As mentioned above, at the end of the month 3, recounting the number of posterior keratocyte cells was repeated and registered by the Confoscan III machine. At the end, the data collected by examinations before and after the operation were analyzed by SPSS software version 18 and by paired t-test exams.



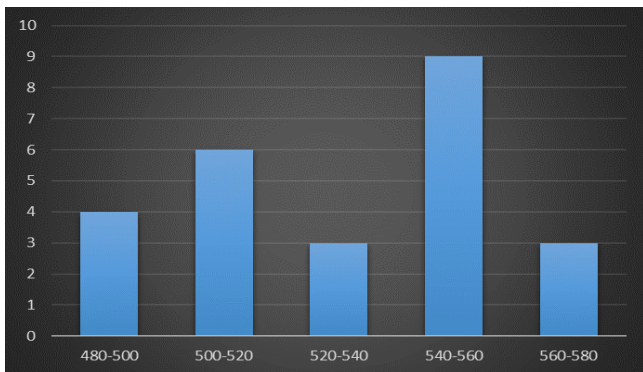
**Figure 2.** Number of posterior stromal keratocytes after the surgery in the same patient.

**RESULTS**

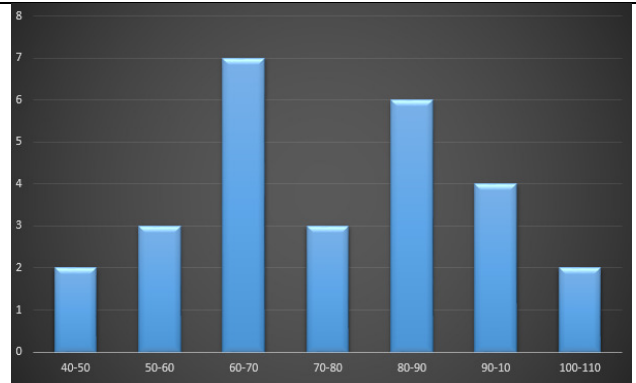
In this study, out of 13 patients (26 eyes) referring to the clinic, 8 (51.5%) were male and 5 (38.5%) were female. The mean refraction index before surgery was  $-3.6 \pm 0.8$  diopters. The lowest and highest rates were  $-5$  and  $-2.25$  (chart 1). In this study, the mean corneal thickness of patients was  $538.1 \pm 41.2$  microns. The minimum thickness was 485 microns and the highest was 879 microns (chart 2), with a mean ablation rate of  $74.7 \pm 15.6$  patients. The lowest level was 46.4 and the highest was 103.8 (chart 3). The mean number of posterior keratocytes of the posterior wall of the corneal stroma before the surgery was  $714.6 \pm 12.1$  (Figure 1), and its lowest value was 698.5 and the highest was 726 (chart 4). Also, the mean number of posterior keratocytes of the posterior wall of the corneal stroma after the surgery was  $714.7 \pm 12.9$  (Figure 2), with the lowest of 697.5 and the highest of 726.3 (chart 5). There was no statistically significant difference between the number of keratocytes before and after surgery ( $P = 0.838$ ) (Table 1).



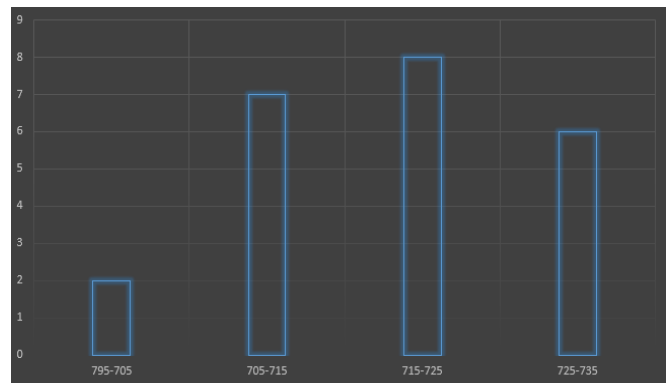
**Chart 1.** Average thickness of patients' cornea.



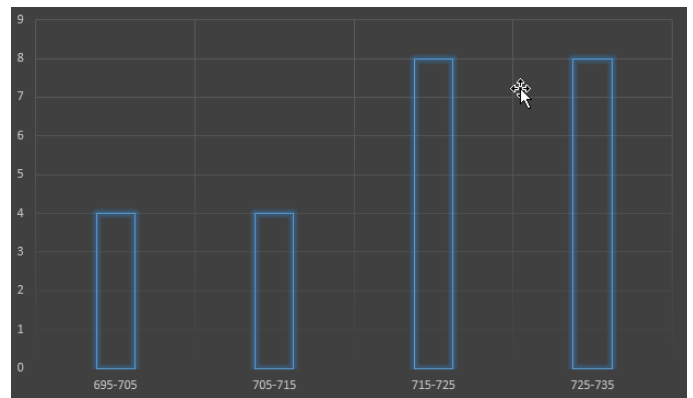
**Chart 2.** Patients' corneal thickness indexes.



**Chart 3.** Patients' ablation amount.



**Chart 4.** Average number of keratocytes of posterior wall of stroma of cornea before the surgery



**Chart 5.** Average number of keratocytes of posterior wall of stroma of cornea after the surgery

**Table 1.** Number of keratocytes of posterior wall of stroma of cornea before and after the surgery

P-Value	Difference (Average $\pm$ Standard Deviation)	After the surgery (Average $\pm$ Standard Deviation)	Before the surgery (Average $\pm$ Standard Deviation)	Number of keratocytes of posterior wall of stroma of cornea
0.838	-0.08 $\pm$ 1.72	714.7 $\pm$ 12.9	714.6 $\pm$ 12.1	

## DISCUSSION

Prophylactic use of MMC may be a useful adjuvant treatment, especially in high risk cases; however, the potential MMC toxicity is a concern, and therefore the risk and benefit ratio of it should be evaluated (9). Previous studies have shown that 0.02% mitomycin is less effective in reducing post-PRK operation opacity (4). Damage to epithelial cells during LASEK surgery or PRK leads to the release of cytokines, including IL-1, which ultimately activates the apoptosis of keratocytes via Fas-Fas Ligand (4). MMC can prolong the apoptosis of keratocytes after PRK (10, 11). In the usual way, following the regional apoptosis of keratocytes, their proliferation and the conversion of keratocytes to myofibroblasts, causes scarring. The process of converting keratocytes into myofibroblasts is inhibited by corticosteroids and MMC, which leads to decreased scarring (12). In this study, the effect of MMC on the number of keratocytes on the posterior wall of the stroma of cornea was evaluated, and there was no change in the number of corneal keratocytes before and after surgery, and there was no statistically significant difference between them. Most studies have also been consistent with our study. In a study by Midena et al. In 2007, PRK with 0.02% mitomycin C did not have a reverse effect on the number of corneal keratocytes (13). Goldsberry et al. in 2007 also found that MMC prescription to prevent opacity after PRK surgery had no significant quantitative and qualitative effect on endothelial cell density and morphometric parameters (9). Katbab et al. in 2008 concluded that the use of mitomycin C in the surgical site in keratorefractive surgeries did not have a reverse effect on epithelial repair and the location of the flap or endothelium health, and recommended more human studies (14). Of course, in a number of studies, the results also differed with our study, so in a study by Lee et al in 2001 it was shown that prescription of topical MMC cause apoptosis of keratocytes and may cause myofibroblasts to die through the induction of apoptosis and necrosis (15). Netto et al. in 2006 reported the reduction of cellularity of the anterior corneal stroma in one month after MMC prescription (16). Similarly, Kim et al. in 2003 reported low cellular continuity more than 6 months after PRK using MMC (17). In the current study, there was no reduction in keratocytes' count within 3 months of follow-up, so in this study, topical use of mitomycin C with the concentration and duration mentioned is safe and did not have any reverse effect on epithelial repair or endothelial health during the keratorefractive surgery; In general, it indicates the effectiveness of this therapeutic approach. More follow-up is needed to study the long-term complications of mitomycin C and careful usage is recommended to prevent so.

## CONCLUSION

The use of 0.02% mitomycin, topically, during keratorefractive surgery does not affect the number of keratocytes on the posterior wall of the stroma of cornea. According to the results of the present study, it is suggested that a study with a larger number of samples, with a longer follow-up time and a longer period of time with 0.02% MMC, should be considered.

## Conflict of interest

No conflict of interest was declared by the authors.

## Acknowledgment

This article is the result of the dissertation of Resident of Ophthalmology, Zahedan University of Medical Sciences (Thesis number: T-533). Special Thanks to the Deputy of Research and Technology of Zahedan University of Medical Sciences who sponsored this research financially and spiritually.

## REFERENCES

- Rajan MS, Jaycock P, O'Brart D, Nystrom HH, Marshall J. A long-term study of photorefractive keratectomy: 12-year follow-up. *Ophthalmology*. 2004;111:1813-24.
- Mohan RR, Hutcheon AE, Choi R, Hong J, Lee J, Mohan RR, et al. Apoptosis, necrosis, proliferation, and myofibroblast generation in the stroma following LASIK and PRK. *Experimental eye research*. 2003;76:71-87.
- Carones F, Vigo L, Scandola E, Vacchini L. Evaluation of the prophylactic use of mitomycin-C to inhibit haze formation after photorefractive keratectomy. *Journal of Cataract & Refractive Surgery*. 2002;28:2088-95.
- Pak JH, Lee SY, Tchah H. Mitomycin C-induced reduction of keratocytes and fibroblasts after photorefractive keratectomy. *Investigative ophthalmology & visual science*. 2004;45:2978-84.
- Majmudar PA, Forstot SL, Dennis RF, Nirankari VS, Damiano RE, Brenart R, et al. Topical mitomycin-C for subepithelial fibrosis after refractive corneal surgery. *Ophthalmology*. 2000;107:89-94.
- Rubinfeld RS, Pfister RR, Stein RM, Foster CS, Martin NF, Stoleru S, et al. Serious complications of topical mitomycin-C after pterygium surgery. *Ophthalmology*. 1992;99:1647-54.
- Dougherty PJ, Hardten DR, Lindstrom RL. Corneoscleral melt after pterygium surgery using a single intraoperative application of mitomycin-C. *Cornea*. 1996;15:537-40.
- Talamo JH, Gollamudi S, Green WR, De La Cruz Z, Filatov V, Stark WJ. Modulation of corneal wound healing after excimer laser keratomileusis using topical mitomycin C and steroids. *Archives of Ophthalmology*. 1991;109:1141-6.
- Goldsberry DH, Epstein RJ, Majmudar PA, Epstein RH, Dennis RF, Holley G, et al. Effect of mitomycin C on the corneal endothelium when used for corneal subepithelial haze prophylaxis following photorefractive keratectomy. *Journal of Refractive Surgery*. 2007;23:724-7.
- Lai Y-H, Wang H-Z, Lin C-P, Chang S-J. Mitomycin C alters corneal stromal wound healing and corneal haze in rabbits after argon-fluoride excimer laser photorefractive keratectomy. *Journal of ocular pharmacology and therapeutics*. 2004;20:129-38.
- Azar DT, Jain S. Topical MMC for subepithelial fibrosis after refractive corneal surgery. *Ophthalmology*. 2001;108:239-40.
- Wilson SE, Mohan RR, Hong J-W, Lee J-S, Choi R, Mohan RR. The wound healing response after laser in situ keratomileusis and photorefractive keratectomy: elusive control of biological variability and effect on custom laser vision correction. *Archives of Ophthalmology*. 2001;119:889-96.
- Midena E, Gambato C, Miotto S, Cortese M, Salvi R, Ghirlando A. Long-term effects on corneal keratocytes of mitomycin C during photorefractive keratectomy: a randomized contralateral eye confocal microscopy study. *Journal of Refractive Surgery*. 2007;23:S1011-54.
- Katbab A, Dabiri F, Eghtedari M, Attarzadeh A. Histopathologic Changes Induced by Topical Mitomycin-C in Rabbit Corneas. 2007.
- Lee JS, Oum BS, Lee SH. Mitomycin C influence on inhibition of cellular proliferation and subsequent synthesis of type I collagen and laminin in primary and recurrent pterygia. *Ophthalmic research*. 2001;33:140-6.
- Netto MV, Mohan RR, Sinha S, Sharma A, Gupta PC, Wilson SE. Effect of prophylactic and therapeutic mitomycin C on corneal apoptosis, cellular proliferation, haze, and long-term keratocyte density in rabbits. *Journal of refractive surgery*. 2006;22:562-74.
- Tchah H, Lee S-a, Sung K, Cho BJ, Kook MS. Apoptosis in keratocytes caused by mitomycin C. *Investigative ophthalmology & visual science*. 2003;44:1912-7.