

A Diagnostic Conundrum in a Localized Ascending Aortic Aneurysm

Lokalize Çıkan Aort Anevrizmasında Tanı İncelikleri

Affirul Chairil Ariffin¹, Hanizah Ngadiron¹, Firdaus Hayati², Nornazirah Azizan³, Fairrul Kadir⁴, Andee Dzulkarnaen Zakaria⁵

¹ Faculty of Medicine, Universiti Sains Islam Malaysia, Kuala Lumpur, Malaysia

² Department of Surgery, Faculty of Medicine and Health Sciences, Universiti Malaysia Sabah, Sabah, Malaysia

³ Department of Pathobiology and Medical Diagnostic, Faculty of Medicine and Health Sciences, Universiti Malaysia Sabah, Sabah, Malaysia

⁴ Department of Medicine, Faculty of Medicine and Health Sciences, Universiti Malaysia Sabah, Sabah, Malaysia

⁵ Department of Surgery, School of Medical Sciences, Universiti Sains Malaysia, Kelantan, Malaysia

ABSTRACT

Aortic dissection (AD) is an uncommon life-threatening emergency. Its development is usually subtle and easily missed. On the other hand, an aneurysm nearly always requires immediate surgical intervention. Both interventions are technically different and pose their own challenges. We experienced a distinct case of AD of the ascending aorta in a 65-year-old lady, who presented with a sudden onset of severe chest pain and shortness of breath. Thoracic aortic aneurysm was suspected as computed tomography revealed a saccular aneurysm of the proximal ascending aorta with no involvement of the valve and aortic branches. Surgery was decided after considering the risk of rupture and mortality. However, a diagnosis of localized aortic dissection was discovered and repaired accordingly. We discuss the pitfalls of diagnostic modalities and the techniques of surgical repair.

Key Words: Saccular, aneurysm, aortic dissection, goretex, graft

Received: 05.04.2018

Accepted: 08.15.2018

ÖZET

Aort disseksiyonu (AD) nadir bir hayatı tehdit eden acil durumdur. Gelişimi genellikle gizlidir ve kolayca gözden kaçır. Öte yandan, bir anevrizma hemen her zaman acil cerrahi müdahale gerektirir. Her iki müdahale de teknik olarak farklıdır ve kendi zorluklarını ortaya çıkarır. Başvuru sırasında 65 yaşında olan bir bayanda, ani başlayan şiddetli göğüs ağrısı ve nefes darlığı ile AD'nin ayrı bir olgusunu yaşadık. Hastada toraks aort anevrizması bilgisayarlı tomografinin, kapak ve aortik dalların tutulumu olmaksızın proksimal inen aortun bir sakküler anevrizmasını ortaya koyması nedeniyle şüphelenildi. Rüptür ve mortalite riski göz önüne alınarak cerrahi karar verildi. Bununla birlikte, lokalize aort disseksiyonu tanısı konuldu ve buna göre onarıldı. Burada, tanı yaklaşımları ve cerrahi onarım tekniklerinin tehlikelerini tartıştık.

Anahtar Sözcükler: Sakküler, anevrizma, aort disseksiyonu, goreteks, greft

Geliş Tarihi: 04.05.2018

Kabul Tarihi: 15.08.2018

INTRODUCTION

Aortic dissection (AD) is a life-threatening affliction necessitating urgent intervention. Its development is subtle and its presentation may imitate other conditions such as ruptured aneurysm and myocardial infarction. All these conditions pose a guarded prognosis if mismanagement occurs. The morbidity and mortality in fact are dreadful despite surgical repair. AD develops when a tear in the intimal layer exposes the underlying media, hence causing a dissected space. The space occupying blood in between the intimal flap and the adventitia creates a false lumen. It is commonly associated with long standing hypertension, connective diseases as well as trauma(1). The surgical strategy used for this case was removal of the thrombus with insertion of an inlay unigraft for anastomosis and closure of the false lumen by tissue adhesives.

CASE REPORT

A 65-year-old lady presented to us with chest discomfort associated with difficulty in breathing. It was not associated with sweating or radiating pain. She was previously well. She has a background of hypertension and diabetes mellitus. The examination revealed an overweight elderly lady with a high blood pressure and stable pulse rate. Clinically, there was no radio-radial or radio-femoral delay. Other systemic examinations were unremarkable.

Blood investigations were within normal range. Chest radiograph showed a widened mediastinum. Transoesophageal echo (TOE) revealed a good left ventricular function with ejection fraction of 79%, slightly dilated right atrium, and minimal pericardial effusion.

Address for Correspondence / Yazışma Adresi: Firdaus Hayati, MD Department of Surgery, Faculty of Medicine and Health Sciences, Universiti Malaysia Sabah, Sabah, Malaysia E-mail: firdaushayati@gmail.com

©Telif Hakkı 2018 Gazi Üniversitesi Tıp Fakültesi - Makale metnine <http://medicaljournal.gazi.edu.tr/> web adresinden ulaşılabilir.

©Copyright 2018 by Gazi University Medical Faculty - Available on-line at web site <http://medicaljournal.gazi.edu.tr/>

doi:<http://dx.doi.org/10.12996/gmj.2018.98>

From the CT scan, a saccular aneurysm was visualized arising from the proximal ascending aorta without valve involvement (Figure 1). A decision for emergency repair was made in view of impending rupture.

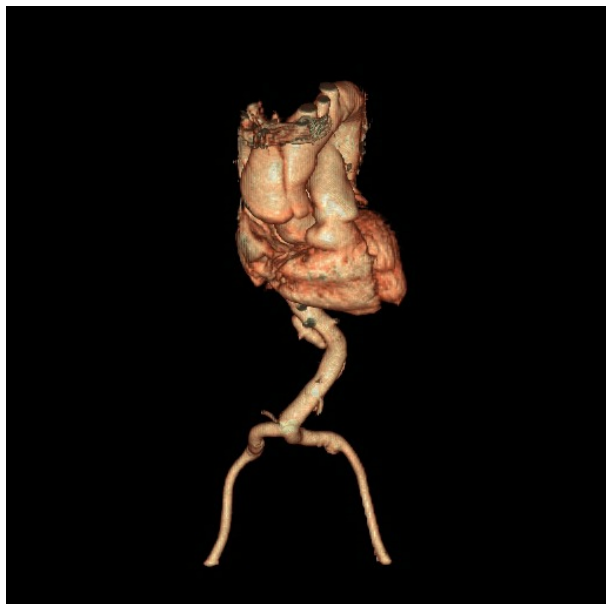


Figure 1: Saccular aneurysm of the ascending aorta as seen from computed tomography reconstruction

The surgery was carried out via a primary median sternotomy with aorto-atrial cannulation for the extracorporeal circulation under general moderate hypothermia. Intraoperatively, there was a 3.5 cm entry point at the antero-medial segment of the aortic wall with thrombus within the false lumen. The entry point was located 3 cm from the sino-tubular junction which appeared to be partially transected while the exit point just 1 cm distal from the entry point also at the anterior part of the ascending aorta (Figure 2).

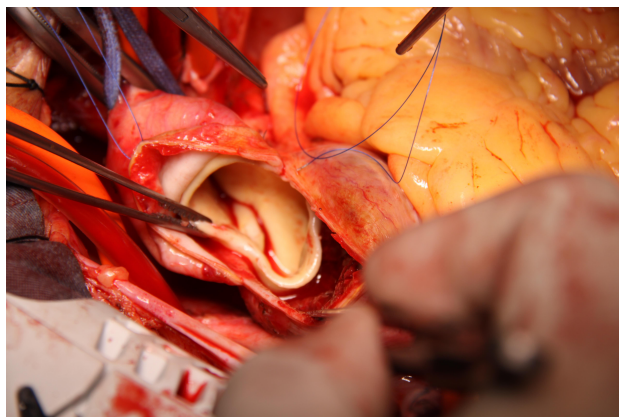


Figure 2: Intraoperative findings revealed a longitudinal intimal tear without a mobile intimal flap and dissection 3.5 cm in length in the anterior wall of the ascending aorta wall a mimicking saccular aneurysm 2 cm in diameter in the center of the intimal tear.

In view of non-valvular and coronaries involvement, the thrombus was removed and an inlay unigraft size 28 mm graft was anastomosed within the true lumen and false lumen was strengthened by tissue adhesive (Figure 3). The composite graft was placed securely with 4-0 pledgetted Prolene sutures which were reinforced with coseal glue (Figure 4). Graft replacement is used after considering the tear size and aortic wall fragility. The wall was repaired overlying the graft with excellent flow. Post operatively, the patient recovered tremendously and discharged home well after a week.

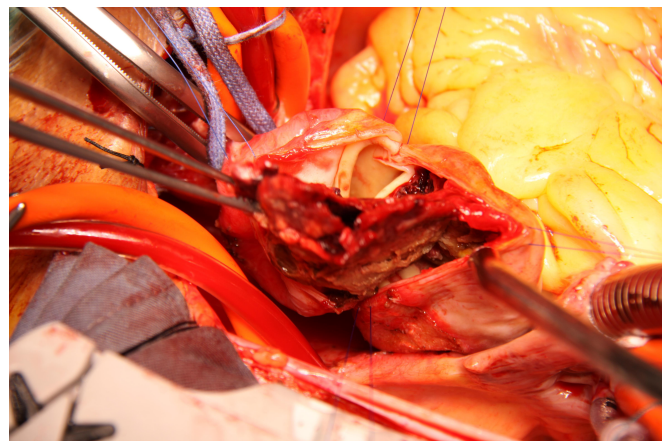


Figure 3: Thrombus within the false lumen between the intima media and adventitia.

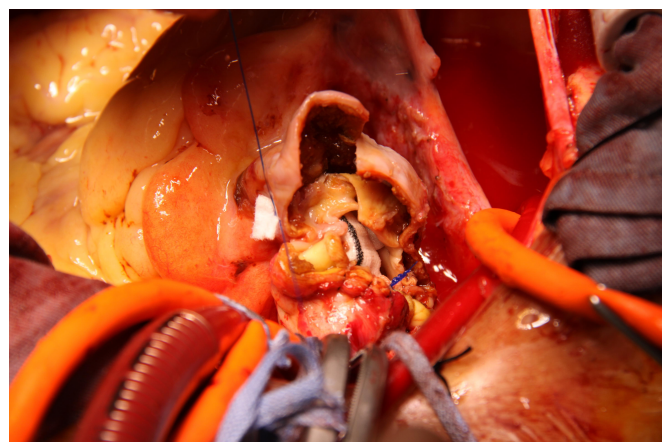


Figure 4: Composite inlay graft 4-0 pledgetted prolene sutures which were reinforced with coseal glue.

She showed tremendous response in the postoperative period. She was on regular 3-6 monthly follow up to monitor for postoperative morbidities and recurrent symptoms. Postoperative CT after 6 months showed no evidence of dissection or leakage. She is now pain-free and having a good quality of life after 1 year of surgery.

DISCUSSION

Aortic dissection is the most common life-threatening emergency affecting the aorta. Atherosclerosis is the leading aetiology of AD and aneurysm formation. It can lead to gross intimal thickening due to massive fibrosis, calcification, and increased accumulation of extracellular fatty acids. The integrity of this layer is further compromised by degradation of extracellular matrix from histiocytic cells. Additional degenerative changes can also happen within the fibrous tissue. Both mechanisms can lead to intimal tear. All these cellular changes can contribute to increased vascular stiffness and vulnerability to shearing tear.

Dissections are usually associated with a history of prolonged hypertension in arteriosclerotic patient. Risk factors namely smoking and hypercholesterolaemia are related to the development of aneurysm and AD. Connective tissue diseases such as Marfan and Ehlers-Danlos syndromes are also associated with AD. Pregnancy especially during the third trimester or during labor is another condition that increases the risk of dissection. Other cause of AD includes direct or indirect trauma particularly after deceleration during motor vehicle accident. Mortality secondary to high speed motor vehicle accidents is related to aortic trauma frequently associated with myocardial contusion in 15-20% of the cases(1).

The diagnosis can be achieved by multiple modalities both non-invasive or invasive technique by taking into consideration of technical aspect, sensitivity, specificity, and the accuracy of the methods. The primary diagnostic modalities used according to the International Registry of Acute Aortic Dissection (IRAD) are transthoracic echocardiography (TTE) and transoesophageal echocardiography (TEE) in 33%(2). Meanwhile, computed tomography (CT) is utilized in 61%, with magnetic resonance imaging and angiography are used in 2% and 4% respectively(2). The demonstration of an intimal flap separating two lumina is essential to diagnose AD. If the false lumen is completely thrombosed, central displacement of the intimal flap, calcification or separation of intimal layers are regarded as pathognomonic for AD. However, TTE and TEE depend on the experience of the operators leading to the primary usage of CT thorax in diagnosis of dissections in our centre. It is reasonably non-invasive compared to the conventional angiography. Predilection to provide transaxial rather than projection images; it can produce remarkable information about overlapping structures. In addition, CT angiography allows alternative diagnoses by displaying thoracic structures which are not vivid at conventional angiography. Nevertheless, the result can be false positive in the presence of calcification on the surface of an intraluminal thrombus in an aneurysm(3).

Stanford classification has categorized AD into type A and type B. Stanford A includes the ascending aorta and Stanford B affects only the descending aorta. Local AD in general is regarded as a cystic medial necrosis with intimal tear or medial hemorrhage causing a localized false lumen in between the intima and adventitia. Intramural hematoma is believed to happen after spontaneous localized hemorrhage into the aortic wall in the absence of AD, intimal tear or penetrating atherosclerotic ulcers(4).

Two key issues need to be addressed in determining the most appropriate repair of the proximal AD. Firstly, the size of aortic root is essential and secondly, the integrity of the aortic valve is paramount. Tubular graft is primarily anastomosed to the sino-tubular ridge if the ascending aorta and aortic root diameters are normal without displacement of the coronary ostia and no commissural detachment of the aortic valve leaflets or other acute or chronic pathological changes of the leaflets. The valve needs to be resuspended prior to graft insertion when single or more commissures are detached.

In order to create a firm and leak proof seat of the ascending aortic graft on the acutely dissected proximal aorta, teflon felt, tissue adhesive such as gelatin resorcinol formaldehyde glue (GRF-glue) or both can be utilized(5). Regardless of any method, importantly the dissected segment of the aorta is first completely divided at the sino-tubular junction level. The layers of aorta traditionally are conjoined by sandwiching them between strips of teflon felt placed inside and outside the dissected perimeter of the vessel. This conventional technique is now gradually replaced by glue reconstruction, in which it has transpired to be time saving and technically easier.

CONCLUSION

In a case of AD, another possible diagnosis should always be considered in view of a different technique would be required for repair intra operatively.

Conflict of interest

No conflict of interest was declared by the authors.

REFERENCES

1. Parmley LF, Mattingly TW, Manion WC, Jahnke EJ Jr. Nonpenetrating traumatic injury of the aorta. *Circulation* 1958; 17: 1086-101
2. Erbel R, Alfonso F, Boileau C, Dirsch O, Eber B, Haverich A, et al. Diagnosis and management of aortic dissection. *Eur Heart J*. 2001; 22: 1642–81
3. Batra P, Bigoni B, Manning J, Aberle DR, Brown K, Hart E, et al. Pitfalls in the diagnosis of thoracic aortic dissection at CT angiography. *Radiographics*. 2000; 20: 309–20
4. Yokoyama H, Ohmi M, Sadahiro M, Shoji Y, Tabayashi K, Moizumi Y. Spontaneous rupture of the thoracic aorta. *Ann Thorac Surg*. 2000; 70: 683–9
5. Bachet J, Gigou F, Laurian C, Bical O, Goudot B, Guilmet D. Four-year clinical experience with the gelatin-resorcine-formol biological glue in acute aortic dissection. *J Thorac Cardiovasc*. 1982; 83: 212–7