

An Unusual Cause of Dysphagia: Hypopharyngeal Rhabdomyoma

Nadir Bir Disfaji Nedeni: Hipofarengeal Rabdomiyom

Mehmet Düzlü¹, Alper Türkcan¹, Metin Yılmaz¹, Recep Karamert¹, Merve Yıldız¹, Caner Ercan²

¹ Department Of Otorhinolaryngology, Gazi University Faculty of Medicine, Ankara, Turkey

² Department Of Pathology, Gazi University Faculty of Medicine, Ankara, Turkey

ABSTRACT

Extra-cardiac rhabdomyomas are rare benign soft tissue tumors accounting for 2% of skeletal muscle neoplasms. Oral cavity and pharynx are the most common sites for rhabdomyomas originating from the head and neck region. The presenting symptom for head and neck rhabdomyomas may change according to tumor size and location. The main treatment modality is total surgical excision. In this study, we aimed to report an adult hypopharyngeal rhabdomyoma case presenting with dysphagia and globus sensation and to discuss head and neck extra-cardiac rhabdomyomas reported in the literature.

Key Words: Extra-cardiac rhabdomyoma, hypopharynx, dysphagia

Received: 02.02.2018

Accepted: 05.01.2018

ÖZET

Ekstra-kardiyak rabdomiyomlar iskelet kası neoplazmalarının %2'sini oluşturan iyi huylu yumuşak doku tümörleridir. Baş boyun bölgesi kaynaklı rabdomiyomlar en çok oral kavite ve farenksten köken alır. Baş boyun rabdomiyomlarında başvuru şikayetleri tümör boyutu ve lokasyonuna göre değişebilir. Temel tedavi yöntemi total cerrahi eksizyondur. Biz bu çalışmada disfaji ve boğazda takılma şikayeti ile başvuran erişkin bir hipofarenks rabdomiyomu olgusunu sunmayı ve baş boyun bölgesi kaynaklı ekstra-kardiyak rabdomiyomları tartışmayı planladık.

Anahtar Sözcükler: Ekstra-kardiyak rabdomiyom, hipofarenks, disfaji

Geliş Tarihi: 02.02.2018

Kabul Tarihi: 01.05.2018

INTRODUCTION

Rhabdomyomas are benign soft tissue tumors of striated muscle most commonly originating from myocardial muscle (1). Extra-cardiac manifestation is extremely rare. Head and neck region is the most common site for extra-cardiac rhabdomyomas. Rhabdomyomas are also classified as being adult or pediatric type. There is not any evidence for malignant transformation of rhabdomyomas (2). The main treatment modality for head and neck rhabdomyomas is total surgical excision (3). In this study, we aimed to report an adult hypopharyngeal rhabdomyoma case presenting with dysphagia and to discuss head and neck extra-cardiac rhabdomyomas reported in the literature.

CASE REPORT

Forty-five years old adult male presented to our clinic with the complaint of difficulty in swallowing. He was also suffering globus sensation in the throat. Medical history revealed a 5-kg weight loss (62kg to 57kg) in the last three months. There wasn't any symptom or sign of dyspnea and hoarseness as well as neck lump. A thorough otorhinolaryngologic examination was performed. Fiber-optic laryngoscopy revealed an asymmetric swelling on the posterior and left lateral pharyngeal wall. The sub-mucosal mass was minimally obstructing the airway and digestive tract (Figure1).

Address for Correspondence / Yazışma Adresi: Mehmet Düzlü, MD Department of Otorhinolaryngology, Gazi University Faculty of Medicine, Ankara, Turkey E-mail: mehmetduzlu@gmail.com

©Telif Hakkı 2018 Gazi Üniversitesi Tıp Fakültesi - Makale metnine <http://medicaljournal.gazi.edu.tr/> web adresinden ulaşılabilir.

©Copyright 2018 by Gazi University Medical Faculty - Available on-line at web site <http://medicaljournal.gazi.edu.tr/>

doi:<http://dx.doi.org/10.12996/gmj.2018.68>

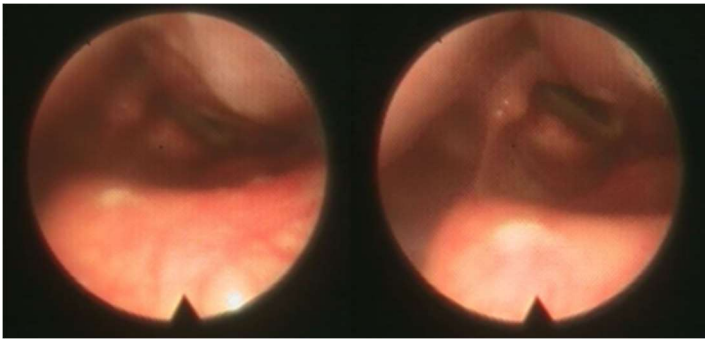


Figure 1. Left sided sub-mucosal mass located at hypopharynx partially obstructing the airway and digestive tract.

There was no sign of cranial nerve deficit. Laboratory examination including common blood count (CBC) were all found to be in normal limits. After that, magnetic resonance imaging (MRI) was performed. There was a 33*52*22 mm well-circumscribed, sub-mucosal mass on posterior pharyngeal wall extending to the left aryepiglottic fold anteriorly and parapharyngeal space superiorly, occluding the left pyriform sinus (Figure 2).

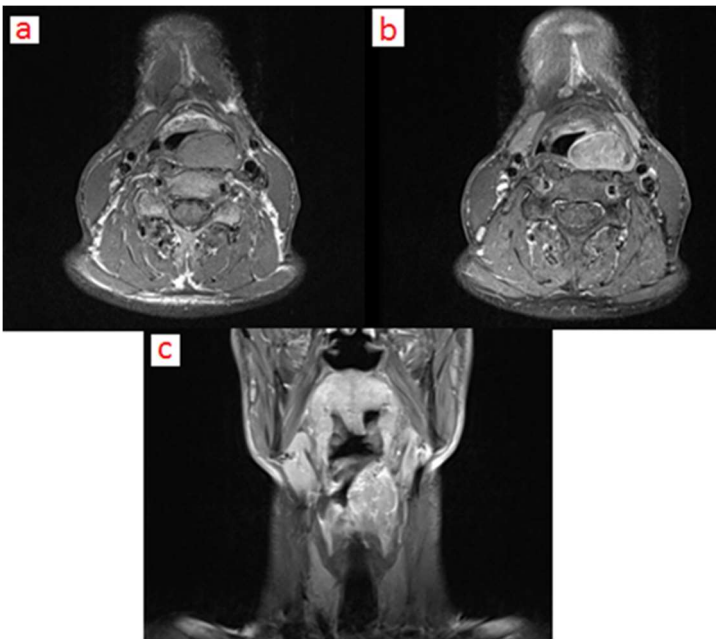


Figure 2. Extra-cardiac rhabdomyoma located at left hypopharynx extending into parapharyngeal space superiorly a. T1 weighted axial MRI scan b.T1 weighted axial scan with contrast c.T2 weighted coronal scan.

Subsequently an incisional biopsy via suspension laryngoscopy was performed under general anesthesia. The pathology result was compatible with adult type extra-cardiac rhabdomyoma. Immunohistochemical analysis was positive for desmin and actin and negative for S-100 (Figure 3).

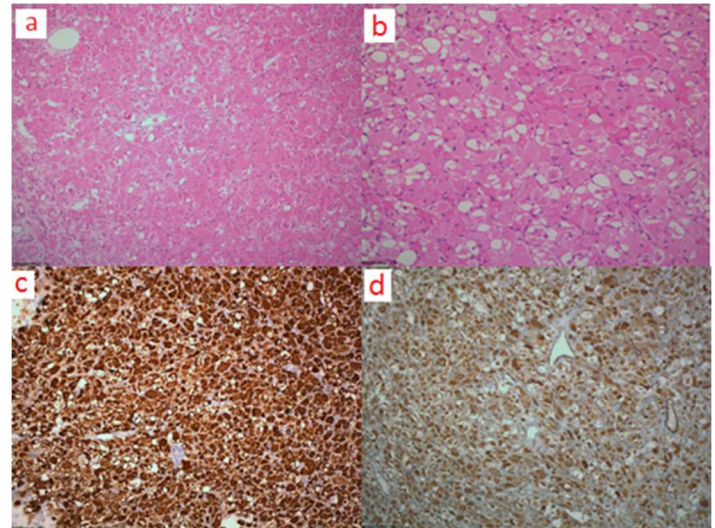


Figure 3. Histopathology: a. Tumor area in eosinophilic and rhabdoid morphology composed of polygonal and variable size cells (H&E x100). b. Tumor cells including peripherally located nucleus and prominent nucleoli are surrounded with thin capillary network. There are also vacuolated cells (H&E x200). Immunohistochemical analysis: Desmin (c) and actin (d) positivity (x100).

Under general anesthesia the hypopharyngeal mass located anterior to the carotid sheath was identified via trans-cervical incision. The superior laryngeal nerve was crossing on the mass. Multilobulated mass was completely excised while preserving superior laryngeal nerve (Figure 4).

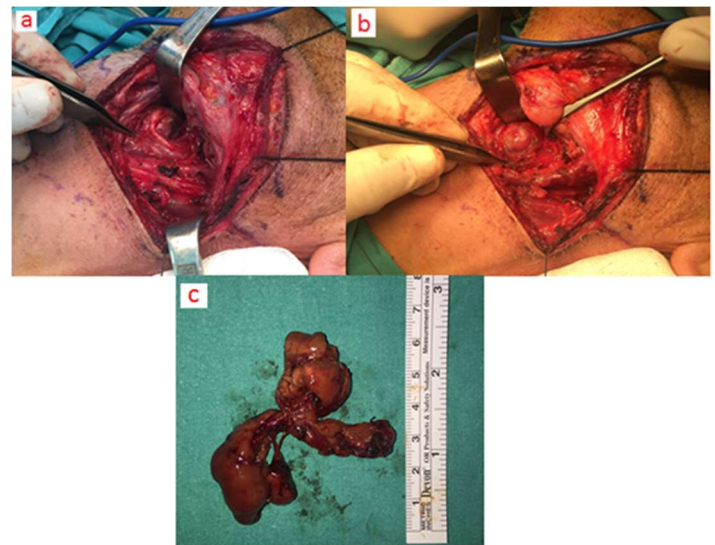


Figure 4.a. Superior laryngeal nerve crossing the mass b. Rhabdomyoma is carefully dissected from surrounding structures c. Multilobulated surgical material.

A 1.5 cm defect occurred on hypopharyngeal wall (possibly the previous incisional biopsy field) at the end of dissection. The defect was sutured primarily. There was no perioperative or postoperative complication. After four days following the surgery, the nasogastric tube was removed and oral intake was initiated. The final histopathological examination revealed extra-cardiac rhabdomyoma, consistent with previous biopsy result. In the 10 months' follow-up, there wasn't any sign of residual or recurrent disease on physical examination or imaging. The patient also regained his original weight.

DISCUSSION

Extra-cardiac rhabdomyomas are rare tumors accounting for 2% of skeletal muscle neoplasms (4). Oral cavity and pharynx are the most common sites for rhabdomyomas located in the head and neck region (5). Pharyngeal rhabdomyomas are supposed to originate from the striated muscles of third or fourth branchial arches. However, the exact etiopathogenetic mechanism is unknown (6). For head and neck rhabdomyomas the median age at presentation is reported to be 60 years with a male predominance of 3:1 ratio (7). Likewise, our case presented here was a 45 years old adult male. The disease may present with obstruction of the airway and dysphagia as well as neck mass (8). In our case the main complaint was dysphagia and weight loss. He was also suffering globus pharyngeus.

According to tumor location; granular cell myoblastoma, rhabdomyosarcoma, minor salivary gland tumor and paraganglioma must be considered in the differential diagnosis for head and neck rhabdomyomas, (9). CT or MRI may be considered for imaging. On MRI scan the mass appears isointense on T1 sequences, and hyperintense on T2 weighted and fat-suppressed sequences. In addition, the rhabdomyoma shows diffuse contrast enhancement (10-11).

On histopathologic examination; the tumor cells contain peripherally located nucleus, vacuoles and prominent nucleoli surrounded with eosinophilic and glycogen rich cytoplasm in rhabdomyomas (7,12). The adult type extra-cardiac rhabdomyomas contain less organized myofibrils compared to fetal type (13). Immunohistochemical analysis must be performed. As like skeletal muscle, extra-cardiac rhabdomyoma shows positivity for desmin and actin protein.

To our knowledge, this is the third extra-cardiac rhabdomyoma case in the literature presenting with dysphagia. Pichi and colleagues reported a parapharyngeal rhabdomyoma presenting with dysphagia and oropharyngeal bulky lesion (9). Grosheva et al. also reported a case of head and neck rhabdomyoma presenting with dysphagia and neck mass (14). In our case, the tumor was located in the left hypopharynx and there was not apparent airway obstruction or neck mass. The only presenting symptom was dysphagia and globus sensation. Therefore, it would be easily misdiagnosed unless laryngoscopic examination was performed.

Malignant transformation is not reported for head and neck rhabdomyomas. Therefore, total surgical excision is adequate for the treatment. Incomplete resection may result in recurrences. Recurrences are reported to be as high as 42% and may be diagnosed even after 11 years (7,15). Total surgical excision was achieved in our case. There isn't any sign of recurrence in the sixth months' follow-up period.

CONCLUSION

Extra-cardiac rhabdomyomas must be considered in the differential diagnosis of any sub-mucosal pharyngeal mass. The presenting symptom may change according to tumor size and location. It may even present with dysphagia as reported in this paper.

The main treatment modality is total surgical excision. However, the patients should be followed long term for any possible recurrence.

Conflict of interest

No conflict of interest was declared by the authors.

REFERENCES

1. Burke AP, Virmani R Cardiac rhabdomyoma: a clinicopathologic study. *Mod Pathol.* 1991;4 :70–4.
2. Vermeersch H, van Vugt P, Lemmerling M, Moerman M, De Potter C. Bilateral recurrent adult rhabdomyomas of the pharyngeal wall. *Eur Arch Otorhinolaryngol.* 2000;257:24-6.
3. Metheetrairut C, Brown DH, Cullen JB, Dardick I. Pharyngeal rhabdomyoma: a clinico-pathological study. *J Otolaryngol.* 1992; 21 :257–61.
4. Sanchez Jimenez J, Dean Ferrer A, Alamillos Granados F, et al. Adult rhabdomyoma in the masticatory area. New case presentation and review of the literature. *Med Oral* 2001;6:64–8.
5. Favia G, Lo Muzio L, Serpico R, Maiorano E Rhabdomyoma of the head and neck: clinicopathologic features of two cases. *Head Neck.* 2003;25:700-4.
6. Stringer SP, Close LG, Cohen DJ, Merkel MA, Smith HJ. Adult parapharyngeal extracardiac rhabdomyoma. *Otolaryngol Head Neck Surg* 1988; 10 :422–6.
7. Kapadia SB, Ellis GL, Frisman DM, Heffner DK, Hyams VJ, Meis JM. Adult rhabdomyoma of the head and neck: a clinicopathologic and immunophenotypic study. *Hum Pathol* 1993; 24 :608–17.
8. Stringer SP, Close LG, Merkel MA, Smith HJ, Cohen DJ. Adult parapharyngeal extracardiac rhabdomyoma. *Otolaryngol Head Neck Surg* 1988;10:422–6.
9. Pichi B, Manciocco V, Marchesi P, Pellini R, Ruscito P, Vidiri A, Covello R, Spriano G. Rhabdomyoma of the parapharyngeal space presenting with dysphagia. *Dysphagia.* 2008;23:202-4.
10. Koutsimpelas D, Weber A, Lippert BM, Mann WJ. Multifocal adult rhabdomyoma of the head and neck: a case report and literature review. *Auris Nasus Larynx.* 2008;35:313-7.
11. Liang GS, Loevner LA, Kumar P. Laryngeal rhabdomyoma involving the paraglottic space. *Am J Rad* 1999;174:1285 -7.
12. Metheetrairut C, Brown DH, Cullen JB, Dardick I (1992) Pharyngeal rhabdomyoma: a clinico-pathological study. *J Otolaryngol* 21 :257–61.
13. Rooks JJ Jr, Cassisi NJ, Alexander RW, Smith RO. Rhabdomyoma of the pharyngeal wall. *Laryngoscope.* 1977;87:1046-51.
14. Grosheva M, Gerharz M, Bovenschulte H, Beutner D. Adult multilobular rhabdomyoma as a rare cause of dysphagia. *Laryngorhinootologie.* 2008;87:651-3.
15. Andersen CB, Elling F. Adult rhabdomyoma of the oropharynx recurring three times within 35 years. *Acta Pathol Microbiol Immunol Scand [A]* 1986;94:281–3.