

## Postpartum Acute Appendicitis

### Doğum Sonrası Akut Apendisit

Nuri Peker<sup>1</sup>, Göksel Seçkin<sup>2</sup>, Turgut İpek<sup>2</sup>

<sup>1</sup> İstinye University Liv Hospital, Department of Obstetrics and Gynecology, Istanbul, Turkey

<sup>2</sup> İstinye University Liv Hospital, Department of General Surgery, Istanbul, Turkey

#### ABSTRACT

A 28-year-old woman, gravida 1 para 1, presented to the obstetrics department with pelvic pain and intermittent fever. Body temperature was 38.9°C. Widespread abdominal sensitivity and rebound were observed on physical examination. C-Reactive Protein was elevated to 31.1 mg/dl and White Blood Cell count remained at 11,000/mm<sup>3</sup>. The diameter of the appendix was measured as about 8.1 cm on Computed Tomography. Diagnostic laparoscopy was performed and appendectomy was done because of acute appendicitis. Postpartum appendicitis is a very rare condition and only a few cases have been reported in the literature however acute appendicitis has to be kept in mind in the differential diagnosis.

**Key Words:** Appendicitis, postpartum morbidity, fever

**Received:** 12.06.2017

**Accepted:** 07.03.2018

#### ÖZET

28 yaşında, gravida 1 para 1, kadın, pelvik ağrı ve aralıklı ateş ile obstetrik bölümüne başvurdu. Vücut ısısı 38.9 ° C idi. Fizik muayenede yaygın abdominal duyarlılık ve rebound gözlemlendi. C-Reaktif Protein 31.1 mg / dl'ye yükselmiş ve beyaz kan hücre sayısı 11,000 / mm<sup>3</sup> olarak saptandı. Apendiksin çapı bilgisayarlı tomografide yaklaşık 8.1 cm olarak ölçüldü. Tanı amaçlı laparoskopi yapıldı ve akut apandisit nedeniyle apendektomi yapıldı. Postpartum apandisit çok nadir görülen bir durumdur ve literatürde sadece birkaç olgu bildirilmiştir, ancak ayırıcı tanıda akut apandisit akılda tutulmalıdır.

**Anahtar Sözcükler:** Apendisit, doğum sonrası morbidite, ateş

**Geliş Tarihi:** 06.12.2017

**Kabul Tarihi:** 03.07.2018

#### INTRODUCTION

Postpartum morbidity is commonly assumed to be associated with pregnancy or delivery; however, non-urogynecologic factors such as acute appendicitis are also a possible cause. Endometritis, wound site infection and urinary tract infection are common causes of postpartum morbidity however acute appendicitis has to be kept in mind in the differential diagnosis. (1,2)

We presented a case report with the diagnosis of acute appendicitis at the postpartum 7<sup>th</sup> day.

#### CASE REPORT

A 28-year-old woman, gravida 1 para 1, presented to the obstetrics department with pelvic pain and intermittent fever. She had a history of cesarean section 3 days earlier with the indication of prolonged labor and fetal distress at 41 weeks gestation. At presentation, the patient's body temperature was 38.5°C and she had abdominal pain. On physical examination, the cesarean incision was clean with no signs of wound site infection.

**Address for Correspondence / Yazışma Adresi:** Nuri Peker, MD İstinye University Liv Hospital, Department of Obstetrics and Gynecology, Istanbul, Turkey  
dr.ata1980@hotmail.com

©Telif Hakkı 2018 Gazi Üniversitesi Tıp Fakültesi - Makale metnine <http://medicaljournal.gazi.edu.tr/> web adresinden ulaşılabilir.

©Copyright 2018 by Gazi University Medical Faculty - Available on-line at web site <http://medicaljournal.gazi.edu.tr/>

doi:<http://dx.doi.org/10.12996/gmj.2018.94>

Ultrasound examination showed that the uterus size was consistent with the postpartum period and the ovaries were normal. The breasts were normal, with no engorgement or mastitis. Laboratory findings included C-reactive protein (CRP) level of 3.1 mg/dl and white blood cell (WBC) count of 11,000/mm<sup>3</sup>; urinalysis revealed a moderate urinary infection. A third-generation cephalosporin and an antipyretic were prescribed. At follow-up on postpartum day 7, the patient reported that the fever episodes had continued and her abdominal pain had worsened. The patient was hospitalized to determine the cause of the fever and the abdominal pain. At the time of admission, her body temperature was 38.9°C. Widespread abdominal sensitivity and rebound were observed on physical examination. CRP level, WBC count, liver function test, and serum amylase, lipase, urea, and creatinine levels were assessed. CRP was elevated to 31.1 mg/dl and WBC count remained at 11,000/mm<sup>3</sup>. Amylase and lipase levels were normal. Ultrasound examination of the abdomen and urinary tract was normal; however, the appendix could not be clearly distinguished due to severe gas distention. Therefore, contrast-enhanced computed tomography (CT) was performed to rule out any acute bowel pathology. The diameter of the appendix was measured as about 8.1 cm on CT (Figure 1). The uterus was 15 cm with minimal fluid in the endometrial cavity and the ovaries showed normal shape and size. After evaluating the clinical, laboratory, and radiological findings together, diagnostic laparoscopy was planned.

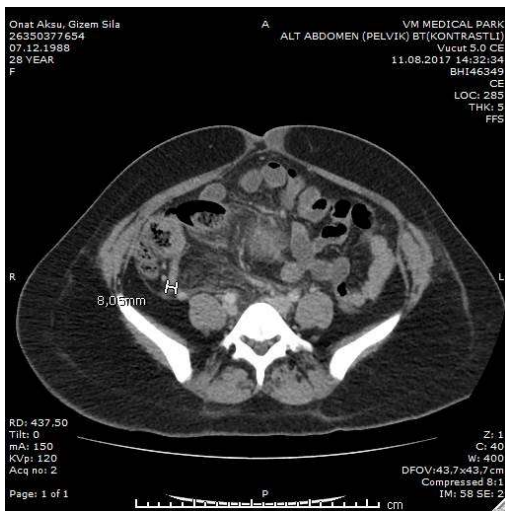


Figure 1. 8.1 millimeter enlarged appendix

Intraoperatively, the appendix was erect, edematous, and enlarged. The uterus and the ovaries were normal. Appendectomy was performed ([supplementary video](#)). Pathological examination confirmed acute appendicitis. Postoperatively, the fever and abdominal pain resolved immediately and CRP level declined sharply, becoming negative by postoperative day 7. The patient was discharged at postoperative day 2 with an antibiotic regimen.

## DISCUSSION

The differential diagnosis for patients with postpartum abdominal pain and fever should include endometritis, surgical site infection, urinary tract infection, septic pelvic thrombophlebitis, and non-gynecologic factors (1,2). However, fever and abdominal pain generally suggest endometritis, which is more common after cesarean delivery and presents with fever, uterine tenderness, foul lochia, and elevated leukocytosis and CRP (2). Surgical site infection is also common after cesarean delivery, generally occurring four to seven days after surgery and presenting with fever and abdominal pain. In addition, urinary tract infection is another common cause of postpartum fever and pain (1,2, 3, 4).

Postpartum appendicitis is a very rare condition and only a few cases have been reported in the literature (5). The pathogenesis is not clear. The typical presentation of acute appendicitis is abdominal pain that initially starts periumbilical and then migrates to the right lower quadrant as the inflammatory process progresses. Fever and leukocytosis may develop later (5,6). However, acute appendicitis is a histological diagnosis and should be strengthened with laboratory and radiologic examinations. Ultrasonography, magnetic resonance imaging, and CT are preferred imaging modalities (5,6,7).

In our case, the main complaints at presentation were abdominal pain and fever. The patient's symptoms did not include nausea or vomiting. Although she did not have abdominal tenderness or rebound at initial admission, these signs appeared in follow-up evaluation 3 days later. The enlarged appendix on CT supported our diagnosis of acute appendicitis and we planned diagnostic laparoscopy.

## CONCLUSION

Although acute appendicitis is a very rare cause of postpartum morbidity, it should be considered in the differential diagnosis of abdominal pain and fever.

## Conflict of interest

No conflict of interest was declared by the authors.

## REFERENCES

1. Andersen B, Nielsen TF. Appendicitis in pregnancy: diagnosis, management and complications. *Acta Obstet Gynecol Scand.* 1999; 78: 758-62.
2. Deneux-Tharoux C, Carmona E, Bouvier-Colle MH et al. Postpartum maternal mortality and cesarean delivery. *Obstet Gynecol.* 2006; 108: 541-8.
3. Kawakita T, Landy HJ. Surgical site infections after cesarean delivery: epidemiology, prevention and treatment. *Matern Health Neonatol Perinatol.* 2017 5;3:12.
4. Kazim SF, Pal KM. Appendicitis in pregnancy: experience of thirty-eight patients diagnosed and managed at a tertiary care hospital in Karachi. *Int J Surg.* 2009; 7: 365-7.
5. Wadhawan D, Singhal S, Sarda N, et al. Appendicitis in Postpartum Period: A Diagnostic Challenge. *J Clin Diagn Res.* 2015; 9: QD10-1.
6. Kulhan M, Kulhan NG, Nayki U, et al. Outcomes of the patients diagnosed incidentally appendicitis during cesarean section. *Ginekol Pol.* 2017; 88:147-50.
7. Richards C, Daya S. Diagnosis of acute appendicitis in pregnancy. *Can J Surg.* 1989; 32: 358-60.