

Calcaneal Plating for Intraarticular Calcaneal Fractures: Mid-Term Clinical and Radiographic Outcomes

Eklem İçi Kalkaneus Kırıklarında Plak Tespiti: Orta Dönem Klinik ve Radyolojik Sonuçlar

Zeynel Mert Asfuroğlu¹, Ulukan İnan²

¹ Mersin University, Faculty of Medicine, Department of Orthopaedics and Traumatology, Division of Hand Surgery, Mersin, Turkey

² Eskisehir Osmangazi University, Faculty of Medicine, Department of Orthopaedics and Traumatology, Eskisehir, Turkey

ABSTRACT

Objective: To evaluate the clinical and radiographic outcomes and wound complications of patients with closed calcaneal fractures undergoing open reduction and internal fixation with conventional extended lateral approach.

Methods: The study included 35 closed calcaneal fractures of 32 consecutive patients (28 male, 4 female) undergoing open reduction and plate fixation in our department between 2007 and 2013. All patients were operated using the extended lateral incision. All patients were examined using direct radiography and computed tomography. Böhler's angle and Sanders classification were recorded. The American Orthopedic Foot and Ankle Society (AOFAS) scoring system was used for the clinical functional assessments.

Results: AOFAS score was significantly and positively correlated with the preoperative Böhler's angle ($r=0.667$, $p<0.001$) and significantly and negatively correlated with the Sanders classification type ($r=-0.765$, $p<0.001$). The wound site problem was observed only in 2 patients (one had superficial wound site infection and the other developed skin necrosis), for whom good results were achieved after appropriate treatments.

Conclusion: The open reduction internal fixation technique with lateral incision provided postoperative satisfactory results clinically and radiologically for intraarticular calcaneal fractures. If sufficient time is waited preoperatively for soft tissue recovery, wound site complications can be avoided in open surgery.

Key Words: Calcaneus, open-reduction and plate fixation, extended lateral approach

Received: 06.13.2017

Accepted: 03.12.2018

ÖZET

Amaç: Geleneksel uzatılmış lateral yaklaşım ile açık redüksiyon ve internal tespit yapılan kapalı kalkaneus kırıklı hastaların klinik ve radyolojik sonuçları ile yara yeri komplikasyonlarının değerlendirilmesi.

Yöntem: 2007-2013 yılları arasında açık redüksiyon ve plak fiksasyonu yapılan 32 hastanın (28 erkek, 4 kadın) 35 kapalı kalkaneus kırığı çalışmaya dahil edildi. Tüm hastalarda uzatılmış lateral yaklaşım kullanıldı. Tüm hastalar ameliyat öncesi direkt radyografi ve bilgisayarlı tomografi ile tetkik edildi. Böhler açısı ve Sanders sınıflaması kayıt altına alındı. Klinik değerlendirme için The American Orthopedic Foot and Ankle Society (AOFAS) skorlama sistemi kullanıldı.

Bulgular: AOFAS skorunun anlamlı olarak Böhler açısı ile negatif ($r=0.667$, $p<0.001$), Sanders sınıflaması tipi ile pozitif ($r=-0.765$, $p<0.001$) korelasyon gösterdiği tespit edildi. Yara yeri sorunu sadece 2 hastada (1 yüzeysel enfeksiyon, 1 cilt nekrozu) görüldü ve uygun tedavi yaklaşımı ile bu iki hastada iyi sonuç elde edildi.

Sonuç: Eklem içi kalkaneus kırıklarında lateral yaklaşım ile açık redüksiyon ve internal tespit, ameliyat sonrası tatmin edici klinik ve radyolojik sonuçlar sağlamaktadır. Ameliyat öncesi yumuşak doku iyileşmesi için yeterli süre beklenirse açık cerrahi sonrasında görülebilecek yara yeri sorunlarından korunabilmektedir.

Anahtar Sözcükler: Kalkaneus, açık redüksiyon ve plak fiksasyonu, uzatılmış lateral yaklaşım

Geliş Tarihi: 13.06.2017

Kabul Tarihi: 12.03.2018

INTRODUCTION

Calcaneal fractures are the most common tarsal bone fractures and have commonly been considered problematic in terms of clinical outcomes (1, 2). The choice of treatment for displaced intraarticular calcaneal fractures is still debatable (3, 4). Surgical treatment has commonly been preferred in displaced calcaneal fractures for the last 20 years. Closed reduction and percutaneous fixation (CRPF) and open reduction and internal fixation (ORIF) are the two main surgical methods. The importance of minimally invasive methods has recently been emphasized due to the wound site problems that can occur after extended lateral approach. Timing of surgery is also important and a careful examination of the surrounding soft tissue status may prevent postoperative wound problems (5, 6).

The aim of the present study was to assess the clinical and radiographic outcomes and the rate of wound complications in patients with closed calcaneal fractures who underwent open reduction and plate fixation with conventional extended lateral approach.

METHODS

The present study included 35 closed calcaneal fractures of 32 consecutive patients who underwent open reduction and plate fixation at the Orthopedics and Traumatology Department of Medical Faculty of Eskisehir Osmangazi University between 2007 and 2013. A bilateral fracture was present in 3 patients and bilateral fractures of each case were operated on at the same session. Immediate preoperative ice, elevation, and rest by a splint protocol were applied for all patients. The patients with bullae detected on the lateral side were applied wet-to-dry dressing and monitored. Soft tissue swellings of the patients were monitored two or three times a day.

Preoperatively, anteroposterior, lateral, and axial radiographies including the ankle and foot were obtained for all patients. Computerized tomographic examination was also performed in all patients. The preoperative soft tissue status of the patients was determined by evaluating the patient for the "wrinkle sign"; those with skin wrinkle lateral to the ankle with the dorsiflexion and eversion of the ankle were considered eligible for surgery.

All operations were performed in the lateral decubitus position and under pneumatic tourniquet. The extended lateral approach was used in all patients. First, the reduction of the lateral wall was performed. If there was a collapsed posterior facet, the facet was elevated. After elevating the posterior facet, the bone defect was evaluated.

Bone grafting was performed using allograft in 26 patients. Finally, the reduction of the calcaneocuboid joint was performed. Temporary K-wires were used for maintaining all reductions. After fluoroscopic confirmation of the reduction, a permanent fixation was performed using pre-shaped anatomical locking plates according to the lateral wall. After the plate fixation, the temporary K-wires were removed. In all patients, a hemovac drain was used for 48 hours and a short leg splint was applied for 4 weeks. The patients were allowed to walk using crutches without weight bearing the day after the surgery. Partial weight bearing was allowed at the 6th postoperative week. Full weight bearing was allowed at the 12-18 weeks following the surgery.

Böhler's angle was used for the radiographic evaluation (7). Classification of the fractures was performed using Sanders classification system (8). The clinical functional assessments of the patients were performed using the American Orthopedic Foot and Ankle Society (AOFAS) scoring system (9).

Statistical Analysis

Data analysis was performed using the IBM SPSS Statistics for Windows, version 22.0 (IBM Corp., Armonk, NY, USA) and PAST program. The normality of univariate data was tested using the Kolmogorov-Smirnov test and Shapiro-Wilk test and the normality of multivariate data was tested using the Mardia's (Doornik-Hansen omnibus) test. Leneve's test was used to assess homogeneity of variance. Parametric methods were used for variables with normal distribution and homogeneity of variance, whereas non-parametric methods were used for variables without homogeneity of variance or with non-normal distribution. Two repetitive measurements of dependent variables were evaluated by the paired samples t-test. Spearman's rho test was used to determine the correlations between the variables. Quantitative data were expressed as mean±standard deviation, median, and range (minimum-maximum) and categorical variables were expressed as number and percentage. A p value of <0.05 was considered statistically significant.

RESULTS

The study included 35 closed calcaneal fractures of 32 patients. The mean age of these patients was 45.4±15.0 years (range, 19-77 years); of them, 28 (87.5%) were male and 4 (12.5%) were female. Twelve patients had associated fractures; 6 (18%) patients had lumbar vertebral fracture, 3 (9%) patients had distal radius fracture, 2 (6%) patients had pelvic fracture, and 1 (3%) had medial malleolus fracture. The causes of fractures were fall from a height in 18 (56%) patients and traffic accident in 14 (44%) patients. General characteristics of the study patients are presented in Table 1.

There was a significant difference between the mean preoperative and postoperative Böhler's angle values (p<0.001). (Figure 1). The mean AOFAS score was 80.2±14.6. According to the AOFAS scoring system, the outcomes were excellent in 20 (57.1%) calcanei, good in 7 (20%) calcanei, fair in 2 (5.7%) calcanei, and poor in 6 (17.1%) calcanei.

Table 1: General characteristics of the study patients

Characteristics	
Age, year	45.4±15.0 46 (19-77)
Gender	
Female	4 (12.5)
Male	28 (87.5)
Causes of fractures	
Fall from a height	18 (56.0)
Traffic accidents	14 (44.0)
Fracture side	
Left	16 (45.7)
Right	19 (54.3)
AOFAS Score	82.3±14.6 90 (35-93)
Böhler's Angle, degrees	
Preoperative	-5.6±14.2 -4 (21-[-31])
Postoperative	20.8±10.2 21 (0-38)
Sanders score	2.9±0.8 3 (2-4)
Time elapsed between admission and surgery	5.4±2.6 5 (1-14)
Duration of follow-up, months	34.4±20.1 33 (15-80)

According to Sanders classification, of the fractures, 12 (34.3%) were Type 2 fractures, 13 (37.1%) were Type 3 fractures, and 10 (28.6%) were Type 4 fractures. The mean preoperative Böhler's angle was -5.71±14.2 degrees.

The patients were operated on after a mean duration of 5.4 days (range, 1-14 days) following their admission date. The mean follow-up was 34.4±20.1 months. At the last follow-up, the mean Böhler's angle was 20.8±10.2 degrees.

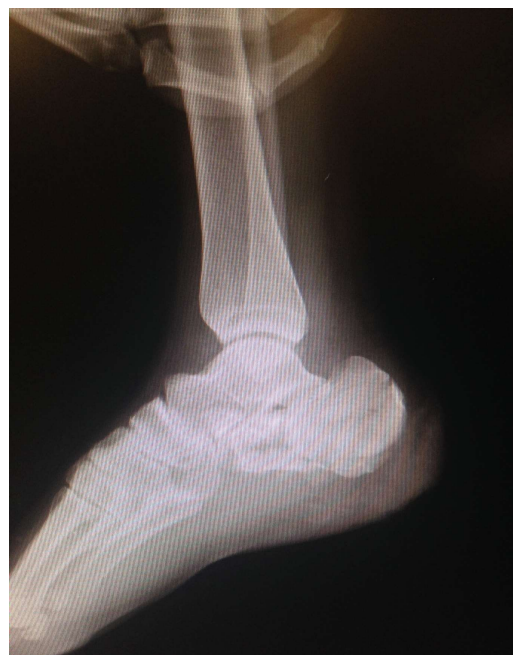

Figure 1A. A 32 year-old male patient with calcaneus fracture due to fall from height. His preoperative lateral radiographic view.

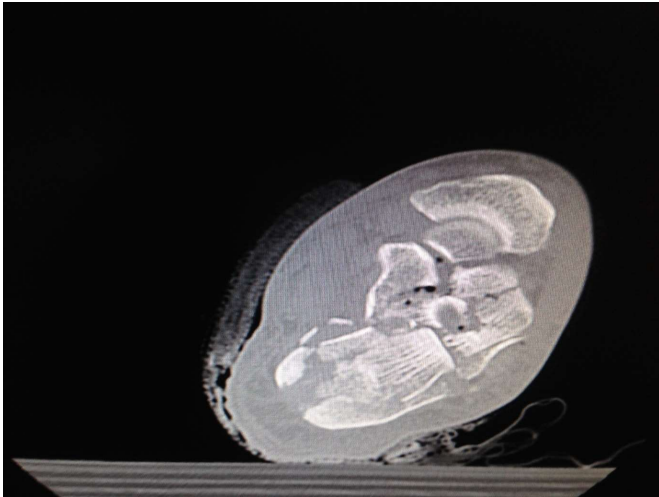


Figure 1B. Computed tomography view.

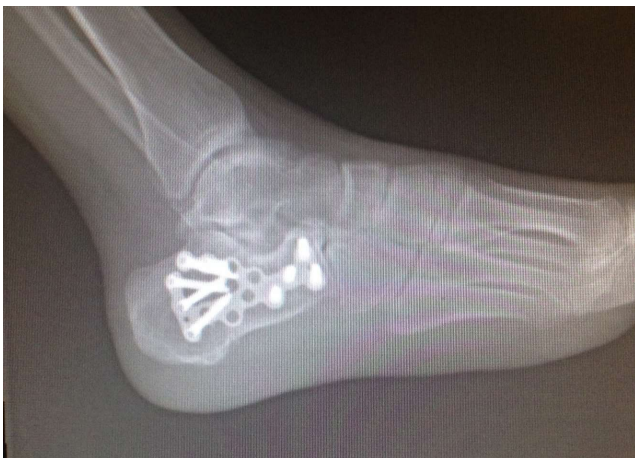

Figure 1C. Lateral radiographic view at the postoperative 23rd month.

The correlation analysis revealed that AOFAS score was found to be significantly and positively correlated with the preoperative Böhler's angle and significantly and negatively correlated with the Sanders classification type

Table 2. Findings of correlation analysis

	AOFAS score	
	r	p
Preoperative Böhler's angle	0.667	<0.001
Sanders classification type	-0.765	<0.001
Timing of surgery	0.271	0.115
Age	0.099	0.571

AOFAS, the American Orthopedic Foot and Ankle Society.

None of the patients had arthrodesis. Postoperative complications were observed in 4 patients. Of these 4 patients, only 2 had wound site complications, for whom the Department of Plastic and Reconstructive Surgery was also consulted. One of these patients had superficial wound site infection and treated with an appropriate antibiotherapy without the need for surgery. The other patient developed skin necrosis. In this patient, the necrosis plaques were initially excised; however, since an infection occurred

DISCUSSION

Since wound site complications are common on the skin of the respective region in the calcaneal fractures, there are debates on the use of extended lateral approach for the treatment of these fractures in recent years.

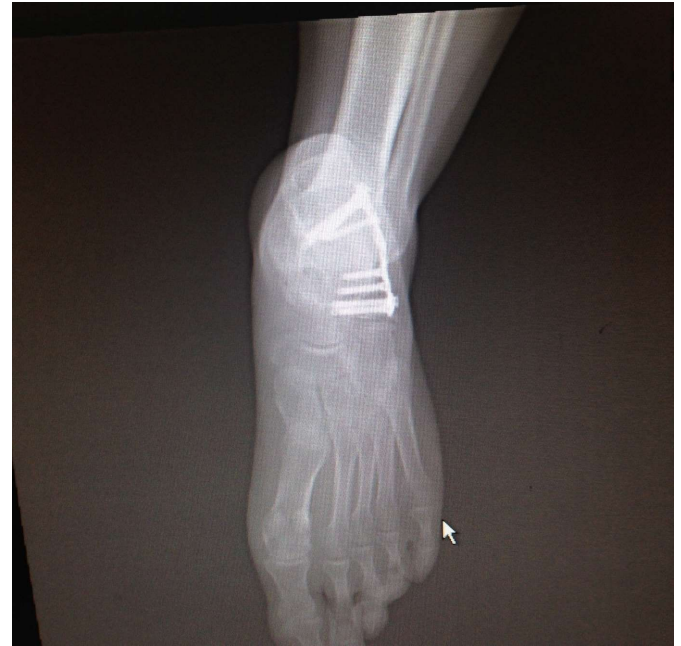

Figure 1D. Anteroposterior radiographic view at the postoperative 23rd month.

($p < 0.001$ for each; Table 2). Moreover, there was also a significant negative correlation between preoperative Böhler's angle and Sanders classification type ($r = -0.771$, $p < 0.001$).

afterwards, the implants of the patient were removed and the wound was covered using a vacuum device.

A complete recovery was observed at the postoperative 12th month. The remaining 2 patients had reflex sympathetic dystrophy that completely healed with a proper physical therapy program and calcium and vitamin D supplementation.

The present study aimed to reveal the functional outcomes of classic extended lateral approach and open surgery and the rate of wound site complications in patients with closed calcaneal fractures.

Calcaneal injuries mostly occur due to high-energy accidents (such as fall from a height, motor vehicle accidents) and severe work accidents and thereby these fractures are usually common in the male population. Similar to those reported in the literature (10-12), in the present study, the most common cause of the calcaneal fractures was fall from a height (56%) and the majority of the patients (87%) were male.

With the advances in technology, computed tomography has been commonly used in recent years for the diagnosis of calcaneal fractures (13). There are several classifications that are based on computed tomography scans (14). In the present study, Sanders classification system was used for classification of the fractures (8). Moreover, there are several assessment systems revealing the functional outcomes related to the ankle and the foot. The most common scales include the Maryland Foot Score, Creighton-Nebraska Foot Score, Foot-Ankle Disability Index, and AOFAS Hindfoot score (9, 15). There is no certain information on which one of these scales is better. In the present study, we used the AOFAS scoring system (9), which is understood by the patients more easily and has a higher level of applicability.

According to Sanders classification system, conservative treatment is recommended for Type 1 fractures, surgery is recommended for Type 2 and Type 3 fractures; however, there is no consensus on Type 4 fractures. The choice of treatment for Type 4 fractures depends on the trauma experience of the surgeon. Previous studies on this issue have reported that the surgical outcomes are unsatisfactory in Sanders Type 4 fractures (16-21). Being one of the most important studies in this regard, the study by Sanders et al. (21), in which 120 displaced intraarticular calcaneal fractures were surgically treated using a lateral approach, lag screws, and side plate without bone graft, demonstrated that none of the Type 4 fractures achieved an anatomic articular reduction and only one of them (1 out of 9 Type 4 fractures) achieved excellent/good outcome. In the present study, the functional outcomes of surgically treated Type 4 fractures (n=10) revealed that the outcome was good in 2 (20%) calcanei, fair in 2 (20%) calcanei, and poor in 6 (60%) calcanei. All of the calcanei with poor outcomes were observed to have Type 4 fractures at the initial admission.

In a multicenter, randomized controlled study, Griffin et al. (22) compared surgical and non-surgical treatments in displaced intraarticular calcaneal fractures and reported no symptomatic or functional difference between surgical and non-surgical treatments. However, they recommended conservative treatment for displaced intraarticular fractures due to the postoperative complication risk.

A meta-analysis study by Jiang et al. (23) reviewed the studies conducted between 1980 and 2011 and compared surgical and conservative treatments of displaced intra-articular calcaneal fracture. They showed that surgical treatment was more effective on the reconstruction of Böhler's angle and associated with greater functional benefits. In the present study, the mean Böhler's angle was significantly increased at the final follow-up as compared with the preoperative value; in other words, Böhler's angles were reconstructed to an acceptable level postoperatively and this contributed to achieve good functional outcomes.

Extended lateral incision is commonly preferred for the ORIF of the calcaneus. In the present study, we also used this incision, in which the peroneal tendons and the calcaneofibular ligament are elevated as flaps and the sural nerve is found and preserved, for all of our patients. This incision enables a clear vision of the fracture lines and the chance of grafonage for the bone defects is provided through the same incision (24, 25). In the present study, locking plates, which have become popular in the recent years, were chosen as the fixation method. Additional incision was not required in any patient included in the present study, which indicated the adequacy of extended lateral incision.

The most intimidating aspect of the extended lateral incision is the high risk of wound site complications. In their multicenter study, Kwon et al. (26) examined the effects of delayed surgery on wound complications in closed intraarticular calcaneal fractures and found the rate of wound site complications to be higher with extended lateral approach, even the surgery was delayed, compared with other minimal techniques; accordingly, the authors recommended minimal invasive methods (26). However, we preferred extended lateral approach as all fracture fragments were more easily accessed and the joint restoration was more easily provided. Regarding the wound site complications, we believe that wound site problems would not be as much as intimidating if aggressive elevation is applied and the formation of wrinkles the lateral to the skin are waited.

A limitation of the present study might be the lack of control group involving a different surgical technique (e.g. minimal invasive surgery) or a conservative treatment. A sufficient group of patients could not be formed since this kind of fractures is typically treated with classic surgical approach at our clinic. Since calcaneal fractures may have long term complications such as osteoarthritis, follow up period shorter than 24 months in some patients might be considered as another limitation for the study.

In conclusion, extended lateral approach provided both an easy access to the fracture site and an anatomic reduction of the fracture. The results of the present study revealed that the type of the fracture and the degree of the Böhler's angle were important factors effective on the prognosis in calcaneal fractures. The poorer the Sanders fracture type is and the lower the Böhler's angle is at the initial admission, the poorer the outcomes will be. Extended lateral approach might produce satisfactory outcomes if not rushed for surgery and waited for the heel swelling to subside in displaced intraarticular calcaneal fractures.

Conflict of interest

No conflict of interest was declared by the authors.

REFERENCES

1. Nork SE, Barai DP. Ankle and hindfoot trauma. In: Fischgrund JS, editor. Orthopaedic knowledge update. Rosemont, IL; American Academy of Orthopaedic Surgeons; 2008.
2. Clare MP, Lee WE, Sanders RW. Intermediate to long-term results of a treatment protocol for calcaneal fracture malunions. *J Bone Joint Surg Am* 2005;87:963-73.
3. Kundel K, Funk E, Brutscher M, Bickel R. Calcaneal fractures: operative versus nonoperative treatment. *J Trauma* 1996;41:839-45.
4. Schepers T, Ginai AZ, Van Lieshout EM, Patka P. Demographics of extra-articular calcaneal fractures: including a review of the literature on treatment and outcome. *Acta Orthop Trauma Surg* 2008;128:1099-106.
5. Swanson SA, Clare MP, Sanders RW. Management of intra-articular fractures of the calcaneus. *Foot Ankle Clin* 2008;13:659-78.
6. Guerado E, Bertrand ML, Cano JR. Management of calcaneal fractures what have we learnt over the years? *Injury* 2012;43:1640-50.
7. Böhler L. Diagnosis, pathology and treatment of fractures of the os calcis. *J Bone Joint Surg Am* 1931;13:75-89.
8. Sanders R. Displaced intra-articular fractures of the calcaneus. *J Bone Joint Surg Am* 2000;82:225-50.
9. Toolan BC, Wright Quinones VJ, Cunningham BJ, Brage ME. An evaluation of the use of retrospectively acquired preoperative AOFAS clinical rating scores to assess surgical outcome after elective foot and ankle surgery. *Foot Ankle Int* 2001;22:775-8.
10. Tornetta P 3rd. Percutaneous treatment of calcaneal fractures. *Clin Orthop Relat Res* 2000;91-6.
11. Eastwood DM, Langkamer VG, Atkins RM. Intra-articular fractures of the calcaneum. Part II: open reduction and internal fixation by the extended lateral transcaneal approach. *J Bone Joint Surg Br* 1993;75:189-95.
12. Paul M, Peter R, Hoffmeyer P. Fractures of the calcaneum. A review of 70 patients. *J Bone Joint Surg Br* 2004;86:1142-5.
13. DiGiovanni CW, Benirschke SK, Hansen ST. Foot injuries. In: Browner BD, Jupiter JB, Levine AM, Trafton PG. *Skeletal Trauma: basic science, management and reconstruction*. WB Saunders: 2003:2375-492.
14. Ibrahim T, Roswell M, Rennie W, Brown AR, Taylor GJ, Gregg PJ. Displaced intra-articular calcaneal fractures: 15-year follow-up of a randomised controlled trial of conservative versus operative treatment. *Injury* 2007;38:848-55.
15. Kitaoka HB, Alexander IJ, Adelaar RS, Nunley JA, Myerson MS, Sanders M. Clinical rating systems for the ankle-hindfoot, midfoot, hallux and lesser toes. *Foot Ankle Int* 1994;15:349-53.
16. Rammelt S, Zwipp H. Calcaneal fractures: facts, controversies and recent developments. *Injury* 2004;35:443-61.
17. Sanders R. Displaced intra-articular fractures of the calcaneus. *J Bone Joint Surg Am* 2000;82:225-50.
18. Clare MP. Calcaneal fractures. In: Pinzur MS, editor. *Orthopaedic Knowledge Update: Foot and Ankle 4*. Rosemont, IL: American Academy of Orthopaedic Surgeons; 2008:75-94.
19. Thordarson DB. Foot and Ankle Trauma. In: Thordarson DB, editor. *Foot and Ankle*. Philadelphia: Lippincott Williams & Wilkins; 2004:288-319.
20. Murphy GA. Fractures and dislocations of foot. In: Canale ST, editor. *Campbell's Operative Orthopaedics*. Vol 4, 10th Edition. Philadelphia: Mosby; 2003:4231-47.
21. Sanders R, Fortin P, DiPasquale T, Walling A. Operative treatment in 120 displaced intraarticular calcaneal fractures. Results using a prognostic computed tomography scan classification. *Clin Orthop Relat Res* 1993;87-95.
22. Griffin D, Parsons N, Shaw E, Kulikov Y, Hutchinson C, Thorogood M, et al. Operative versus non-operative treatment for closed, displaced, intra-articular fractures of the calcaneus: randomised controlled trial. *BMJ* 2014;349:g4483.
23. Jiang N, Lin QR, Diao XC, Wu L, Yu B. Surgical versus nonsurgical treatment of displaced intra-articular calcaneal fracture: a meta-analysis of current evidence base. *Int Orthop* 2012;36:1615-22.
24. Stephenson JR. Treatment of displaced intra-articular fractures of the calcaneus using medial and lateral approaches, internal fixation, and early motion. *J Bone Joint Surg Am* 1987;69:115-30.
25. Stephenson JR. Surgical treatment of displaced intraarticular fractures of the calcaneus. A combined lateral and medial approach. *Clin Orthop Relat Res* 1993;68-75.
26. Kwon JY, Guss D, Lin DE, Abousayed M, Jeng C, Kang S, et al. Effect of Delay to Definitive Surgical Fixation on Wound Complications in the Treatment of Closed, Intra-articular Calcaneus Fractures. *Foot Ankle Int* 2015;36:508-17.