

## Protective Effects of Resveratrol in a Rat Model of Ischemia-Reperfusion Injury of Sciatic Nerve

Rat Siyatik Siniri Iskemi-Reperfüzyon Hasarında Resveratrolün Koruyucu Etkileri

Onur Akarca<sup>1</sup>, Özgür Öcal<sup>1</sup>, Erkut Baha Bulduk<sup>2</sup>, Özge Tuğçe Paşaoğlu<sup>3</sup>, Ayşe Çakır Gündoğdu<sup>4</sup>, Gülnur Take Kaplanoğlu<sup>4</sup>  
Aydın Paşaoğlu<sup>1</sup>

<sup>1</sup>Gazi University, Faculty of Medicine, Department of Neurosurgery, Ankara, Turkey

<sup>2</sup>Eskisehir Government Hospital, Department of Neurosurgery, Eskisehir, Turkey

<sup>3</sup>Gazi University, Faculty of Medicine, Department, of Biochemistry, Ankara, Turkey

<sup>4</sup>Gazi University, Faculty of Medicine, Department of Histology, Ankara, Turkey

### ABSTRACT

**Objective:** The aim of this study was to determine the effects of resveratrol on ischemia- reperfusion (I/R) injury in the rats sciatic nerve.

**Methods:** We used 18 Wistar rats anesthetized with ketamine (50 mg/kg-im). In the sham group, we only performed the surgery and not administer any medication. In the ischemia group, we generated I/R injury in 5 minute intervals with medical treatment of saline only. In the resveratrol group, we brought about the same I/R injury but gave resveratrol before the surgery by per oral. After sacrifice, we studied blood and nerve tissue samples. We evaluated the damage with malondialdehyde (MDA), nitric oxide (NO), and total antioxidant capacity (TAC), both in tissue and blood.

**Results:** Evaluation of serum levels of antioxidant markers and tissue samples demonstrated statistically significant effects of resveratrol in ischemia-reperfusion injury.

**Conclusion:** This study revealed the antioxidant effect of resveratrol as an inhibitor of lipid peroxidation.

**Key Words:** Sciatic nerve, ischemia- reperfusion injury, resveratrol, rat, nitric oxide, malondialdehyde

Received: 05.06.2017

Accepted: 06.14.2017

### ÖZET

**Amaç:** Bu çalışmanın amacı sıçan siyatik sinirinde resveratrolün iskemi-reperfüzyon (I / R) hasarı üzerine etkilerini belirlemektir.

**Yöntem:** Ketamin (50 mg / kg-im) ile anestezi uygulanmış 18 adet Wistar sıçanı kullandık. Sham grubunda herhangi bir ilaç vermeden sadece cerrahi uyguladık. İskemi grubunda 5 dakika aralıklarla I / R hasarı oluşturduk ve medikal tedavi olarak sadece salin verdik. Resveratrol grubunda da aynı I / R hasarını oluşturduk, ancak oral yolla işlemde önce resveratrol verdik. Ratlar sakrifiye edildikten sonra kan ve sinir doku örnekleri aldık. Hem doku hem de kandaki malondialdehit (MDA), nitrik oksit (NO) ve toplam antioksidan kapasiteleri (TAC) ile hasarı değerlendirdik.

**Bulgular:** Antioksidan belirteçlerin ve doku örneklerinin serum düzeylerinin değerlendirilmesi, iskemi-reperfüzyon hasarında resveratrolün istatistiksel olarak anlamlı etkilerini ortaya koymuştur.

**Sonuç:** Bu çalışma lipid peroksidasyonunun bir önleyicisi olarak resveratrolün antioksidan etkisini ortaya koymuştur.

**Anahtar Sözcükler:** Siyatik sinir, iskemi-reperfüzyon hasarı, resveratrol, sıçan, nitrik oksit, malondialdehit

Geliş Tarihi: 06.05.2017

Kabul Tarihi: 14.06.2017

## INTRODUCTION

Reperfusion damage is an undesirable condition that results from biochemical interactions between the blood and the damaged cell clusters when the blood flow is made to resume following local tissue damage caused by ischemia. Ischemia has been reported to quickly disrupt the normal functioning of peripheral nervous system tissues within 30 to 90 minutes of its initiation (1). Following studies focused on many organs and tissues affected by reperfusion damage, numerous suggestions have been formulated regarding the mechanisms underlying such conditions. The mechanisms of primary focus are cell swelling, the formation of toxic effective free oxygen radicals, the stoppage of the functioning of the energy depended Na-K-ATP pump, and increased liquid flow into cells (2-4).

The sciatic nerve, which is the thickest peripheric nerve in rats, originates from the lumbo-sacral truncus which consists of L4, L5, L6, and S1 spinal nerves. Sciatic nerve anatomy (SNA) has been under experimental study since the beginning of 20<sup>th</sup> century (5).

Resveratrol is a polyphenol compound found especially in red wine, red grapes, blackberries, sour cherries and peanuts (6). It has antioxidant, anti-inflammatory, cardioprotective, antidiabetic, anticancer, and neuroprotective properties, which are also effective in protecting liver and kidneys (7-10).

A significant number of studies on free radicals have pointed out the importance of resveratrol as an antioxidant and an ischemia- preventative and curative agent, primarily for the brain tissue and many other internal organs (11, 12). Resveratrol's effects arise via NO up regulation, prevention of the oxidation of membrane lipids, cleaning the tissues free oxygen radicals, and prevention of platelet aggregation (13, 14).

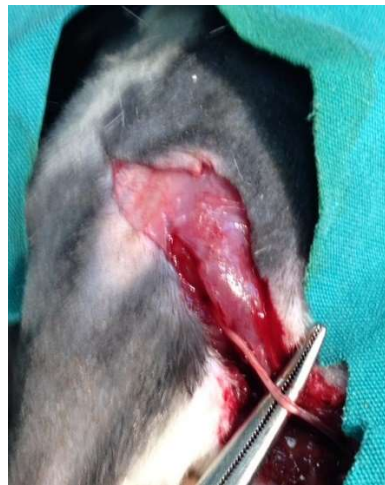The aim of this study was to investigate the effects of resveratrol treatment on Ischemia- reperfusion (I/R) damage in the sciatic nerve in rat.

## METHODS

This study was performed in the experimental animal laboratory of the University of Gazi, Ankara, Turkey. The animals used were 18 Wistar albino female rats in the weight range of 195–250 g. Ethical approval was obtained from University of Gazi ethics committee. All of the surgical procedures were performed by the same surgeon following standard techniques. In all groups, the sciatic nerves of the right extremities were used.

### *Surgical Technique*

Rats were anaesthetized via intramuscular injection of 50 mg/kg ketamine-HCl (Ketalar Flakon-IM Pfizer). Following this, body hair on the gluteal and femoral regions was shaved and the surgical area was cleaned using povidone iodine after identifying the feet in the prone position with a stable. Oblique gluteal incision was performed on the right hind leg. After the ecartation of the lining skin, the biceps femoris muscle could be identified. The muscle fibers are separated by blunt dissection, which are then removed without completely closing them. The incision is held open using a pair of forceps in either hand, and the superficial muscular layer is moved backwards and forwards until the sciatic nerve is identified (Figure 1). Using a dissection scissors, the nerve fiber was removed of its side tissue from the sciatic notch to the popliteal branching region.



**Figure 1.** Demonstrating of sciatic nerve

### *Study Groups*

Three study groups were determined as follows:

Group 1: Sham control group (n= 6). The right sciatic nerve was dissected and excised 1 cm proximal to the diverging point of the tibial and peroneal nerves. Group 2: Control group (n=6): One hour before the surgical procedure, 50 mg/kg doses of oral serum physiologics was given to rats. The right sciatic nerve was then dissected, compressed by clips from 1.5 cm proximal to the diverging point of tibial and peroneal nerves for 5 minutes, and waited for 5 more minutes for revascularization. At the 10<sup>th</sup> minute, the sciatic nerve was excised 1 cm proximal to the diverging point of the tibial and peroneal nerves. Group 3: Experimental group (n=6): One hour before the surgical procedure, 30 mg/kg doses Resveratrol was administered to rats. The right sciatic nerve was then dissected, compressed by clips from 1.5 cm proximal to the diverging point of tibial and peroneal nerves for 5 minutes, and waited for 5 more minutes for revascularization. At the 10<sup>th</sup> minute, the sciatic nerve was excised 1 cm proximal to the diverging point of the tibial and peroneal nerves.

Following the surgical procedures on the nerve fibers, all of the rats underwent euthanasia via massive intracardiac blood aspiration with the aid of injectors under sedation.

### *Biochemical Assessment*

The tissues were homogenized in a phosphate-buffered saline (PBS) solution (pH 7.4). Following this procedure, a 10,000 g centrifuge was administered at +4°C and supernatants were used.

Nitrate/nitrite levels, which are an indication of NO production, were assessed using Bio Assay Systems Quanti Chrom Nitric Oxide Assay Kit. MDA was used to examine membrane lipid peroxidation. MDA can be measured by thiobarbituric acid (TBA). Peroxidized membranes produce fragments which show color reactions with the TBA. This production is the main stage for the thiobarbituric acid reactive substance (TBARS) test. The assessment was carried out spectrophotometrically on 532 nm.

Total antioxidant status (TAS) was analyzed accordingly with the protocol supported by the manufacturer of the commercially derived diagnostics kit (Rel Assay Diagnostics). Antioxidants found in sample solutions turn the blue-green colored ABST radical into its colorless form. TAS of the sample was identified via the spectrophotometrically observed change in absorbance at 660 nm. The standard solution of antioxidants was the Trolox equivalent, which is a vitamin E analogue.

### *Histopathological Assessment*

All of the tissue samples were first identified in a 10% formaldehyde solution for light microscope assessment. Following the identification process, tissue samples were washed under tap water in cassettes for 24 hours. Samples were then administered increasing degrees of alcohol solutions (70%, 80%, 90%, and 100%) to remove the water within tissues. Tissues were then passed through xylol for brightening, and they were finally buried in liquefied paraffin wax. Four-to-five micron segments were cut from the paraffin blocks and hematoxylin–eosin staining was administered. Their photos were derived following the Leica Q Vin 3 program assessment. Histopathological assessment was carried out by the pathologist blind for the study groups.

### *Statistical Analysis*

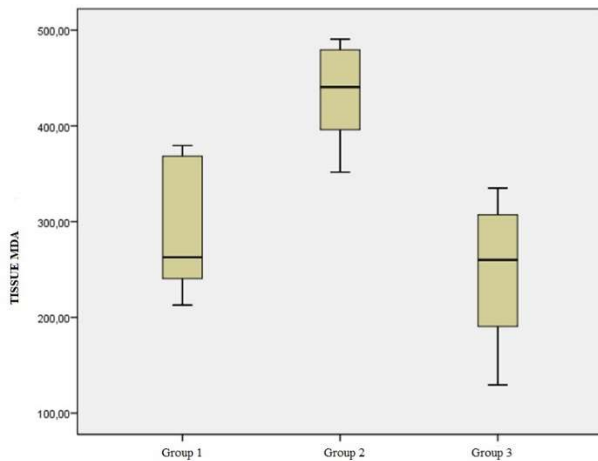
Statistical analysis was performed with IBM SPSS Statistics software version 20. Descriptive and inferential analyses of the compared data were carried out via the analysis of variance (ANOVA) and Kruskal–Wallis H tests with a significance level of  $p < 0.05$  (95% confidence interval).

## RESULTS

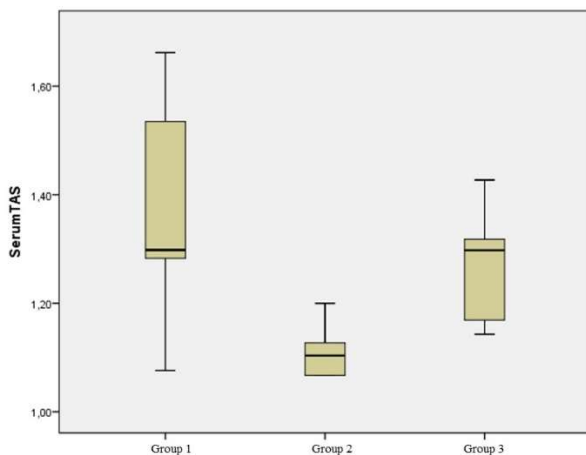
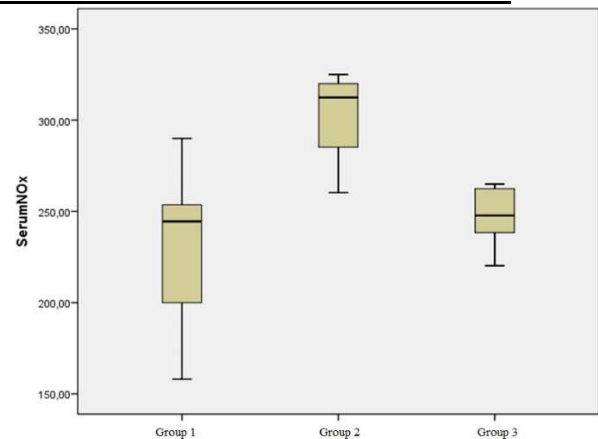
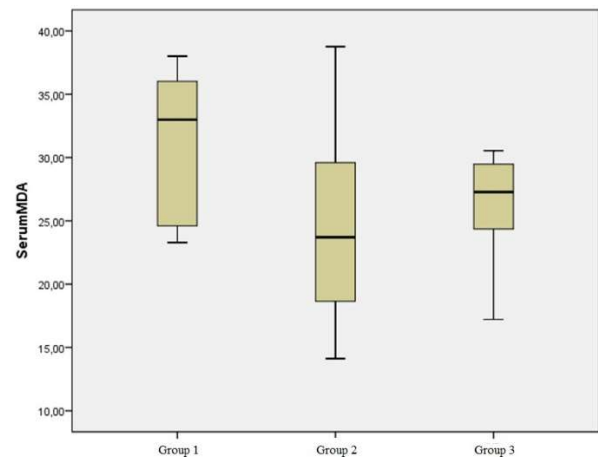
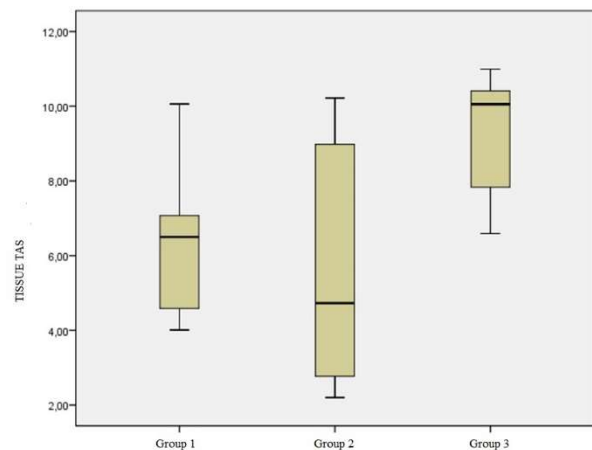
Serum and tissue levels of MDA, NOx, TAS are seen in Table 1. MDA analysis of tissue samples revealed a significant difference between groups ( $p=0.001$ ) (figure 1). This difference appeared between Group 1 and Group 2 ( $p=0.006$ ), as well as between Group 2 and Group 3 ( $p=0.001$ ). The mean MDA values for Group 2 were significantly higher than for Group 1. Similarly, Group 2 MDA values showed statistically higher values with respect to Group 3 data.

**Table 1:** Serum and tissue levels of NO, MDA and TAS

		SERUM NO <sub>x</sub>	SERUM MDA	TISSUE MDA	SERUM TAS	TISSUE TAS
Group 1 (control)	Mean±SD (min-max)	231,02±46,26 (158,00-90,00)	35,95±15,57 (23,29-37,79)	287,77±69,34 (212,80-379,40)	1,36±0,21 (1,08-1,66)	9,89±10,25 (4,01-11,67)
Group 2 (Ischemia)	Mean±SD (min-max)	302,55±24,91 (260,25-325,26)	24,76±9,08 (14,12-38,76)	433,15±54,95 (351,70-490,60)	1,15±0,13 (1,07-1,41)	5,61±3,28 (2,20-10,22)
Group 3 (Ischemia + Resveratrol)	Mean±SD (min-max)	246,91±17,17 (220,23-265,00)	26,03±4,84 (17,21-30,55)	247,03±79,15 (129,40-335,00)	1,28±0,10 (1,14-1,43)	10,81±4,32 (6,59-13,92)

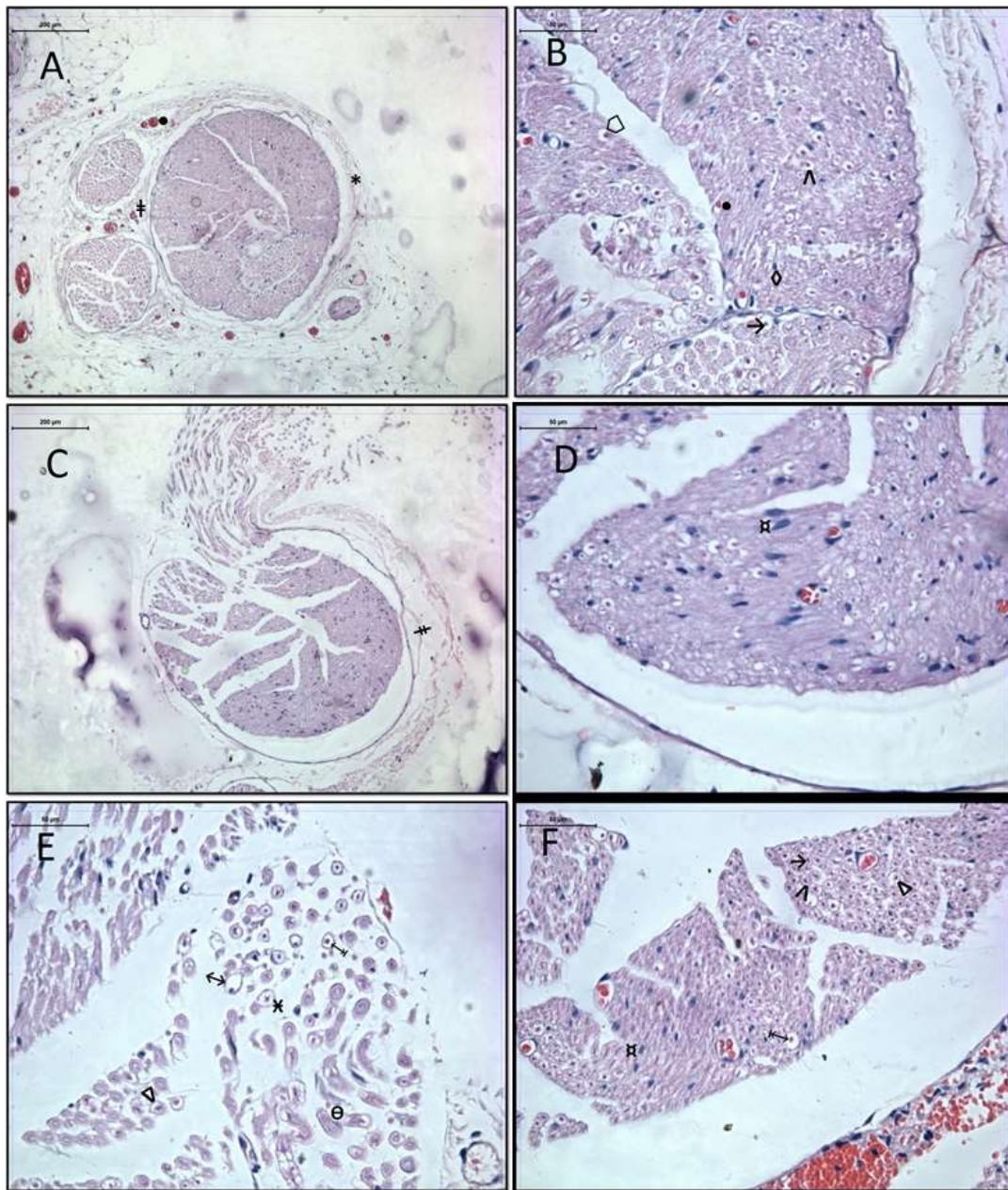
**Figure 1.** Tissue MDA levels of groups.

Serum TAS levels did not differ significantly among the groups ( $p=0.088$ ,  $>0.05$ ) (Figure 2). In contrast, serum mean NO<sub>x</sub> levels (Figure 3) were significantly different between Group 1 and Group 2 ( $p=0.001$ ), where the Group 1 mean was significantly lower than the Group 2 mean. There was a difference between the mean values of Group 2 and Group 3, but this difference was not statistically significant ( $p>0.05$ ). There was not a statistically significant difference for serum MDA (Figure 4) and tissue TAS (Figure 5) levels according to the groups ( $p=0.278$  and  $p=0.069$ , respectively).

**Figure 2.** Serum TAS levels of groups.**Figure 3.** Serum NO<sub>x</sub> levels of groups.**Figure 4.** Serum MDA levels of groups.**Figure 5.** Tissue TAS levels of groups

Compounds of the peripheral nerve tissue were normal in Group 1. The epineurium, perineurium, and endoneurium were all structured normally.

Nerve fibers were clearly outlined, with their central axons surrounded by myelin sheaths. Schwann cells nucleuses which compose the myelin sheaths, were also observable. Capillary veins laying through the connective tissue substructures also showed normal formation (Figure 6 A, B).



**Figure 6.** A. Epineurium (\*), perineurium (‡) and blood vessels of group 1 are seen. (hematoxylin-eosin x100) B. Group 1 endoneurium (◻), axon (→), myelin sheath (Λ), Schwann cell (◊), and blood vessels (●) (hematoxylin-eosin x400). C. Perineurium seen in Group 2 (‡) (hematoxylin-eosin x100). D. Hypertrophy and hyperplasia of Schwann cells in Group 2 (⌘) (hematoxylin-eosin x400). E. Group 2 samples demonstrated swelling of myelinated nerve fibers (↔), myelin sheath degeneration (⊥), partial myelin sheath

degeneration (Δ), contact between nerve fibers (Θ), and endoneurial edema (×) (hematoxylin-eosin x400). F. Group 3 samples demonstrated hypertrophy and hyperplasia in Schwann cells (⌘), myelin sheath degeneration (⊥), partial myelin sheath degeneration (Δ), contact between nerve fibers (Θ), and endoneurial edema (×). Symbols for axons and myelin sheaths are (→) and (Λ), respectively. (hematoxylin-eosin x400).

Perineurium integration showed occasional disturbances in Group 2 samples. Detailed observations revealed hypertrophy and hyperplasia within Schwann cells surrounding nerve fibers. Numerous tissues also demonstrated swelling of myelinated nerve fibers, as well as myelin degeneration. Some of these fibers showed a partial degeneration of myelin sheaths, whereas the rest appeared to have undergone complete degeneration. Occasional nerve fiber contacts resulted in their combining with each other; in such locations of nervous tissue degeneration, endoneurial edema was also prevalent. Even though some samples did not show endoneurial edema, they had significantly swollen nerve fibers, as well as clearly identifiable myelin loss (Figure 6 C, D, E).

Group 3 sample analysis revealed that although Schwann cell hypertrophy and hyperplasia were significant in the ischemia group, no significant endoneurial edema was present. Nerve fiber assessments demonstrated that most individual fibers had normal myelin structures with intact central axons; however, the remaining fibers appeared to have undergone myelin sheath degeneration, similar to the members of the ischemia group. Myelin degeneration was complete in some fibers, whereas it appeared to be partial in one subgroup (Figure 6 F).

## DISCUSSION

Our study demonstrated that resveratrol applied orally before I/R damage could reduce the extent of peripheral nerve damage. Histological findings confirmed the presence of ischemia alongside significant effects of resveratrol, which partially reduced its effects in the study group. Some samples showed a reduction in endoneurial edema, whereas myelin degeneration was almost always observed. This degeneration was partial in some samples and complete in others.

I/R damage causes multiple organ failure within hours of its initiation and gives way to the production of free oxygen radicals, as well as pro-inflammatory mediators. These oxygen radicals, in turn, cause lipid peroxidation (15-17). This is the reason for membrane disruption, mitochondrial damage, and finally, cell death (18,19). NO acts as a protective agent against I/R damage in organs (20, 21). However, numerous studies have shown that following I/R, NO synthase may synthesize free oxygen radicals instead of NO (22, 23).

Despite rigorous research, the mechanisms of I/R damage are still not properly understood. It is highly plausible to consider resveratrol as a protective agent for internal organs due to its antioxidant and anti-inflammatory characteristics (24). Previous research has highlighted the neuroprotective effects of resveratrol in enhancing its antioxidant effects and associated NO synthesis. The effects of NO on nervous system tissue, however, are controversial, as NO appears to support neurotoxic and neuroprotective effects simultaneously (25, 26). NO is a free radical on its own yet, it can be a potent antioxidant in certain environments. Kiziltepe and colleagues observed that NO levels rose in the resveratrol applied group in a spinal cord damage model, where reduced NO levels were associated with severe neurological deficits (27). In our study, serum TAS and NO levels significantly increased in line with the degree of ischemia in the respective experimental groups; however, although resveratrol application decreased ischemic damage in the relevant samples, this effect could not be demonstrated to be statistically significant. The short duration between ischemia initiation and blood sampling, as well as the low amounts of blood samples, could have influenced our results. NO activity in tissues could not be studied due to insufficient amounts of tissue samples.

Sinha and colleagues reported that antioxidant activities of trans-resveratrol caused decreases in infarct volumes caused by focal ischemia in brain tissue (28).

Lipid peroxidation is one of the most important organic markers for oxidative stress, where the associated reactivity is triggered by free oxygen radicals. The synthesis of MDA during lipid peroxidation can easily be assessed in biological samples, and this is a relatively stable marker of peroxidative damage (29). MDA reacts with lysine residues of proteins and amine groups of phospholipids (30). As this compound can diffuse easily, it can cause damage following its reactions with DNA bases. In their spinal cord damage model, Kiziltepe and colleagues showed that MDA levels are reduced in animals with high doses of applied resveratrol (27). In our study, we demonstrated that the tissue MDA level rose significantly along with ischemic damage, and in line with previous research, the resveratrol- applied group showed subsequent reductions in tissue MDA levels that were significantly lower than the levels observed in the other two groups. Our findings support the idea that resveratrol has effective antioxidant properties. Notably, significant reductions in MDA levels are suggestive of inhibitory effects of resveratrol on lipid peroxidation during the early stages of peripheral nerve damage. Pre-ischemia resveratrol applications showed similar ranges of tissue MDA levels with non-ischemic tissue samples. Pre-ischemia serum levels, in contrast, showed significant differences following such a comparison.

In their I/R model where arteries feeding sciatic and tibial nerve fibers were connected, Yoshiyuki et al reported protective effects of racemic alpha lipoic acid (LA) against reperfusion damage on peripheral nerves (31). Grey et al examined the effects of 2-sulfo-phenyl-N-tert-butyl nitrone (S-PBN) on reperfusion damage occurring in rat peripheral nerves and found that post-ischemic applications of S-PBN could have important neuroprotective characteristics on I/R nerve damage (32). After examining mRNA expressions of the pro-inflammatory cytokines, tumor necrosis factor- $\alpha$  (TNF- $\alpha$ ) and interleukin-1 $\beta$  (IL-1 $\beta$ ) following I/R damage in rat sciatic and tibial nerve fibers, Mitsui et al. reported that TNF- $\alpha$  and IL-1 $\beta$  mRNA expressions were correlated with the ischemic damage on their own, and they were even more significantly associated with reperfusion than ischemia itself (33). TNF- $\alpha$  gene expression peaked at the 24<sup>th</sup> hour of reperfusion, while the IL-1 $\beta$  peak appeared at the 12<sup>th</sup> hour.

These observations support the idea that TNF- $\alpha$  and IL-1 $\beta$  are involved in the inflammatory response to peripheral nervous system I/R damage. Hence, these compounds can be important for the pathophysiology of ischemic nerve tissue degeneration.

Previous research in the literature has demonstrated the protective effects of resveratrol against I/R damage in many regions of the body, including cardiac tissue, kidneys, brain tissue, and the spinal cord. Its effects on the peripheral and central nervous systems are promising. Although intraperitoneal applications were favored in previous research, we chose the oral application method due to our considerations for human use. Resveratrol's oral preparations are available the market, and the clinical use of resveratrol for acute ischemia can be regarded as plausible given our research findings.

In conclusion, we can confidently say that single doses of resveratrol applied post- I/R can alleviate lipid peroxidation rates and hence can be protective against neural tissue damage. The most important limitation of our research was the absence of subsequent longitudinal observations of resveratrol's long-term effects. The limited rat sciatic nerve fiber dimensions also prevented us from examining tissue NO levels.

Future research needs to be longitudinal and to implement a broader scope to assess the efficacy of resveratrol. Along with antioxidant effects, cellular effects should be examined in both acute and chronic pathologies.

## Conflict of interest

No conflict of interest was declared by the authors.

## REFERENCES

1. Joseph E, and Schoepfle GM. A study of nerve degeneration and regeneration. *American Journal of Physiology-Legacy Content*. 1946;147: 550-81.
2. Weisfeldt ML. Reperfusion and reperfusion injury. *Clin Res*. 1987; 35: 13-20.
3. Greene HL, Weisfeldt ML. Determinants of hypoxic and post-hypoxic myocardial contracture. *Am J Physiol*. 1997; 232 (5): 526-33.
4. Mahboob M, Siddiqui M.K. Long-term effects of a novel phosphorothionate (RPR-II) on detoxifying enzymes in brain, lung and kidney rats. *Ecotoxicol Environ Saf*. 2002; 53: 355-60.
5. Ramón y Cajal S. The structure and connexions of neurons. 1906 Nobel prize acceptance speech.
6. Ménard C, Stéphane B, and Quirion R. Neuroprotective effects of resveratrol and epigallocatechin gallate polyphenols are mediated by the activation of protein kinase C gamma. *Front Cell Neurosci*. 2013; 7: 281.
7. Marchal J, Pifferi F, and Aujard F. Resveratrol in mammals: effects on aging biomarkers, age-related diseases, and life span. *Annals of the New York Academy of Sciences*. 2013; 1290: 67-73.
8. Leonard SS, Xia C, Jiang BH, Stinefelt B, Klandorf H, Harris GK, Shi X. Resveratrol scavenges reactive oxygen species and effects radical-induced cellular responses. *Biochemical and biophysical research communications*. 2003; 309:1017-26.
9. Takayuki S, Nakazato T, Xian MJ, Sagawa M, Ikeda Y, Kizaki M. Resveratrol induces apoptosis of human malignant B cells by activation of caspase-3 and p38 MAP kinase pathways. *Biochemical pharmacology*. 2006; 71: 742-50.
10. Tsai S, Hung L, Fu Y, Cheng H, Nien M, Liu H, Zhang F, Huang S. Resveratrol neuroprotective effects during focal cerebral ischemia injury via nitric oxide mechanism in rats. *Journal of vascular surgery*. 2007; 46: 346-53.
11. Huang, S.S., Tsai, M.C., Chih, C.L., Hung, L.M. and Tsai, S.K. Resveratrol reduction of infarct size in Long-Evans rats subjected to focal cerebral ischemia. *Life Sci*. 2001; 69: 1057-65.
12. Hung LM, Chen JK, Huang SS, Lee RS, and Su MJ. Cardioprotective effect of resveratrol, a natural antioxidant derived from grape. *Cardiovasc Res*. 2000; 47: 549-55.
13. Fremont L. Biological effects to resveratrol. *Life Sci* 2000; 66: 663-73.
14. Shigematsu S, Ishida S, Hara M, Takahashi N, Yoshimatsu H, Sakata T, Korthuis RJ. Resveratrol, a red wine constituent polyphenol, prevents superoxide-dependent inflammatory responses induced by ischemia/reperfusion, platelet-activating factor, or oxidants. *Free Radic Biol Med*. 2003; 34: 810-7.

15. Liao YF, Zhu W, Li DP, and Zhu X. Heme oxygenase-1 and gut ischemia/reperfusion injury: a short review. *World J Gastroenterol.* 2013; 19: 3555-61.
16. Weyker PD, Webb CAJ, Kiamanesh D, and Flynn BC. Lung ischemia reperfusion injury: a bench-to-bedside review. *Semin Cardiothorac and Vasc Anesth.* 2013; 17: 28-43.
17. Vardanian AJ, Busuttill RW, and Kupiec-Weglinski JW. Molecular mediators of liver ischemia and reperfusion injury: a brief review. *Molec Med.* 2008; 14: 337-45.
18. Antonuccio P, Minutoli L, Romeo C, Nicotina PA, Bitto A, Arena S, Altavilla D, Zuccarello B, Polito F, Squadrito F. Lipid peroxidation activates mitogen-activated protein kinases in testicular ischemia-reperfusion injury. *J Urol.* 2006; 176: 1666-72.
19. Yaylak F, Canbaz H, Caglikulekci M, Dirlik M, Tamer L, Ogetman Z, Polat Y, Kanik A, Aydin S. Liver tissue inducible nitric oxide synthase (iNOS) expression and lipid peroxidation in experimental hepatic ischemia reperfusion injury stimulated with lipopolysaccharide: the role of aminoguanidine. *J Surg Res.* 2008; 148: 214-23.
20. Folino A, Losano G, and Rastaldo R. Balance of nitric oxide and reactive oxygen species in myocardial reperfusion injury and protection. *J Cardiovasc Pharmacol.* 2013; 62: 567-75.
21. Abu-Amara M, Yang SY, Seifalian A, Davidson B, and Fuller B. The nitric oxide pathway—evidence and mechanisms for protection against liver ischaemia reperfusion injury. *Liver Int.* 2012; 32:531-43.
22. Dong W, Li F, Pan Z, Liu S, Yu H, Wang X, Bi S, Zhang W. Resveratrol ameliorates subacute intestinal ischemia-reperfusion. *J Surg Res.* 2013; 185: 182-89.
23. Simão F, Matt'e A, Matt'e C, Soares FMS, Wyse ATS, Netto CA, Salbego CG. Resveratrol prevents oxidative stress and inhibition of Na<sup>+</sup>K<sup>+</sup>-ATPase activity induced by transient global cerebral ischemia in rats. *J Nutr Bioch.* 2011; 22: 921-28.
24. Liu F, Tsai H, Yu H. Organ protective effects of red wine extract, Resveratrol, in oxidative stress-mediated reperfusion injury. *Oxidative Medicine and Cellular Longevity.* 2014; 2015: 1-15.
25. Lipton SA. Neuronal protection and destruction by NO. *Cell death and differ.* 1999; 6: 943–51.
26. Centeno JM, Orti M, Salom JB, Sick TJ, Perez- Pinzon MA. Nitric oxide is involved in anoxic preconditioning neuroprotection in rat hippocampal slices. *Brain Res.* 1999; 836: 62-69.
27. Kiziltepe U, Turan NND, Han U, Ulus T, Akar F. Resveratrol, a red wine polyphenol, protects spinal cord from ischemia- reperfusion injury. *J Vasc Surg.* 2004; 40: 138-45.
28. Kusum S, Chaudhary G, and Gupta YK. Protective effect of resveratrol against oxidative stress in middle cerebral artery occlusion model of stroke in rats. *Life sciences.* 2002; 71: 655-65.
29. De Zwart LL, Meerman JHN, Commandeur JNM, Vermeulen NPE. Biomarkers of free radical damage applications in experimental animals and in humans. *Free Radical Biology and Medicine.* 1999; 26: 202-26.
30. Uchida K. Role of reactive aldehyde in cardiovascular diseases. *Free Radical Biology and Medicine.* 2000; 28: 1685-96.
31. Mitsui Y, Schmelzer JD, Zollman PJ, Mitsui M, Tritschler HJ, Low PA. Alpha-lipoic acid provides neuroprotection from ischemia - reperfusion injury of peripheral nevre. *J Neurol Sci.* 1999; 163 : 11-6.
32. Gray C, Nukada H, Jackson DM, McMorran PD, Wu A, Ma F. Neuroprotective effects of nitron radical scavenger S-PBN on reperfusion nerve injury in rats. *Brain Res.* 2003; 932: 179-85.
33. Mitsui Y, Okamoto K, Martin DP, Schmelzer JD, Low PA. The expression of proinflammatory cytokine mRNA in the sciatic-tibial nerve of ischemia -reperfusion injury. *Brain Research.* 1999; 844: 192-5.