

Infected Retroareolar Breast Cysts in an Adolescent Girl: A Case Report

Adölesan Bir Kızda Enfekte Retroareolar Meme Kistleri: Olgu Sunumu

Meltem Akcaboy¹, Sanliay Sahin¹, Hasibe Gokce Cinar², Melahat Melek Oguz¹, Pelin Zorlu¹, Saliha Senel¹

¹ Dr. Sami Ulus Maternity and Children's Health and Diseases Training and Research Hospital, Department of Pediatrics, Ankara, Turkey

² Dr. Sami Ulus Maternity and Children's Health and Diseases Training and Research Hospital, Department of Radiology, Ankara, Turkey

ABSTRACT

Adolescent girls have breast problems to be managed. Pediatricians are frequently the first consultants of this clinical entity. Breast cysts lead the benign conditions of the breast problem. A 15-year-old girl admitted to our hospital with pain and swelling on the right breast. On physical examination, periareolar erythema in the presence of a tender subareolar mass on the right breast and non-tender, smooth, non-fixated retroareolar mass on the left breast was prominent. Ultrasonographic evaluation identified an infected retroareolar cyst. Medical treatment was successful without any invasive intervention. First-line conservative management for infected cysts is antibiotherapy. Every effort should be made to preserve the developing breast bud and drainage considered only in the rare presence of abscess formation unresponsive to antibiotics. Unlike adults, hormonal evaluation should be done in every girl. Multidisciplinary long term follow-up is crucial.

Key Words: Breast cyst, adolescent, girl

Received: 03.29.2017

Accepted: 06.29.2017

ÖZET

Meme sorunları ile adölesan kızlarda sık karşılaşılr. Meme kistleri, en sık görülen iyi huylu sorunlar içinde başı çekmektedir. Bu sorunlar erişkin dönemdeki meme sorunlarının temelini oluşturması nedeniyle oldukça önemlidir. Çocuk Sağlığı ve Hastalıkları uzmanları bu sorunlar ile ilk basamakta karşılaşan ve çözüm üretmesi gereken hekimlerdir. Onbeş yaşında kız hasta, merkezimize sağ memede şişlik ve ağrı şikayeti ile başvurdu. Fizik muayenede sağ memede, periareolar eritem ile subareolar hassas kitle ve sol memede ağrısız, düzgün sınırlı, mobil retroareolar kitle saptandı. Ultrasonografik incelemede, retroareolar enfekte kistler gösterildi. Girişimsel bir işlem yapılmadan antibiyotik tedavisi ile hasta izlendi. Meme kistlerinin enfeksiyonunda antibiyotik tedavisi ilk basamak tedavidir. Meme tomurcuğunu korumak adına girişimsel işlemler ertelenmelidir. Nadir vakalarda abse drenajı gerekebilir. Erişkinlerin aksine, adölesan kızlarda hormonal değerlendirme yapılmalıdır. İzlemede multididipliner yaklaşım önemlidir.

Anahtar Sözcükler : Meme kisti, adölesan, kız

Geliş Tarihi: 29.03.2017

Kabul Tarihi: 29.06.2017

INTRODUCTION

Breast cysts are common in women over 35 years, being one of the symptoms of dysplastic lesions or hormonal disturbances. However, they are also seen in adolescent girls (1). Cysts may constitute a serious clinical problem like inflammation and infection and also require assessment of concomitant hormonal disorders (2). The clinical follow-up of this entity needs a multidisciplinary approach especially in adolescent girls (3). Here we report an adolescent girl having an infected retroareolar breast cyst in order to emphasize the breast problems in adolescent girls.

CASE REPORT

A healthy 15-year-old girl admitted to our hospital with pain and swelling on the right breast for 3 days. She had mild pyrexia. She did not report any trauma. Her menstrual periods were normal. Her past medical history and family history was unremarkable. Physical examination identified periareolar erythema with the presence of a tender subareolar mass on the right breast and non-tender, smooth, non-fixated retroareolar mass on the left breast. The Ultrasonographic evaluation revealed five-lobulated cysts located behind the nipple having the greatest size of 16x9 mm.

Address for Correspondence / Yazışma Adresi: Meltem Akcaboy, MD Dr. Sami Ulus Maternity and Children's Health and Diseases Training and Research Hospital, Babur Caddesi No. 44, 06080, Altındag, Ankara, Turkey E-mail: meltemileri@yahoo.com

©Telif Hakkı 2017 Gazi Üniversitesi Tıp Fakültesi - Makale metnine <http://medicaljournal.gazi.edu.tr/> web adresinden ulaşılabilir.

©Copyright 2017 by Gazi University Medical Faculty - Available on-line at web site <http://medicaljournal.gazi.edu.tr/>

doi:<http://dx.doi.org/10.12996/gmj.2017.80>

The cysts contained hypoechoic fluid with surrounding hyperemia and subcutaneous tissue edema (Figure 1-A). Also the asymptomatic left breast had three retroareolar cysts having the greatest size of 10x6 mm. Laboratory evaluation was as follows; hemoglobin: 13.4 gr/dl; platelet count: 222000 /mm³; white blood cell count: 15190 /mm³; sedimentation rate: 35 mm/h; C-reactive protein: 18.8 mg/L. Neutrophil dominance was prominent in peripheral blood smear. The diagnosis was made as retroareolar cyst infection and oral antibiotherapy with amoxicillin clavulanate was started. The child surgeons have decided not to aspirate the mass but to follow-up the patient

attentively. The control Ultrasonography revealed a well-defined anechoic cysts rather than abscess formation (Figure 1-B). The lesion had decreased in size, and clinical examination revealed no existing erythema or tenderness on palpation of the inflammatory mass. The patient responded well to the 14-days oral amoxicillin clavulanate therapy. The acute phase reactants turned to normal values after the treatment. Hormonal endocrinological evaluation revealed normal results (FT4: 1.08 ng/dL; TSH: 1.584 µU/mL; FSH: 10.28 mIU/mL; LH: 16.98 mIU/mL; E2: 83.4 pg/mL; Progesteron: <0.21 ng/mL; Prolactin: 7.26 ng/mL). The patient is being followed by departments of pediatrics, pediatric surgery and pediatric oncology.

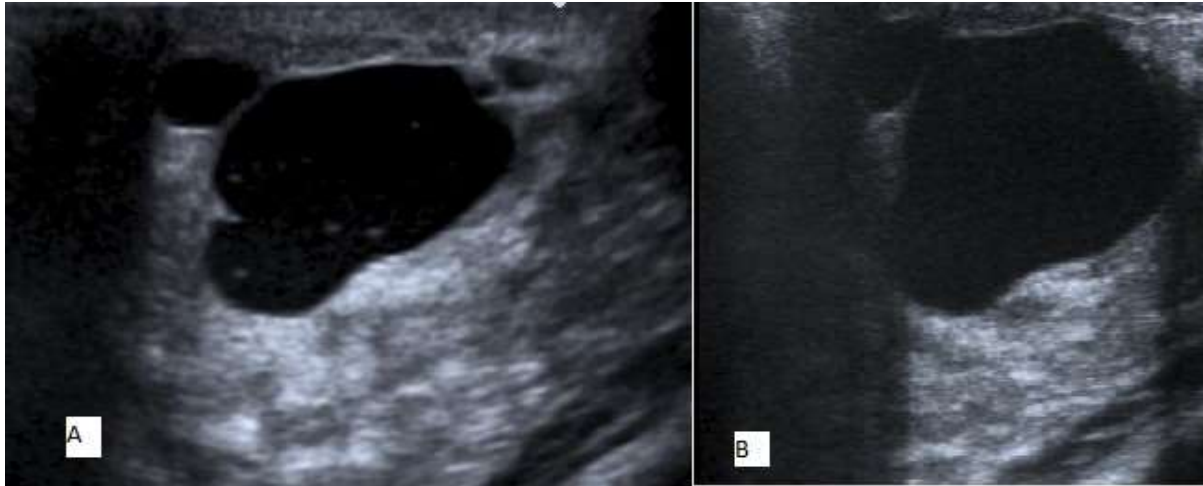


Figure 1. A. Ultrasonography of right breast showing a well-circumscribed oval cystic mass internal ecogenities. **B.** Control Ultrasonography of the right breast after treatment.

DISCUSSION

The increased awareness of female breast cancer has led to increased sensitivity toward pathologic breast conditions in adolescence and childhood. However, the spectrum of breast diseases in childhood and adolescence is substantially differ from that in adults (4). Quite the opposite the adults, the risk of malignancy is low (5). Breast masses or breast enlargements in children and adolescents are usually of a benign nature. Solid benign tumors, developmental disturbances and cystic changes lead the benign breast lesions in adolescent girls (4). Minor breast problems lead to increased anxiety among young patients and their families, especially due to high correlation with breast cancer (5). However, individual case reports of malign masses like sarcomas have been reported (6). Even in young girls, progressively growing breast masses should alert clinicians to check for malignancy. Pediatricians are generally the first consultants who make the diagnosis but multidisciplinary long-term follow-up is essential and necessary for patients.

Breast cysts are one of the common benign breast lesions that should be considered in pediatric practice. Referral indications to the clinics occasionally include pain, breast swelling and palpable painful nodules (1). Cystic changes may be asymptomatic, but usually manifest with the signs of infection. Ultrasonography is the first choice of examination in the diagnostics of breasts in children and adolescents like adults (7). Although cystic changes can be easily distinguished from solid lesions, the differentiation between fibroadenoma and phylloides tumor is difficult. Ultrasonography images of cysts and infected cysts are typical with a round or oval mass with a distinct capsule, fluid-like echogenic content, posterior enhancement and increased vascular flow (1).

Infected cysts are generally responsive to antibiotics; but rarely invasive procedures and drainage are needed due to abscess formation (2). Successful management of retroareolar cysts is dependent on distinguishing inflammatory retroareolar cysts from a breast abscess. Through this distinction unnecessary needle aspiration and possible trauma to the developing breast bud can be avoided. In the absence of sepsis or severe pain, patients with inflammatory cystic lesions can be managed outpatiently (2). Close clinical and sonographic follow-up is recommended after the diagnosis of infected cysts. Our patient responded well to the antibiotherapy and did not need further manipulation for drainage.

Unlike adults, adolescent girls should be evaluated for hormonal disturbances after the diagnosis of breast cysts (1). The most common problem is luteal atelectasis and elevated prolactin levels, respectively. Luteal atelectasis means a relative disproportion of estrogens with respect to progesterone in the phase II of the menstrual cycle. It is assumed that the relative disproportion between the level of estrogens and progesterone plays a role in the formation of breast cysts in adolescents (1, 4). The level of estrogens tends to be normal, but there is commonly a deficiency of

progesterone in the second cycle of the menstruation, which frequently results in luteal atelectasis. Breast cysts persisting for longer than 6 months with low progesterone levels, constitute an indication for hormonal therapy with progesterone(1, 2). Hormonal evaluation of our patient revealed normal results. She is in follow-up closely by clinical and sonographic evaluation. Persisting breast cysts will be stimulating to consider the reevaluation of hormonal disturbances.

Breast problems leaded by benign disorders are not rare in adolescent girls. Pediatricians are the first medical team to face and manage the disorders. Complicated problems such as infected breast cysts are managed successfully with conservative approach, and invasive procedures should be postponed in order to protect the breast bud and tissue. Disparate from adults, hormonal evaluation should be done in every adolescent girl. Multidisciplinary long term follow-up is crucial.

Conflict of interest

No conflict of interest was declared by the authors.

REFERENCES

1. Jakubowska A, Grajewska-Ferens M, Brzewski M. Breast cysts in adolescents—diagnostics, monitoring, treatment. *Polish Journal of Radiology*. 2011;76:20.
2. Wallace D, Sian A, Carne A, Irvine TE. Diagnosis and management of retroareolar cysts in adolescents: a case report. *Journal of surgical case reports*. 2013;2013:rjt052.
3. Balleyguier C, Arfi-Rouche J, Haddag L, Canale S, Delalogue S, Dromain C. Breast pain and imaging. *Diagnostic and interventional imaging*. 2015;96:1009-16.
4. Bock K, Duda VF, Hadji P, Ramaswamy A, Schulz-Wendtland R, Klose K-J, et al. Pathologic Breast Conditions in Childhood and Adolescence Evaluation by Sonographic Diagnosis. *Journal of ultrasound in medicine*. 2005;24:1347-54.
5. Michala L, Tsigginou A, Zacharakis D, Dimitrakakis C. Breast disorders in girls and adolescents. Is there a need for a specialized service? *Journal of pediatric and adolescent gynecology*. 2015;28:91-4.
6. Tekbas G, Ince T, Kapan M, Ekici F, Önder A, Kucukonen M, et al. Are breast masses in teenagers always benign? Undifferentiated mesenchymal sarcoma in a 14-year-old girl. *Breast Care*. 2012;7:144-6.
7. Chang Y-W, Kwon KH, Goo DE, Choi DL, Lee HK, Yang SB. Sonographic differentiation of benign and malignant cystic lesions of the breast. *Journal of ultrasound in medicine*. 2007;26:47-53.