

Rare Variation of the Profunda Brachii Artery and its Clinical Significance

Arteria Profunda Brachii'nin Nadir Varyasyonu ve Klinik Önemi

Zafer Kutay Coskun¹, Kerem Atalar², Yadigar Kastamoni¹, Neslihan Gurbuz³, Hasan Basri Turgut¹

¹Gazi University Faculty of Medicine Department of Anatomy, Ankara, Turkey

²Bülent Ecevit University Faculty of Medicine Department of Anatomy, Zonguldak, Turkey

³Gazi University Faculty of Medicine Biochemistry Laboratory, Ankara, Turkey

ABSTRACT

Variations in the origin of axillary artery branches are one of the most common variations. However, derivation of profunda brachii artery from circumflex humeral artery is a rare occurrence. Since it is a frequent site of injury and it is involved in many surgical and invasive procedures, the arterial variations in the arm is important for a clinician. During routine dissection, for students of medical school, a variation of profunda brachii artery was observed in right upper extremity of 62 year old male cadaver. In the present study, profunda brachii artery arose from posterior circumflex humeral artery and radial nerve in radial sulcus did not accompany profunda brachii artery. Awareness of details of variations of the axillary artery may function as a beneficial guide for vascular surgeons. It may contribute to preventing complications during the surgery of the axilla region.

Key Words: Profunda brachii artery, axillary artery, arterial variation

Received: 08.29.2016

Accepted: 09.02.2016

ÖZET

A. axillaris dallarının çıkış yerindeki varyasyonlar en yaygın varyasyonlardan biridir. Ancak a. circumflexa humeri'den a. profunda brachii'nin çıkması pek ender bir durumdur. Sık sakatlanan bir bölge olduğu için ve pek çok cerrahi ve invazif prosedürler ile ilgili olduğu için koldaki arterial varyasyonlar klinisyen için önemlidir. Tıp öğrencileri için gerçekleştirilen rutin bir diseksiyon sırasında a. profunda brachii'nin varyasyonu 62 yaşındaki erkek bir kadavranın sağ üst ekstremitesinde gözlemlenmiştir. Bu çalışmada, a. profunda brachii a. circumflexa humeri posterior'dan çıkmıştır ve sulcus radialis'teki n. radialis a. profunda brachii'ye eşlik etmemiştir. A. axillaris varyasyonlarının detayları ile ilgili farkındalık vasküler cerrahlar için faydalı bir rehber görevi görebilir. Axilla bölgesindeki cerrahi işlemler sırasındaki komplikasyonları önlemede katkı sağlayabilir.

Anahtar Sözcükler: Arteria profunda brachii, arteria axillaris, arteriyel varyasyon

Geliş Tarihi: 29.08.2016

Kabul Tarihi: 02.09.2016

INTRODUCTION

Variations in the origin, branching and course of the main arteries of the human upper limb are common and have long attracted the attention of anatomists and surgeons (1,2). The brachial artery is the main artery in the arm. The profunda brachii artery which follows the radial nerve closely, between the long and the medial heads of the triceps brachii muscle and then in the radial groove, is a large branch from the brachial artery. It divides into the radial collateral and the middle collateral arteries. In the early stages of embryonic development, four or five intersegmental branches of the dorsal aortae supply vascular plexuses of the limb buds. The lateral branches of the seventh cervical intersegmental arteries enlarge and from the axial arteries of the upper extremities. The brachial artery develops from the proximal part and the common interosseous artery from the distal part of the axial artery (2). Variations of the brachial artery and its branches are common and they are sometimes associated with an anomalous arrangement of the nerves of the brachial plexus (3,4).

CASE REPORT

During routine dissection for students of medical school, a variation of profunda brachii artery was observed in right upper extremity of 62 year old male cadaver. As seen in figure 1, axillary nerve and posterior circumflex humeral artery passed through quadrangular space and axillary nerve gave branches to teres minor muscle and deltoid muscle, profunda brachii artery arose from posterior circumflex humeral artery and coursed downwards at the posterior of teres major muscle. In addition, it was observed that the middle collateral branch which was cut by mistake during routine dissection originated about 2 cm below the origin of profunda brachii artery and that radial collateral artery coursed downwards as continuation of profunda brachii artery with the accompaniment of radial nerve at radial sulcus and its branch at the medial side of radial nerve extended towards lateral head of triceps brachii muscle.

Address for Correspondence / Yazışma Adresi: Zafer Kutay Coşkun, DVM, PhD, Gazi University Faculty of Medicine Department of Anatomy, Ankara, Turkey
E-mail: zcoskun@gazi.edu.tr

©Telif Hakkı 2016 Gazi Üniversitesi Tıp Fakültesi - Makale metnine <http://medicaljournal.gazi.edu.tr/> web adresinden ulaşılabilir.

©Copyright 2016 by Gazi University Medical Faculty - Available on-line at web site <http://medicaljournal.gazi.edu.tr/>

doi:<http://dx.doi.org/10.12996/gmj.2016.65>

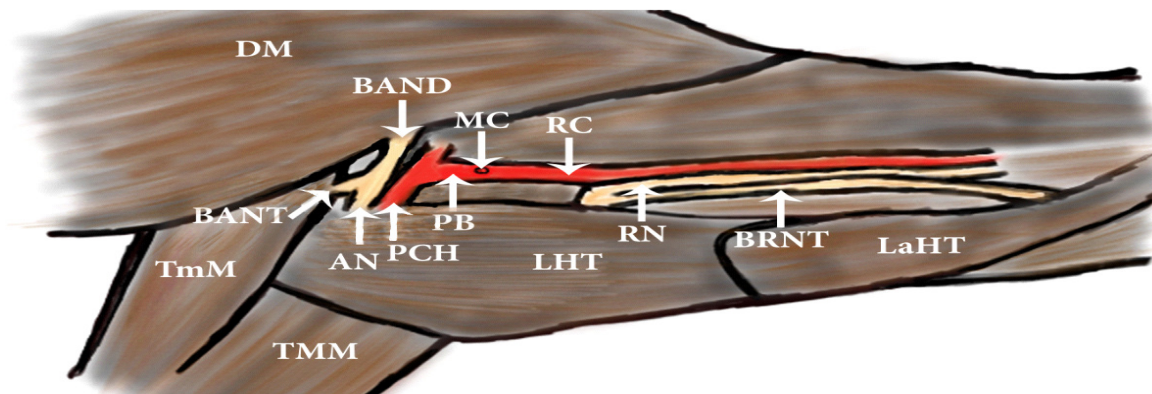
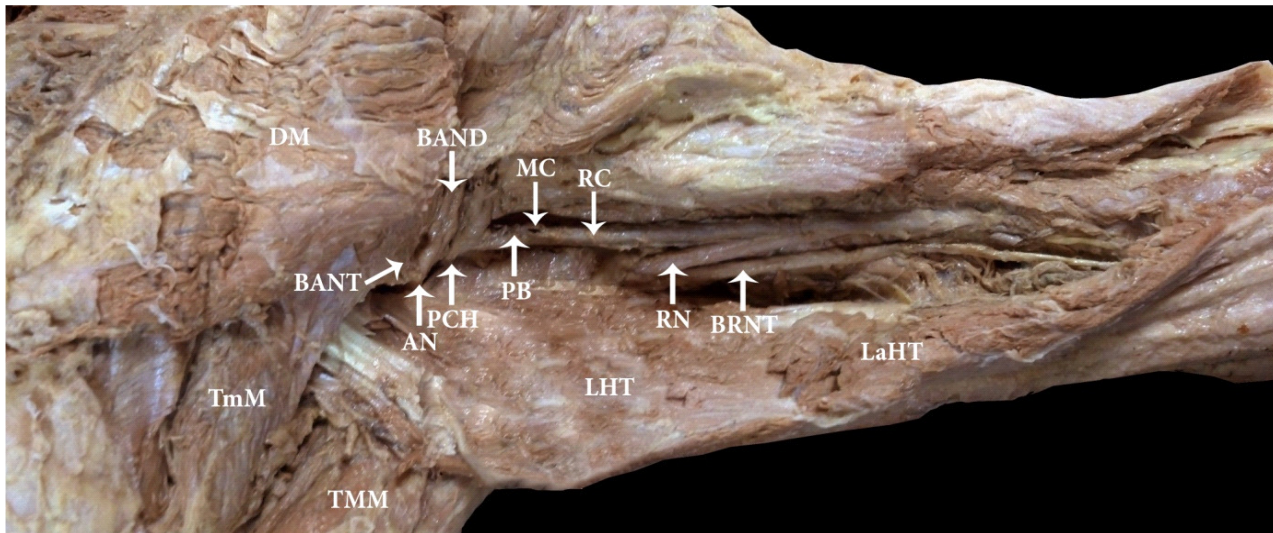


Figure 1. Posterior view of the right upper arm and its schematic illustration. TmM- teres minor muscle; TMM- teres major muscle; DM- deltoid muscle; LHT- long head of triceps muscle; LaHT- lateral head of triceps muscle; AN- axillary nerve; BANT- branch of axillary nerve to teres minor muscle; BAND- branch of axillary nerve to deltoid muscle; PCH- posterior circumflex humeral artery; PB- profunda brachii artery; MC- middle collateral artery (cut); RC- radial collateral artery; RN- radial nerve; BRNT- branch of radial nerve to triceps brachii, lateral head.

DISCUSSION

The profunda brachii artery, which arises from the brachial artery at a point distal to the level of the teres major muscle, and its terminal branches are the blood supply to the posterior compartment of the arm. The profunda brachii artery accompanies the radial nerve into the radial sulcus of the humerus (5). In the present study, profunda brachii artery arose from posterior circumflex humeral artery and radial nerve in radial sulcus did not accompany profunda brachii artery.

The profunda brachii artery is the largest branch of the brachial artery and it shows considerable variation in its origin. In 55% of the cases, it arises as a single trunk at the level of the tendon of the teres major muscle. It may arise from the axillary artery (in 22% cases), as a common trunk with the superior ulnar collateral artery (in 22% cases) or as a branch of the circumflex humeral artery (in 7% cases) (6). Shetty et al. (2012) have reported the two branches of the profunda brachii; the radial collateral and the middle collateral arteries originating from a common trunk, which also gave origin to the superior ulnar collateral artery (7). In the present study, radial collateral and middle collateral arteries arose from profunda brachii artery separately. Yücel (1999) have reported that the third part of the right axillary artery gave origin to a common branch, the profunda brachii artery and the superior ulnar collateral artery (8).

The posterior circumflex humeral artery may arise from the profunda brachii artery and pass back below the teres major instead of passing through the quadrangular space (9). In the present study, conversely, profunda brachii artery arose from posterior circumflex humeral artery. The posterior

circumflex humeral artery, passed through quadrangular space along with axillary nerve.

Ramesh et al. (2008) have reported the third part of the axillary artery gave only one main trunk, which divided into two main branches, lateral and medial. The lateral branch gave common humeral circumflex artery, which divided into anterior and posterior circumflex humeral arteries, the latter continued as the profunda brachii artery (10). The branches of the third part of the axillary artery are subject to great variation. The two circumflex humeral arteries may arise from a common trunk, usually alone or rarely together with the profunda brachii and muscular branches. Very rarely it may give rise to a common trunk, from which may arise the subscapular, anterior and posterior circumflex humeral, profunda brachii, and ulnar collateral arteries (11). In the study of Cavdar et al (2000) it was demonstrated that the third part of the axillary artery unilaterally divides into two major arterial stems, named according to their localization as deep brachial artery and superficial brachial artery (brachial artery). The deep brachial artery gives off the posterior circumflex humeral artery, anterior circumflex humeral artery, subscapular artery, and profunda brachii artery (12). Nayak et al (2008) demonstrated that profunda brachii artery arose from third part of axillary artery and did not accompany radial nerve (13). Likewise, in the present study, profunda brachii artery arose from the third part of axillary artery, but from posterior circumflex humeral artery and did not accompany radial nerve.

Branches of the upper limb arteries have been used for coronary bypass and flaps in reconstructive surgery. Accurate knowledge of the normal and variant arterial pattern of the human upper extremities is important both for reparative surgery and for angiography (14).

Variations in the terminal end of axillary artery are important not only for anatomists, but also for surgeons because, when raising a microvascular myocutaneous flap based on one of these terminal branches of the axillary artery, the reconstructive surgeon needs to be familiar with these variations and appropriate preoperative planning is essential before performing surgery. The variations also need to be evaluated by orthopaedic surgeons when preparing the soft tissue flap for covering the stump after an above-elbow amputation. Likewise, for the internal fixation of a fracture of the shaft of the humerus, it is important to avoid injury to the arterial branches, which can bring about ischemic complications (15).

As a result, we can say that, for vascular surgeons and radiologists, awareness of details and topographic anatomy of variations of the axillary artery may be good guide. During the surgery of the axillary artery region, it may also help to prevent diagnostic errors and complication.

Conflict of interest

No conflict of interest was declared by the authors.

REFERENCES

1. Kodama K. Arteries of the upper limb. In: Sato T, Akita K, eds, *Anatomic Variations in Japanese*, University of Tokyo Press, Tokyo, 2000; 220-37.
2. Williams PL, Bannister LH, Berry MM, Collins P, Dyson M, Dussek JE and Ferguson MWJ. *Gray's Anatomy*, 38th Ed, Edinburgh: Churchill Livingstone, 1995. pp. 1538-44
3. Anagnostopoulou S, and Venieratos D. An unusual branching pattern of the superficial brachial artery accompanied by an ulnar nerve with two roots. *J Anat* 1999; 195:471-6.
4. Srivastava SK and Pande BS. Anomalous pattern of median artery in the forearm of Indians. *Acta Anat* 1990; 138:193-4.
5. Williams, PL, R. Warwick, M. Dyson and L.H. Bannister (eds.) 1989 *Gray's Anatomy*. New York : Churchill Livingstone, p. 758.
6. Tountans CP, Bergman RA. *Anatomical variations of the upper extremities*. New York, Churchill Livingstone. 1993. pp 197-10.
7. Shetty SD, Nayak BS, Madhav NV, Sirasanagandla SR, P A. The abnormal origin, course and the distribution of the arteries of the upper limb: a case report. *J Clin Diagn Res*. 2012; 6: 1414 -6.
8. Yücel AH. Unilateral variation of the arterial pattern of the human upper extremity with a muscle variation of the hand. *Acta Med Okayama*. 1999; 53:61-5.
9. Johnson, D. & Ellis, H. Pectoral girdle and upper limb. In: Standring, S. Ed. *Gray's Anatomy*. 39th ed. Edinburgh, Elsevier, 2005. p. 845.
10. Ramesh RT, Shetty P, Suresh R. Abnormal branching pattern of the axillary artery and its clinical significance. *Int. J. Morphol.* 2008;26:389-92.
11. Bergman, R. A.; Thomson, S. A.; Afifi, A. K. & Saadeh, F. A. *Compendium of Anatomic Variation*. In: Cardiovascular system. Baltimore, Urban and Schwarzenber, 1988. pp. 72-3.
12. Cavdar S, Zeybek A, Bayramiçli M. Rare variation of the axillary artery. *Clin Anat*. 2000;13:66-8.
13. Nayak SR, Krishnamurthy A, Kumar M, Prabhu LV, Saralaya V, Thomas MM. Four-headed biceps and triceps brachii muscles, with neurovascular variation. *Anat Sci Int*. 2008; 83:107-11.
14. Yoshinaga K, Kodama K, Kameta K et al. A rare variation in the branching pattern of the axillary artery. *Indian J. Plast. Surg.* 2006; 39: 222-3.
15. Pandey SK, Gangopadhyay AN, Tripathi SK, Shukla VK. Anatomical variations in termination of the axillary artery and its clinical implications. *Med Sci Law* 2004;44:61-6.