

## Foreign Body in the Lateral Wall of Ethmoid Sinus: An Unusual Injury Related to Pneumatic Screw Gun

Etmoid Sinus Lateral Duvarında Yabancı Cisim: Pnömatik Vida Tabancasına Bağlı Yaralanma

Halit Baykan<sup>1</sup>, Sedat Tatar<sup>1</sup>, Günhan Gökahmetoğlu<sup>2</sup>, Emin Silay<sup>2</sup>

<sup>1</sup> Kayseri Research and Training Hospital, Department of Plastic, Reconstructive and Aesthetic Surgery, Kayseri, Turkey

<sup>2</sup> Kayseri Research and Training Hospital, Department of Anesthesia and Resuscitation, Kayseri, Turkey

### ABSTRACT

Intraorbital and periorbital foreign bodies may occur after direct trauma, metallic injuries and occupational accidents. Foreign bodies penetrated into the ethmoid sinus are not common and most cases occur after traumas. We presented a case with a foreign body penetrated into the right ethmoid sinus by pneumatic screw gun, a rarely reported etiology in the literature and we presented treatment approach.

**Key Words:** Etmoid sinus, foreign body, periorbital, pneumatic screw, trauma, foreign body

**Received:** 05.31.2016

**Accepted:** 09.05.2017

### ÖZET

İntraorbital ve periorbital yabancı cisim yaralanmaları direk travma, metalik yaralanmalar ve meslek kazaları sonrası oluşabilmektedir. Etmoid sinüse direkt penetre yabancı cisim olguları nadirdir ve çoğunlukla travmalar sonrası oluşur. Kliniğimizde ilginç bir etyoloji ile pnömatik vida tabancasıyla oluşan ve sağ etmoid sinüse penetre olan yabancı cisim olgusunu ve tedavi yaklaşımımızı sunduk.

**Anahtar Sözcükler:** Etmoid sinus, periorbital, pnömatik tabanca, travma, yabancı cisim

**Geliş Tarihi:** 31.05.2016

**Kabul Tarihi:** 05.09.2017

### INTRODUCTION

Intraorbital and periorbital foreign bodies may occur after direct trauma, metallic injuries, splinter injuries in woodworkers and occupational accidents, and may be responsible from one out of every six orbital injuries(1). The literature involves reports of periorbital foreign body injuries that occurred due to interesting etiologies (2). As another interesting etiology of foreign body injury, in this report we have presented a case of pneumatic gun injury that extended towards the ethmoid sinus.

### CASE REPORT

A 17-years old female patient referred to the emergency of our hospital with the complaints of pain and burning in the right eye, which developed while she had been operating a pneumatic screw gun at her workplace without wearing safety glasses. Physical examination of the patient showed 3 mm laceration and mild chemosis in the right medial canthal region, whereas her vision examination, visual field, eye movements, retina examination, medial canthal region and lacrimal sac assessments turned out to be normal (Figure 1).

**Address for Correspondence / Yazışma Adresi :** Sedat Tatar, MD Department of Plastic Reconstructive and Aesthetic Surgery, Kayseri Research and Training Hospital, Kayseri, Turkey E-mail: sedattatarr@gmail.com

©Telif Hakkı 2017 Gazi Üniversitesi Tıp Fakültesi - Makale metnine <http://medicaljournal.gazi.edu.tr/> web adresinden ulaşılabilir.

©Copyright 2017 by Gazi University Medical Faculty - Available on-line at web site <http://medicaljournal.gazi.edu.tr/>

doi:<http://dx.doi.org/10.12996/gmj.2017.79>

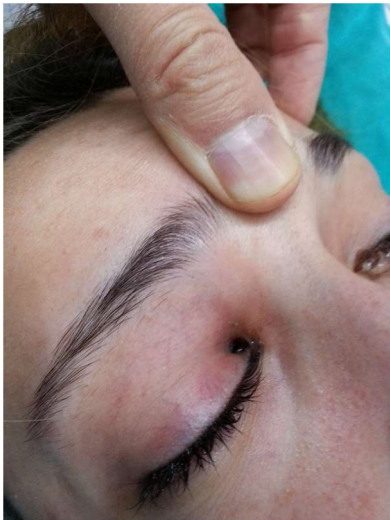


Figure 1: 3 mm laceration in the medial canthal area

Three dimensional computed tomography showed a metal screw that ran along the medial wall of the orbita to the inside of the right ethmoid sinus (Figure 2,3).

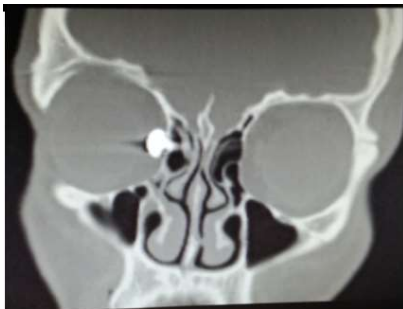

Figure 2: Computed tomography image of foreign body

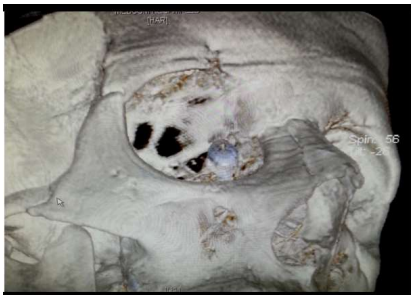

Figure 3: 3D image shows that screw at the lateral wall of ethmoid sinus

The patient was operated under general anesthesia. An incision was performed on the laceration at the medial canthal region and bone structures of the medial wall were accessed while preserving the lacrimal sac and medial canthal ligaments.

Periosteal dissection was performed around the foreign body and the head of the screw was exposed. No fracture was observed when the bone structures were examined. A simultaneous nasal examination was performed in order to check intranasal extension and bleeding, and the 1.5 cm long screw was removed in a controlled manner using a screwdriver and clamp (Figure 4,5). The incision was closed after bleeding had been controlled. No functional problems or wound-healing complications developed during the postoperative period and the patient had no complaints at the follow-up visit performed 6-months later.

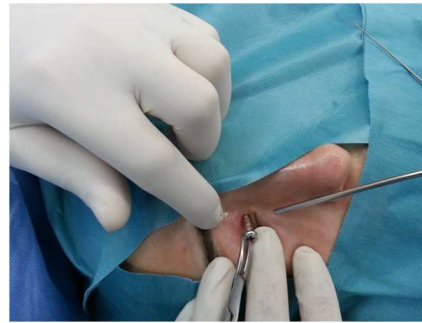

Figure 4: Foreign body removed from medial canthus



Figure 5: 15 mm screw

## DISCUSSION

Foreign body in the orbita and ethmoid sinus is a rare occurrence and 70% of all cases occur due to posttraumatic reasons (3). In such injuries, age, localization of injury and vascular and other complications can be life threatening. The most common late complications include infectious complications such as leakage of cerebrospinal fluid (CSF), meningitis, orbital cellulitis and brain abscess and vascular complications such as progressive intravascular thrombosis and traumatic aneurysm. However, true incidence of late complications is unclear (4).

In this report, we have presented a patient who referred to our clinics with a foreign body penetrated into the right ethmoid sinus. Pneumatic screw gun, a rarely reported etiology in the literature, had caused the injury of the case described here. After ophthalmologic examination of the injury, the patient was taken into surgery under general anesthesia. The laceration at the medial canthal region was entered to access the site of injury and the foreign body was removed using a screwdriver. Nasal examination was performed, bleeding was controlled and possible CSF leakage was monitored at the same time. No complication developed during the follow-up period.

## CONCLUSION

Foreign bodies penetrated into the ethmoid sinus are not common and most cases occur after a trauma. In addition to resulting in ocular problems, these injuries may also be associated with complications such as meningitis and abscess, and may affect the vascular and neurological structures. Periorbital injuries may occur due to unexpected and interesting etiologies, and wearing safety glasses is crucial to ensure protection. In the case presented here, a foreign body, which penetrated into the ethmoid sinus of a patient who was not wearing safety glasses, was removed without any complication

## Conflict of interest

No conflict of interest was declared by the authors.

## REFERENCES

1. Taş S, Top H. Intraorbital wooden foreign body: clinical analysis of 32 cases, a 10-year experience. *Ulus Travma Acil Cerrahi Derg.* 2014;20:51-5.
2. Matsuzaki K, Aoki T, Oji T, Nagashima H, Tsue C, Maki R et.al. A rare case of a broken dental bur perforating the medial orbital wall without damaging the eye. *Quintessence Int.* 2016;47:75-9.
3. Jin H R. Foreign body in the orbit associated with blowout fracture. *Plast Reconstr Surg.* 2006;117:1050-1.
4. Erkutlu İ, Alptekin M, Dokur M, Geyik M, Gök A." Unusual penetration of a construction nail through the orbit to the cranium: a case report" *Ulus Travma Acil Cerrahi Derg* 2011;17:79-82.